

Tinea cruris managed with a single dose of individualised homoeopathic medicine: A case report

K. Sivakumar*

Clinical Research Unit for Homoeopathy, Dimapur, Nagaland, India

Abstract

Introduction: Tinea cruris is an infection of the skin over groins by a species of dermatophyte. It is a common ringworm infestation that affects the groin and is caused by *Trichophyton rubrum*, characterised by red, itchy erythematous plaques extending from the Groin and flexures onto the thighs, buttocks and perianal region of the skin. More than eight million people visit primary care physicians annually to treat tinea-related symptoms. Topical agents are the mainstay in conventional medicine. However, a holistic approach with Homoeopathy for treating tinea cruris can make a difference in terms of both cure and preventing relapse. **Case Summary:** A 30-year-old male presented with a ring-like red erythematous lesion on the buttocks and perianal region of skin with severe itching. The case was diagnosed clinically as tinea cruris. The patient was treated with individualised homoeopathic medicine *Sulphur* 1M in a single dose and followed up for 6 months. There was a complete disappearance of tinea cruris lesions, as documented as photographic evidence, without any adverse effects and recurrence of lesions in the follow-up period. In this case, the outcome and causal attribution of the changes were assessed using the Modified Naranjo Criteria for Homoeopathy. The score was +10 showing the positive relationship between the intervention and the outcome. This case shows the positive role of individualised homoeopathic medicine in the management of tinea cruris.

Keywords: Homoeopathy, Individualisation, Ringworm, *Sulphur*, Tinea cruris

INTRODUCTION

Dermatophytes are fungi that invade and multiply within keratinised tissues (skin, hair and nails), and cause superficial infections of skin known as ringworm or dermatophytosis.^[1] They can originate from the soil or animals or be confined to human skin (anthropophilic).^[2] Clinical forms of cutaneous infection of dermatophytes include tinea corporis, tinea capitis, tinea cruris and tinea pedis.^[3] Causative pathogenesis is by the dermatophyte fungi releasing proteolytic enzymes and keratinases into the skin.^[3] Tinea cruris is also known as ringworm, *dhobi* itch, jock itch and eczema marginatum.^[4] Common in adults and males, itching is a predominant feature in every species. Scaling is variable and occasionally may mask the inflammatory changes.^[4] Some central clearance is usually present but is often incomplete, with nodules scattered throughout the affected area.^[4] Satellite lesions, if present, are few and relatively large. Spread to the scrotum is common, but scaling is minimal and inflammation is inconspicuous against background erythema. Usually, the diagnosis is clinical but can be confirmed by microscopic examination of potassium hydroxide wet-mount preparations of

skin scrapings from the active border of the lesion.^[5] A fungal culture is a gold standard for diagnosing dermatophytosis in doubtful, inconclusive, severe, widespread and resistant cases.^[6] Along with neglected approaches, the climate pattern of tropical and subtropics with high humidity and temperature increased moisture, and poor hygiene provided fertile soil for the fungus.^[7,8] Long-continued treatment and medication costs often lead the patient to search for alternative therapies. Although conventional topical antifungal therapy is effective in treating tinea cruris and other dermatophyte manifestations, its appropriate dose and duration of administration for curing and preventing recurrence remains elusive.^[1] In contrast, the Homoeopathy system, with individualised homoeopathic medicine, treats the patient as a whole, rather than just the disease alone, relieves complaints, aims to prevent recurrence

*Address for correspondence: K. Sivakumar,
National Homoeopathy Research Institute in Mental Health, PO
Sachivothamapuram, Kottayam - 686 532, Kerala, India.
E-mail: drshivasree@gmail.com

Received: 13 November 2022; Accepted: 16 February 2024

Access this article online

Quick Response Code:



Website:
www.ijrh.org

DOI:
10.53945/2320-7094.1298

This is an open access journal, and articles are distributed under the terms of the Creative Commons Attribution-NonCommercial-ShareAlike 4.0 License, which allows others to remix, tweak, and build upon the work non-commercially, as long as appropriate credit is given and the new creations are licensed under the identical terms.

How to cite this article: Sivakumar K. Tinea cruris managed with a single dose of individualised homoeopathic medicine: A case report. Indian J Res Homoeopathy 2024;18:21-28.

and ensures healthy skin. Despite the increased prevalence of cutaneous dermatophytosis worldwide, research in this area has often been neglected. There is an intense need to undertake more research studies and report evidence-based cases focused on the homoeopathic management of tinea cruris. In routine daily practice, the homoeopathic medicine *Sulphur* is widely used for various skin conditions, with promising results when indicated. On a thorough literature search at online databases, well-designed observational or randomised controlled trials on the effectiveness of homoeopathic medicines in treating tinea cruris could not be found. Hence, there is a considerable research gap in this area. The present case shows the evidence-based positive role of individualised homoeopathic medicine *Sulphur* in managing tinea cruris.

PATIENT INFORMATION

A 30-year-old male, a teacher by profession, presented at the outpatient department (OPD) of the Clinical Research Unit for Homoeopathy, Dimapur, with complaints of multiple reddish, ring-like lesions over the buttocks and perianal region accompanied by itching and burning sensation for 2 years. The complaint was treated initially with some antifungal lotions, resulting in temporary relief of complaints. After 1 year, he developed haemorrhoids with bleeding from the rectum during stool, and burning sensation which was ameliorated by cold water application. He also complained of constipation.

History of presenting complaints

The skin lesions had started 2 years back as brown, as discoloured patchy lesions over the Groin which gradually increased in size, became red, erythematous with raised edges accompanied by itching and burning sensation. The patient had consulted a dermatologist who had prescribed some anti-fungal ointments. After using them, initially, there was some relief in skin lesions and itching. However, soon after, he developed two more lesions over the buttocks and the perianal region. Subsequently, the lesions increased in size and thickness and appeared reddish. The itching was aggravated after taking a bath. The haemorrhoids started 1 year back as mild protrusion and bleeding from the rectum during stool. There was itching at the anus and a burning sensation ameliorated from the cold water application. It was 2° haemorrhoids accompanied by constipation, and the stool was hard and unsatisfactory. Complaints were associated with dandruff and itching of the scalp.

There was a history of scabies in childhood, treated with external lotions. His father was hypertensive, and no other relevant family history was there.

For the present complaints, the patient had taken allopathic and Ayurvedic treatment and used many external lotions without significant relief.

Clinical findings

On inspection, the eruptions were present over the buttocks and perianal skin which were ring-like, hyperpigmented, red

inflammation, erythematous, thick, raised edges with central clearing. On palpation, there was no tenderness, but mild soreness was present. On general examination, the patient was conscious and well-built, with no pallor, cyanosis, jaundice or clubbing.

The patient was social, extroverted and talkative, and had anxiety about health. He was mentally dissatisfied due to the previous treatments taken for ringworm, liked cold drinks and sweets and wanted to be open-air. He also had constipation with unsatisfactory, hard stool.

Provisional diagnosis was tinea cruris. Tinea cruris was differentiated from erythrasma due to the absence of the distinctive features of red–brown colour and no active border; and from seborrheic dermatitis with the lack of greasy scale on erythematous base with the typical distribution involving hairline, eyebrows, postauricular folds and annular lesions less common. Based on the clinical history and physical examination and distinguishing the clinical features of similar conditions, tinea cruris was confirmed.

Case analysis and repertorisation

All the symptoms obtained from detailed case-taking are analysed in Table 1. The totality of symptoms included his social nature with a desire for company, dissatisfaction, desire for cold drinks, eruptions ring-like, itching aggravated from bathing, burning sensation in anus ameliorated by cold water application, haemorrhoids with bleeding, itching ameliorated by scratching, etc. Characteristic symptoms were converted to rubrics and repertorisation was done with Synthesis Treasure Edition 2009v [Figure 1].

Therapeutic intervention

The individualised homoeopathic medicine *Sulphur* was selected based on the totality of symptoms and repertorisation in consultation with *Materia medica*, as per the homoeopathic principles.^[9,10] A single dose of *Sulphur* 1M, the potency of the centesimal scale was given as the first prescription as one medicated globule 30 size to be taken on an empty stomach. Diet and regimen were also recommended, such as taking plenty of leafy vegetables and fruits to manage constipation and haemorrhoids, following preventive measures such as

Table 1: Analysis of symptoms

Mental generals	Physical generals	Particular/disease symptoms
Social	Desire cold drinks	Ring-like lesions
Desires	Desires sweets	Severe itching aggravated by sweat, ameliorated by scratching
Talkative	Desire open air	Itching aggravated after bathing
Anxiety about health	Hot patient	Dandruff
Dissatisfied	Constipation and unsatisfactory stool	Haemorrhoids
		Burning sensation in the anus ameliorated by cold application

bathing twice daily, personal hygiene and keeping skin lesions area dry to avoid reinfection.

Follow-up and outcome

The patient was assessed every 2 weeks or earlier if required. The detailed follow-up and outcomes are summarised in Table 2. No adverse effects were noted during the treatment. The Modified Naranjo Criteria for Homoeopathy was also used for the causal attribution between medicinal intervention and clinical outcome.^[11]

After taking medicine, complaints of bleeding per rectum stopped after 1 day, and there was a slight aggravation in itching of skin eruptions, but it decreased in intensity after 2 days. The burning sensation after stool and constipation were ameliorated subsequently. After that, skin eruptions gradually decreased in thickness, red erythematous discolouration disappeared and the itching was relieved completely. The disappearance of tinea cruris lesions occurred with *Sulphur*

1M, a single dose and *Thuja* 1M was given as an intercurrent remedy for relieving the associated symptoms of haemorrhoids. Tinea cruris lesions on the buttocks, perianal and Groin region completely disappeared within 2 months of treatment, and no recurrence of lesions developed in the follow-up period [Figures 2-6].

No adverse effects were noted during the treatment. The Modified Naranjo Criteria for Homoeopathy (MONARCH) was used for the causal attribution between medicinal intervention and clinical outcome.^[11] The MONARCH score was +10, close to the maximum score of +13, which reveals the intervention, *Sulphur* as the cause for the disappearance of tinea cruris [Table 3].

DISCUSSION

Tinea cruris is a natural chronic disease. The patient presented with lesions suggestive of tinea cruris. Usually, the diagnosis




Figure 1: Repertorial Chart

Date	Complaints	Prescription	Remarks
08 June 2022	Multiple rings-like lesions, sensitive skin and itching. Haemorrhoids, bleeding per rectum, constipation and burning sensation after stool are relieved by cold water application. Dandruff with itchy scalp	<i>Sulphur</i> 1M, one dose (30 size medicated one globule) morning on an empty stomach	Single, simple and similar medicine in minute dose
18 June 2022	The itching aggravated slightly after medicine administration but resolved quickly, and the bleeding from haemorrhoids stopped. Slight pain and hard stools are present. Ring-like lesions' thickness was reduced, itching reduced and generally better. Dandruff is not present	<i>Placebo</i> for 2 weeks	The striking improvement in the bleeding of haemorrhoids stopped quickly at first. Transient homoeopathic aggravation was noted in the itching but resolved soon after
28 June 2022	Pain and burning in haemorrhoids and constipation were relieved. Skin lesions' thickness and edges disappeared, itching was relieved and red discolouration was also reduced, generally better	<i>Placebo</i> for 3 weeks	The patient is generally better.
18 July 2022	No complaints regarding haemorrhoids except soft swelling inside the anus without complaints. The lesions of tinea cruris also disappeared	<i>Placebo</i> for 3 weeks	Haemorrhoids became mild and reduced from 2° to 1° types. Tinea cruris wholly disappeared
08 August 2022	The swelling of haemorrhoids inside the anus was reduced.	<i>Placebo</i> for 3 weeks	
01 September 2022	Haemorrhoids relieved	<i>Thuja</i> 1M 1 dose <i>Placebo</i> for 1 month	Anti sycotic prescription
04 October 2022	Slight itching of the scalp with mild dandruff	<i>Placebo</i> for 1 month	No complaints
26 October 2022	Dandruff with itching of the scalp relieved	<i>Placebo</i> for 1 month	-
10 October 2022	No complaints	<i>Placebo</i> for 1 month	-
09 October 2022	No complaints	<i>Placebo</i> for 1 month	-

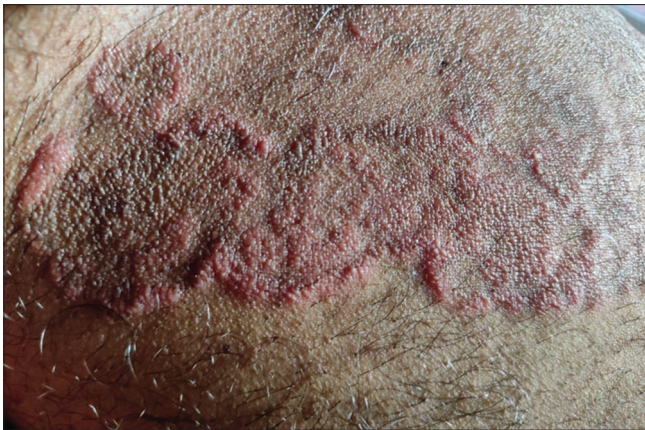

Figure 2: Tinea cruris before treatment (08 June 2022)

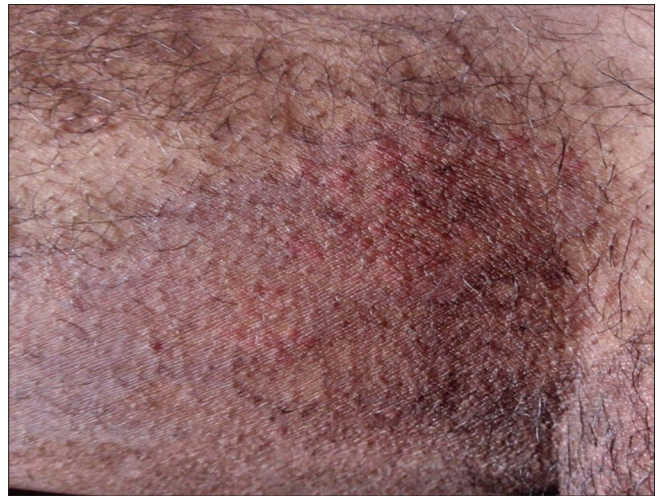

Figure 5: Tinea cruris during treatment (20 August 2022)

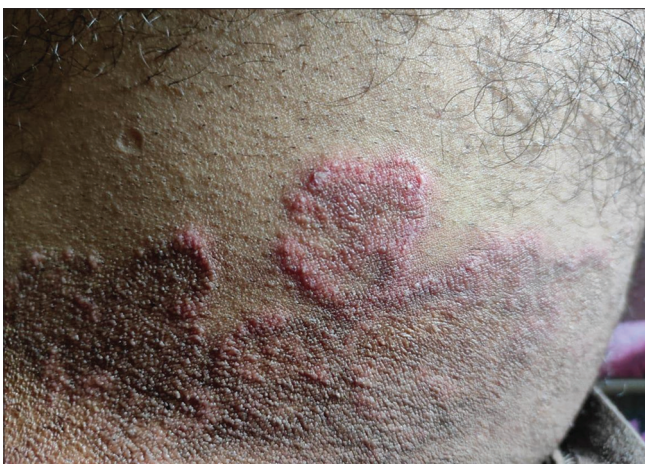

Figure 3: Tinea cruris during treatment (28 June 2022)

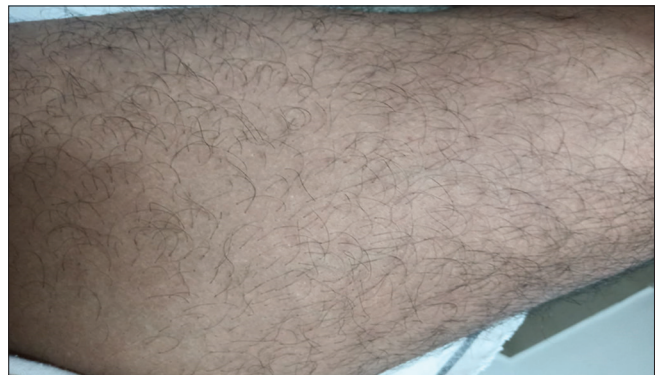

Figure 6: Tinea cruris after treatment (30 August 2022)

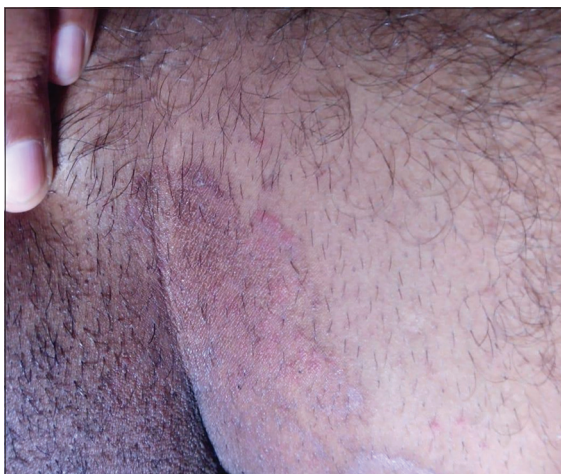

Figure 4: Tinea cruris during treatment (18 July 2022)

is clinical but can be confirmed by microscopic examination of potassium hydroxide wet-mount preparations of skin scrapings from the active border of the lesion.^[5] In this case, we had suggested an investigation of KOH examination to diagnose tinea cruris, but the patient resided in a small town with limited investigation facilities, so the diagnosis was

based on clinical history and local examination. In modern medicine, first-line treatment is with antifungal ointments and corticosteroids in extensive cases. In this case, homoeopathic medicine *Sulphur* was selected after careful case-taking and repertorisation and in consultation with materia medica. Predisposing factors such as excess perspiration with improper hygiene and residing in a hot and high-humidity locality were observed in this case.

Along with medicine, diet and regimen, good hygiene practices were also advised. This case showed marked improvement suggesting a suitable selection of medicine. Since the patient had been suffering from complaints for 2 years, he was anxious and worried about the disease. *Sulphur* 1M was given in a single dose. Generals and other individual characteristics and particulars were most similar to *Sulphur* and considering the vitality of individual and predominant psoric miasm, we had prescribed *Sulphur* in 1M potency. Dr Samuel Hahnemann mentioned in the 283rd aphorism of *Organon of Medicine* 6th edition that the true physician will prescribe his well-selected homoeopathic medicine only in exactly as small a dose as will just suffice to overpower and annihilate the disease before him.^[12] The cure is not organismic, but organic, not chemical, not mechanical, not local, not topic, not parasitic,

Table 3: Monarch inventory (improved version of the modified Naranjo Criteria for Homoeopathy Case Report)

Domains	Yes	No	Not Sure or N/A	Score for successfully treated case	Justification
Was there any improvement in the main symptom or condition for which homoeopathic medicine was prescribed?	+2	-1	0	2	Tinea cruris complaint improved
Did the clinical improvement occur within a plausible time frame relative to the medicine intake?	+1	-2	0	1	The main complaint was relieved within 2 months
Was there a homoeopathic aggravation of symptoms?	+1	0	0	1	Itching symptoms aggravated slightly after the medicine.
Did the effect encompass more than the main symptom or condition (i.e., were other symptoms not related to the main presenting complaint improved or changed)?	+1	0	0	1	Associated complaints of haemorrhoids and constipation were improved
Did overall well-being improve? (suggest using a validated scale or mention about changes in physical, emotional and behavioural elements)	+1	0	0	0	Generally better but not measured with a particular scale.
Direction of cure: Did some symptoms improve in the opposite order of the development of symptoms of the disease?	+1	0	0	1	Haemorrhoid symptoms improve first, then skin symptoms improved
Direction of cure: did at least one of the following aspects apply to the order of improvement in symptoms? From organs of more importance to those of less importance? From deeper to more superficial aspects of the individual? From the top downwards?	+1	0	0	1	Symptoms of Haemorrhoids are relieved first, and symptoms of deeper organs improve initially, then skin complaints.
Did old symptoms (defined as non-seasonal and non-cyclical symptoms previously thought to be resolved) reappear temporarily during improvement?	+1	0	0	0	Not observed
Are there alternative causes (i.e., other than the medicine) that, with a high probability, could, have produced the improvement? (consider the course of disease, other forms of treatment and other clinically relevant interventions)	-3	+1	0	1	Not at all
Was the health improvement confirmed by any objective evidence? (e.g., investigations, clinical examination, etc.)	+2	0	0	2	Confirmed by photographs
Did repeat dosing, if conducted, create similar clinical improvement?	+1	0	0	0	Not done
Total score (Maximum score – 13 and Minimum – 6)				10	Causal attribution established

but organic vital.^[13] As expected, the patient responded quickly to the treatment and the complaints were relieved within a few months. The law of direction of cure has been explained by Constantine Hering as the perfect cure should be established as relieving symptoms in reverse order of development, from centre to periphery, from inner to outer and deeper organs to superficial. In this case, the chief complaint was tinea eruptions and the same was treated initially with antifungal lotions, resulting in temporary relief of complaints but not cured. After some time, the itching in eruptions aggravated, and he also developed haemorrhoids that were associated with the chief complaint when the patient consulted at OPD for the first time. After considering the totality of symptoms, individualised homoeopathic medicine *Sulphur* was given according to homoeopathic principles. In response to this intervention, the bleeding from the anus was relieved first followed by relief in tinea eruptions which was in accordance

with the law of direction of cure. In general, *Sulphur* is given for various skin ailments as a specific medicine, and we get positive results on most occasions, but when we consider the patient as a whole and with a holistic approach, *Sulphur* given as an individualised homoeopathic medicine results in not only cure of chief complaint but also relieves all other associated complaints within a considerable time and indeed the law of direction of cure was evident.

The MONARCH outcome assessment score was +10, establishing a causal relationship between the medical intervention and the clinical outcome.^[11] There was no recurrence of complaints in the 6-month follow-up period even though local climate conditions in the study place favour the relapse of eruptions. Hence, this case showed the positive role of homoeopathic medicine in curing tinea cruris when prescribed on a holistic approach. Since it is a single case study and tinea cruris is associated with a variable and unpredictable

remission, well-designed randomised control studies may be used for gold standard evidence.

CONCLUSION

Individualised homoeopathic medicine plays an important role in treating patients holistically. The complete disappearance of tinea cruris without any recurrence of lesions in the 6 months of the follow-up period is evidence supportive of the positive role of individualised homoeopathic medicine *Sulphur* in the cure of tinea cruris and associated complaints. Therefore, further prospective studies on the curative role of *Sulphur* in treating tinea cruris are suggested for scientific validation.

Declaration of patient consent

We certify that the patient has given written informed consent for his images and other clinical information to be reported in the journal. The patient understands that his name and contact details will not be published and due efforts will be made to conceal his identity, but anonymity cannot be guaranteed.

Financial support and sponsorship

Nil.

Conflicts of interest

Nil.

REFERENCES

1. Sahoo AK, Mahajan R. Management of tinea corporis, tinea cruris, and tinea pedis: A comprehensive review. *Indian Dermatol Online J* 2016;7:77-86.
2. Nicholus AB, Nicki RC, Brain RW, editors. *Davidson's Principles and Practice of Medicine*. 20th ed. Edinburgh: Churchill Livingstone/Elsevier; 2010. p. 1297.
3. Fauci B, Kasper H, Longo J. *Harrison's Principles of Internal Medicine*. 17th ed. New York: McGraw-Hill; 2008. p. 199.
4. Christopher G, Jonathan B, Tanya B, Robert C, Daniel C. *Rook's Textbook of Dermatology*. 9th ed., Part 3., Ch. 32.46. New Jersey: Wiley Blackwell; 2016. p. 968.
5. Leung AK, Lam JM, Leong KF, Hon KL. Tinea corporis: An updated review. *Drugs Context* 2020;9:5-6.
6. Sewon K, Masayuki A, Anna L, Alexander H, Amy J, David J, *et al*. *Fitzpatrick's Dermatology*. 9th ed., Vol. 2. USA: McGraw Hill; 2019. p. 2945.
7. Burnett JC. *Ringworm, its Constitutional Nature and Cure*. Philadelphia, PA: Boericke & Tafel; 1892. p. 89-90.
8. Banerjee SK. *Miasmatic Prescribing, its Philosophy, Diagnostic Classifications, Clinical Tips, Miasmatic Repertory, Miasmatic Weightage of Medicines and Case Illustrations*. Second Enlarged edition. New Delhi: B. Jain Publishers (P) Ltd.; 2010. p. 3-6.
9. Boericke W. *Pocket Manual of Homoeopathic Materia Medica and Repertory*. New Delhi: B. Jain; 1994. p. 507.
10. Allen HC. *Key Notes and Characteristics with Comparisons of Some of the Leading Remedies of the Materia Medica with Bowel Nosodes*. 8th ed. New Delhi: B. Jain; 2002. p. 219.
11. Lamba CD, Gupta VK, van Haselen R, Rutten L, Mahajan N, Molla AM, *et al*. Evaluation of the modified naranjo criteria for assessing causal attribution of clinical outcome to homeopathic intervention as presented in case reports. *Homeopathy* 2020;109:191-7. Erratum in: *Homeopathy* 2020.
12. Hahnemann CF. *Organon of Medicine*. 6th ed. New Delhi: B. Jain Publishers; 2008. p. 221-3.
13. Chitkara HL. *Best of Burnett*. Reprint Edition. New Delhi: B. Jain Publishers (P) Ltd.; 2007. p. 114.

Tinea cruris pris en charge avec une dose unique de médicament homéopathique individualisé : à propos d'un cas

Introduction: Tinea cruris est une infection de la peau des aines par une espèce de dermatophyte. Il s'agit d'une infestation courante de teigne qui affecte l'aine et est causée par *Trichophyton rubrum*, caractérisée par des plaques érythémateuses rouges et prurigineuses s'étendant de l'aine et des flexions sur les cuisses, les fesses et la région périnéale de la peau. Plus de huit millions de personnes consultent chaque année un médecin de premier recours pour traiter les symptômes liés à la teigne. Les agents topiques constituent le pilier de la médecine conventionnelle. Cependant, une approche holistique avec l'homéopathie pour traiter la teigne cruris peut faire une différence en termes de guérison et de prévention des rechutes. Résumé du cas : Un homme de 30 ans s'est présenté avec une lésion érythémateuse rouge en forme d'anneau sur les fesses et la région périnéale de la peau avec de fortes démangeaisons. Le cas a été diagnostiqué cliniquement comme étant une teigne cruris. Le patient a été traité par le médicament homéopathique individualisé Soufre 1M en dose unique et suivi pendant 6 mois. Il y a eu une disparition complète des lésions de la teigne cruris, comme en témoignent les preuves photographiques, sans aucun effet indésirable ni récurrence des lésions au cours de la période de suivi. Dans ce cas, le résultat et l'attribution causale des changements ont été évalués à l'aide des critères modifiés de Naranjo pour l'homéopathie. Le score était de +10 proche du maximum (13), démontrant la relation positive entre l'intervention et le résultat. Ce cas montre le rôle positif de la médecine homéopathique individualisée dans la prise en charge de la teigne cruris.

Tinea cruris mit einer Einzeldosis individualisierter homöopathischer Medizin behandelt: Ein Fallbericht

Einleitung: Tinea cruris ist eine Infektion der Haut über der Leistengegend durch eine Dermatophytenart. Es handelt sich um einen häufigen Ringwurmbefall, der die Leiste befällt und durch *Trichophyton rubrum* verursacht wird. Er ist durch rote, juckende erythematöse Plaques gekennzeichnet, die sich von der Leistengegend und den Biegungen auf die Oberschenkel, das Gesäß und den Perianalbereich der Haut erstrecken. Mehr als acht Millionen Menschen suchen jährlich Hausärzte auf, um Tinea-bedingte Symptome zu behandeln. Topische Wirkstoffe sind die tragende Säule der Schulmedizin. Ein ganzheitlicher Ansatz mit Homöopathie zur Behandlung von Tinea cruris kann jedoch sowohl hinsichtlich der Heilung als auch der Vorbeugung von Rückfällen einen Unterschied machen. Fallzusammenfassung: Ein 30-jähriger Mann stellte sich mit einer ringförmigen roten erythematösen Läsion am Gesäß und im perianalen Hautbereich mit starkem Juckreiz vor. Der Fall wurde klinisch als Tinea cruris diagnostiziert. Der Patient wurde mit dem individualisierten homöopathischen Arzneimittel Sulphur 1M in einer Einzeldosis behandelt und 6 Monate lang nachbeobachtet. Es kam zu einem vollständigen Verschwinden der Tinea cruris-Läsionen, was durch fotografische Beweise dokumentiert wurde, ohne dass es zu Nebenwirkungen und einem Wiederauftreten der Läsionen in der Nachbeobachtungszeit kam. In diesem Fall wurden das Ergebnis und die kausale Zuordnung der Veränderungen anhand der modifizierten Naranjo-Kriterien für Homöopathie beurteilt. Der Wert lag bei +10 nahe am Maximum (13), was den positiven Zusammenhang zwischen der Intervention und dem Ergebnis zeigt. Dieser Fall zeigt die positive Rolle der individualisierten homöopathischen Medizin bei der Behandlung von Tinea cruris.

व्यक्तिगत होम्योपैथिक दवा की एक खुराक से टिनिया क्रूरिस का प्रबंधन: एक केस की रिपोर्ट

टिनिया क्रूरिस डर्माटोफाइट की एक प्रजाति है जो ग्रोइन की त्वचा को संक्रमित करती है यह ट्राइकोफाइटन रूब्रम के कारण होने वाला एक आम फंगल संक्रमण है जो ग्रोइन को प्रभावित करता है और इसमें लाल खुजलीदार चकते होते हैं जो ग्रोइन और फ्लेक्सजर् से जांघों, नितंबों और गुदा श्रेत्र तक फैल जाते हैं। सालाना, टिनिया के लक्षणों वाले 8 मिलियन से अधिक लोग प्राथमिक चिकित्सकों के पास जाते हैं। पारंपरिक चिकित्सा सामयिक एजेंटों पर निर्भर करती है। हालांकि टिनिया क्रूरिस के इलाज के लिए होम्योपैथी के साथ एक समग्र दृष्टिकोण अपनाने से इलाज से फ़र्क लाया जा सकता है और दोबारा होने से रोका जा सकता है।

सारांश:- एक 30 वर्षीय पुरुष नितंबों और पेरिअनल क्षेत्र पर की त्वचा एक छल्ले के आकर का लाल एरिथेमेटस घाव था जिसमें गंभीर खुजली होती थी। चिकित्सीय रूप से, मामले को टिनिया क्रूरिस के रूप में निदान किया गया था। रोगी का इलाज सल्फर 1M व्यक्तिगत होम्योपैथिक दवा की एक खुराक से किया गया और छह महीने तक अनुसरण किया गया | फोटोग्राफिक साक्ष्य के अनुसार, टिनिया क्रूरिस घाव पूरी तरह से बिना किसी नकारात्मक प्रभाव के गायब हो गए। और दोबारा नहीं हुए | होम्योपैथी के लिए संशोधित नारंजो मानदंड का उपयोग इस मामले में परिवर्तनों के परिणाम और कारण का मूल्यांकन करने के लिए किया गया था। हस्तक्षेप और परिणाम का सकारात्मक संबंध देखा गया, क्योंकि स्कोर अधिकतम (13) के पास +10 था। यह उदाहरण टिनिया क्रूरिस के प्रबंधन में व्यक्तिगत होम्योपैथिक दवा की लाभप्रद भूमिका को प्रदर्शित करता है।

Tinea cruris tratada con una dosis única de medicina homeopática individualizada: reporte de un caso

Introducción: La tiña cruris es una infección de la piel de las ingles por una especie de dermatofito. Es una infestación de tiña común que afecta la ingle y es causada por *Trichophyton rubrum*, caracterizada por placas eritematosas rojas que pican y se extienden desde la ingle y las flexiones de los muslos, las nalgas y la región perianal de la piel. Más de ocho millones de personas visitan anualmente a sus médicos de atención primaria para tratar los síntomas relacionados con la tiña. Los agentes tópicos son

el pilar de la medicina convencional. Sin embargo, un enfoque holístico con la homeopatía para el tratamiento de la tiña crural puede marcar la diferencia tanto en términos de curación como de prevención de recaídas. Resumen del caso: Un hombre de 30 años presentó una lesión eritematosa roja en forma de anillo en las nalgas y la región perianal de la piel con picazón intensa. El caso fue diagnosticado clínicamente como tiña crural. El paciente fue tratado con medicamento homeopático individualizado Sulphur 1M en dosis única y seguido durante 6 meses. Hubo una desaparición completa de las lesiones de tiña crural, como se documentó mediante evidencia fotográfica, sin efectos adversos ni recurrencia de las lesiones en el período de seguimiento. En este caso, el resultado y la atribución causal de los cambios se evaluaron utilizando los Criterios de Naranjo Modificados para Homeopatía. La puntuación fue de +10 cerca del máximo (13), lo que muestra la relación positiva entre la intervención y el resultado. Este caso muestra el papel positivo de la medicina homeopática individualizada en el tratamiento de la tiña crural.

单剂量个体化顺势疗法治疗股癣：病例报告

简介：股癣是由一种皮肤癣菌引起的腹股沟皮肤感染。这是一种影响腹股沟的常见癣菌感染，由红色毛癣菌引起，其特征是红色、发痒的红斑从腹股沟延伸到大腿、臀部和肛周皮肤区域。每年有超过八百万人去看初级保健医生来治疗癣相关症状。外用药物是传统医学的支柱。然而，顺势疗法治疗股癣的整体方法可以在治愈和预防复发方面发挥作用。病例摘要：一名30岁男性，臀部及肛周皮肤出现环状红色红斑病变，伴有剧烈瘙痒。该病例临床诊断为股癣。患者接受个体化顺势疗法药物硫磺1M单剂量治疗，并随访6个月。有照片证明，股癣皮损完全消失，随访期间没有任何不良反应和皮损复发。在本例中，使用改良纳兰霍顺势疗法标准评估了变化的结果和因果归因。分数为+10，接近最大值（13），表明干预与结果之间存在正相关关系。该病例显示了个体化顺势疗法在股癣治疗中的积极作用。