

Tinea cruris treated with individualised homoeopathic medicine – An evidence-based case report

Yogeshwari Gupta, Arvind Sharma, Samridhi Sharma*

Swasthya Kalyan Homoeopathic Medical College and Research Centre, Jaipur, Rajasthan, India

Abstract

Introduction: Tinea cruris, also commonly known as *jock itch*, is a skin infection caused by dermatophytes which are pathogenic fungi affecting genital, pubic, perineal and perianal areas. Tinea cruris more commonly affects men and affects adults more than children. Conventional management involves the use of topical antifungal agents and oral therapy in extensive cases. **Case Summary:** A case of tinea cruris in a 30-year-old male patient is reported, which was effectively treated with individualised homoeopathic medicine. Based on the totality of symptoms, the homoeopathic medicine *Natrum muriaticum* in 200C potency was prescribed as the first dose and improvement was observed in subsequent follow-ups. In this case, the causal attribution to the prescribed medicine was established by the Modified Naranjo Criteria Score. This evidenced-based case suggests that tinea cruris can be successfully managed with individualised homoeopathic treatment.

Keywords: Dermatology, Dermatophyte, Fungal infection, HOM-CASE, Modified naranjo criteria, *Natrum muriaticum*, Skin, Tinea cruris

INTRODUCTION

Tinea cruris is a skin infection caused by dermatophytes that affect the genital, pubic, perineal and perianal areas. *Trichophyton*, *Epidermophyton* and *Microsporum* genera dermatophytes have the ability to break down keratin and are the causative agents of tinea cruris.^[1] The primary cause is *T. rubrum*. Several cases also involve *T. mentagrophytes* var. *interdigitale* and *E. floccosum*. Itching is a common symptom, regardless of the causative species.^[2]

Early-stage lesions extend from the groin down the thighs and are characterised by erythematous plaques with curved edges and sharp borders. Inflammatory changes may occasionally mask the scaling. Vesiculation is uncommon, however, older lesions may have dermal nodules, developing beading along the margin. Minute pustules which are one or two in number are often seen. *T. rubrum* may infest the buttocks and lower back as well as further reaching other regions of the trunk.^[2]

Several risk factors, including excessive sweating, obstructive clothes and poor hygiene cause tinea cruris. Perspiration seems to have the greatest impact on the development of infection of all these mentioned factors.^[3] Pruritic, erythematous and raised brown patches with sharply defined borders are seen

on the groin and inner thighs. Vesicles may form along the edge of the patches. The infection may migrate to the gluteal cleft and buttocks, but the scrotum and penis are not normally affected. Clinical presentation and a thorough history may be sufficient for diagnosis.^[4]

Tinea cruris is the second most common superficial fungal infection, with a worldwide prevalence of 20–25%. It is more prevalent in tropical and subtropical countries like India, where heat and humidity are high. It is more common in male adults.^[5,6]

Differential diagnosis includes Candidiasis, candidal intertrigo, erythrasma, psoriasis, pityriasis versicolor and seborrheic dermatitis.^[1,7] Adjacent pustules and absence of scale differentiate candida intertrigo from tinea cruris.^[8] Candidiasis, pityriasis versicolor and intertrigo are all skin conditions that can affect the groin. Candidiasis is characterised by white pustules and frayed peeling edges. Pityriasis versicolor is often asymptomatic and non-inflammatory. Intertrigo is common

***Address for correspondence:** Samridhi Sharma, Swasthya Kalyan Homoeopathic Medical College and Research Centre, Jaipur, Rajasthan, India. E-mail: samridhisharma06@gmail.com

Received: 28 November 2022; **Accepted:** 06 September 2023

Access this article online

Quick Response Code:



Website:
www.ijrh.org

DOI:
10.53945/2320-7094.1306

This is an open access journal, and articles are distributed under the terms of the Creative Commons Attribution-NonCommercial-ShareAlike 4.0 License, which allows others to remix, tweak, and build upon the work non-commercially, as long as appropriate credit is given and the new creations are licensed under the identical terms.

How to cite this article: Gupta Y, Sharma A, Sharma S. Tinea cruris treated with individualised homoeopathic medicine – An evidence-based case report. Indian J Res Homoeopathy 2023;17:181-186.

in obese individuals and has a sharp margin with significant bacterial colonisation. Lichenification is a possibility with atopic eczema, but it often goes up to the hip.^[2]

Homeopathy plays an important role in the treatment of tinea as shown in a clinical trial and evidenced-based case reports.^[9-11] However, published evidence on particularly tinea cruris form is still insufficient.

There are several medicines in the homeopathic materia medica for tinea infection such as *Arsenic*, *Bacillinum*, *Tellurium* and *Sepia*.^[12] This case report shows the usefulness of individualised homeopathic medicine in the treatment of this condition.

PATIENT INFORMATION

A 30-year-old male patient, a shopkeeper, presented to the outpatient department of Swasthya Kalyan Homoeopathic Medical College and Research Centre, Sitapura, Jaipur, in January 2022 with complaints of severe itchy lesions on the lower abdomen and groin region for 4–5 months. The itching aggravated at night and after scratching. The patient took allopathic antifungal medicines for approximately 6 months which relieved him temporarily. He was not on any medication at the time of reporting. He also had complaints of hair loss for 8 months, more from the temporal region and while combing hair (30–40 hair strands came out while combing), with white scales of dandruff over the scalp. There was no family history of any major medical illnesses.

The patient had a desire for spicy food. He preferred warm meals, which he had difficulty tolerating. He also had a fear of high places, a desire for solitude, and was of a reserved nature.

CLINICAL FINDINGS

Erythematous patches with distinct margins were seen on the groin and inner thighs, especially on the left side. The patient’s weight was 75 kg, he was 167 cm tall and his pulse rate was 74 beats/min. His respiratory rate was 16/min.

The diagnosis of tinea cruris was made through clinical presentation and clinical history.

ANALYSIS OF CASE AND REPERTORISATION

The following characteristic symptoms were considered for repertorisation:

1. Aversion to company
2. Fear of high places
3. Reserved personality
4. White dandruff over the scalp
5. Hair loss while combing
6. Hair loss more from the temporal region
7. Itching aggravated at night and on scratching
8. Fungal eruptions over the skin of lower abdomen, inner thighs and groin region
9. Desire for spicy food.

THERAPEUTIC INTERVENTION

This case was repertorised using *Synthesis Repertory* in the RADAR 10.5 software. [Figure 1] As per the reportorial result, the top two medicines which covered the totality were *Arsenicum album* and *Natrum muriaticum*. After consulting *Materia Medica*, the hot thermals of the patient facilitated the elimination of *Arsenicum album*. The first prescription was thus *Natrum muriaticum* 200C/1 dose given on 12 January 2022, followed by a placebo for 15 days. The detailed follow-up is provided in Table 1.

DISCUSSION

Following a thorough case history and recording of the same on a structured proforma, analysis and evaluation of the case was done, the totality of the symptoms was constructed and based on repertorisation, the appropriate homeopathic medicine was chosen. *Synthesis repertory*^[12] was used for repertorisation. The similimum for the case was selected from the medicines that fetched the highest marks on repertorisation and further verified from *Boericke’s New Manual of Homeopathic Materia Medica with Repertory*.^[13] According to the Law of Simplex, only one medicine was prescribed. A single dose was given to the patient, followed by a placebo in accordance with the Law of Minimum dose and the case was treated with high potency as per the susceptibility of the patient.^[14,15] The changes in

	ars.	nat-m	sulph.	phos.	puls.	thur.	arg-n	calc.	lvc	staph.	alum.	mez.	sep.	caust.	con.	gra
1. MIND - COMPANY - aversion to	1	2	3	4	5	6	7	8	9	10	11	12	13	14	15	16
2. MIND - FEAR - high places, of	8	7	7	7	6	6	6	6	6	5	5	5	5	5	5	5
3. MIND - RESERVED	11	15	15	12	11	9	8	8	7	9	8	8	8	7	7	7
4. HEAD - DANDRUFF - white	1	4	2	1	2	2	2	1	2	3	3	-	3	-	2	1
5. HEAD - HAIR - falling - combing the hair; when	1	1	1	1	1	1	2	1	1	1	-	-	-	1	1	-
6. HEAD - HAIR - falling - Temples	1	3	1	3	2	1	1	2	1	2	1	1	1	1	1	1
7. SKIN - ITCHING - night	1	3	-	2	-	3	-	-	-	1	2	-	-	-	-	-
8. SKIN - ITCHING - scratching - agg.	-	-	-	-	-	-	-	-	-	-	-	-	-	-	-	-
9. SKIN - ERUPTIONS - ringworm	-	2	-	-	-	-	-	1	1	-	-	-	-	-	-	1
10. GENERALS - FOOD and DRINKS - spices ...	1	-	3	1	1	1	1	-	-	-	-	2	-	2	1	2
	3	-	3	1	3	-	1	1	-	2	2	2	1	2	2	-
	2	1	2	-	-	1	-	2	1	-	-	1	2	-	-	2
	1	1	3	3	2	-	1	-	1	1	1	-	1	1	-	-

Figure 1: Repertorisation

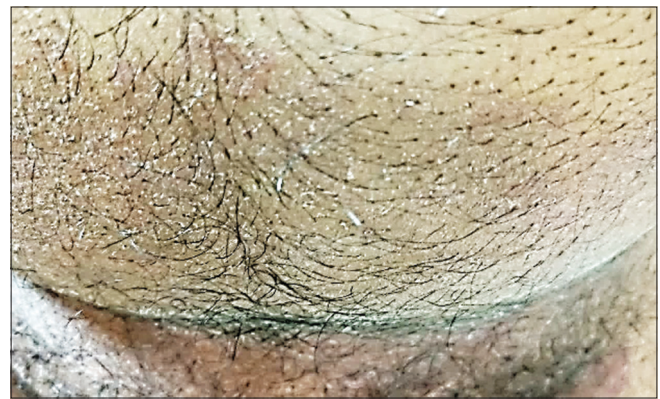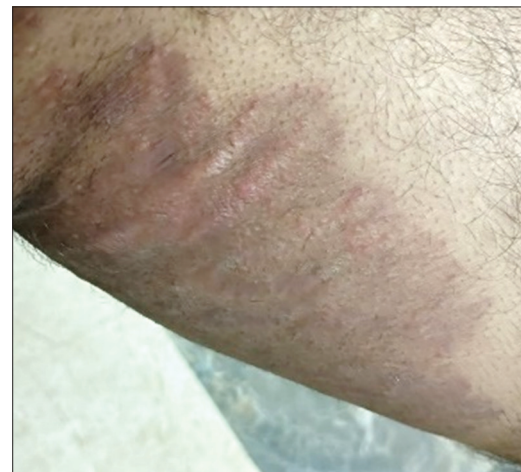Table 1: Follow-up details

Date	Change in symptoms	Prescription
12 January 2022	Severe itchy, erythematous lesions on the lower abdomen and groin region. The itching aggravated at night and after scratching. Hair loss: 30–40 hair strands fall when combing hair as reported by the patient. White dandruff was observed on the scalp.	<i>Natrum muriaticum</i> 200C/1 dose Placebo T.D.S. × 15 days
25 January 2022	Redness and inflammation persisted in both regions, but itching intensity was slightly reduced. Hairfall when combing hair and dandruff: same	Placebo T.D.S. × 15 days
17 February 2022	The itching intensity at night was reduced but redness and inflammation persisted in both the patches. Hairfall reduced to 20–25 hair strands while combing hair. Dandruff: Status Quo.	Placebo T.D.S. × 15 days
2 March 2022	Severe itching in the groin region; aggravated at night, scratching. Inflammation persisted. The abdominal patch was better. Approximate 20–25 hair strands still fall. Dandruff was not seen on the scalp examination.	<i>Natrum muriaticum</i> 1M/1 Dose/Stat Placebo T.D.S. × 15 days
23 March 2022	Redness, itching and inflammation reduced in both the patches. Hairfall of approximate 10 hair strands when combing. Dandruff not seen on the patient's scalp.	Placebo T.D.S. × 15 days
6 April 2022	Itching was reduced and inflammation was absent in both the patches. Hairfall was better; approximately 10–12 hair strands come off now.	Placebo T.D.S. × 15 days
20 April 2022	The patches are almost resolved. Itching and inflammation were absent.	Placebo T.D.S. × 15 days
11 May 2022	Hairfall continues to be approximately 10–12 hair when combing. No itching in the groin region.	Placebo T.D.S. × 15 days
25 May 2022	Both the patches resolved and the skin gained a normal appearance. Hairfall approximately 5–6 hair while combing.	Placebo T.D.S. × 15 days
8 June 2022	No complaints.	Placebo T.D.S. × 15 days

signs and symptoms were noted during follow-up. Potency was increased from 200C to 1M during the follow-up, based on the assessment of reporting signs and symptoms [Table 1]. The tinea lesions disappeared subsequently with the constitutional medicine.

The present case report shows the successful treatment of tinea cruris with the help of individualised homeopathic medicine that is, *Natrum muriaticum*, as shown in the photographs [Figures 2-9], and also reported in subsequent follow-ups in Table 1. Further, the MONARCH score [Table 2] (+8 on the “-6 to +13” scale) indicated the causality that the patient's improvement was due to the homeopathic treatment.^[16] The case is reported as per HOM-CASE-CARE guidelines.^[17] No symptoms' reappearance was reported by the patient even after 6 months of the treatment and with the help of the individualised medicine, there was a marked improvement, not only in the main complaint of tinea cruris but also in the associated complaints of infection. However, the cure could not be verified by investigations like KOH mount, which remains the limitation of the case. Furthermore, a longer follow-up would have further validated the permanent resolution of the complaints.

The previous studies also show the significant role of individualised homeopathic medicines in dermatophyte infections. However, the homeopathic literature has little evidence of treatment of fungal infection which is also mentioned in the case report by Gautam and Goel.^[18] Interestingly, two cases of tinea faciei treated with homeopathic medicines have been reported, out of which one case was treated with *Natrum muriaticum* 30C and potency was increased as per need.^[10] Further, a few traceable reported literature for tinea cruris were found. Another case of tinea cruris successfully treated with *Sulphur* highlighted the

**Figure 2:** Lesions as on 12 January 2022: Lower abdomen**Figure 3:** Lesions as on 12 January 2022: Inner thigh (Left)

importance of miasms for effective prescription.^[19] The above literature suggests that homeopathic medicines are useful for

Table 2: Modified naranjo criteria for homoeopathy (MONARCH) score

S. No.	Domains	Yes	No	Not sure or N/A
1	Was there an improvement in the main symptom or condition for which the homoeopathic medicine was prescribed?	+2		
2	Did the clinical improvement occur within a plausible timeframe relative to the medicine intake?	+1		
3	Was there a homeopathic aggravation of symptoms?		0	
4	Did the effect encompass more than the main symptom or condition, (i.e., were other symptoms, not related to the main presenting complaint, improved or changed)?	+1		
5	Did overall well-being improve? (suggest using a validated scale or mention about changes in physical, emotional and behavioural elements)	+1		
6	(A) Direction of cure: Did some symptoms improve in the opposite order of the development of symptoms of the disease? (B) Direction of cure: Did at least one of the following aspects apply to the order of improvement of symptoms: – From organs of more importance to those of less importance? – From deeper to more superficial aspects of the individual? – From the top downward?		0	0
7	Did “old symptoms” (defined as non-seasonal and non-cyclical symptoms that were previously thought to have resolved) reappear temporarily during the course of improvement?		0	
8	Are there alternative causes (i.e., other than the medicine) that – with a high probability – could have produced the improvement? (Consider known course of disease, other forms of treatment and other clinically relevant interventions)		+1	
9	Was the health improvement confirmed by any objective evidence? (e.g., investigations, clinical examination, etc.)	+2		
10	Did repeat dosing, if conducted, create similar clinical improvement?			0
Total score - 8				
Maximum score=13, minimum score=-6				

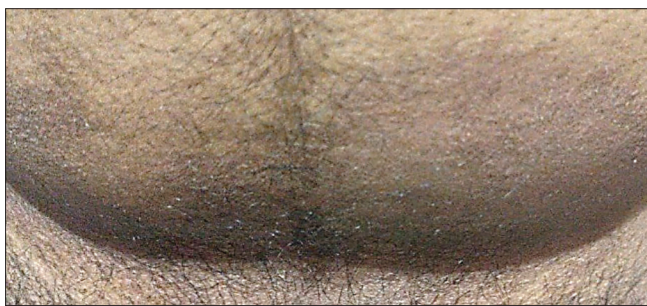

Figure 4: Lesions as on 23 March 2022: *Lower abdomen*

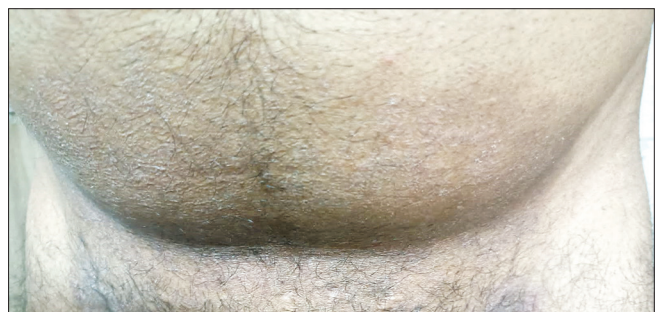

Figure 6: Lesions as on 6 April 2022 *Lower Abdomen*

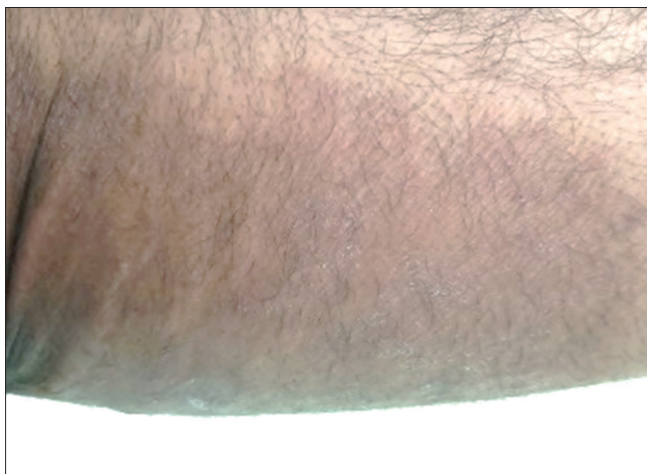


Figure 5: Lesions as on 23 March 2022: *Inner thigh (left)*

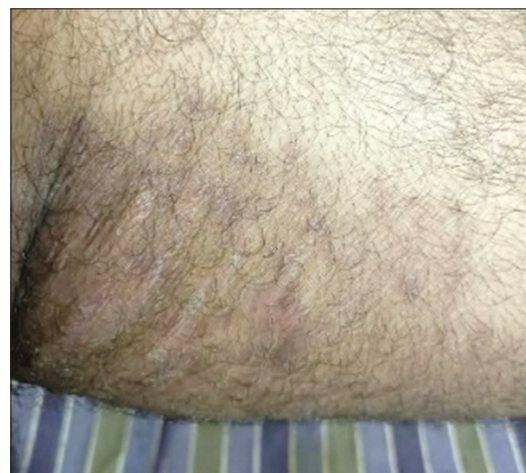

Figure 7: Lesions as on 6 April 2022 *Inner thigh (Left)*

treating tinea cases and their role should be explored further to validate their utility.

This case also highlighted the importance of a holistic approach in the remedy selection considering the

individuality of the patient. This case, treated with individualised homoeopathic medicine, shows relief in signs and symptoms and also, no recurrence, as mentioned in this report.^[10]

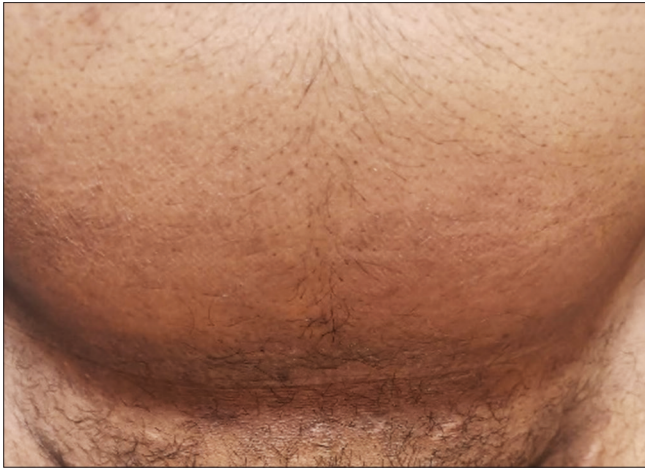

Figure 8: Lesions as on 8 June 2022 Lower Abdomen

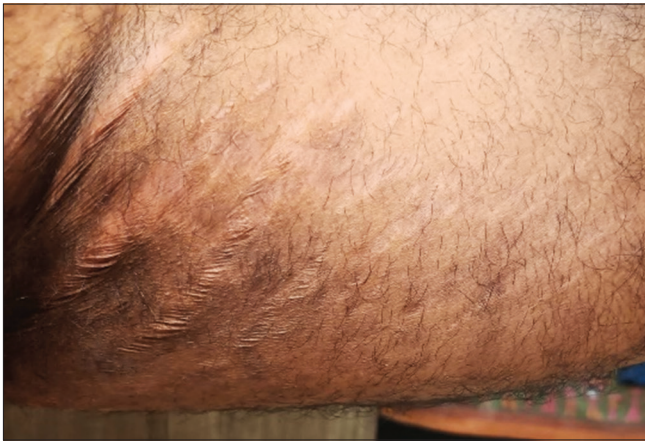

Figure 9: Lesions as on 8 June 2022 Inner thigh (Left)

CONCLUSION

With the use of constitutional homoeopathic medicine *Natrum muriaticum*, tinea cruris was successfully treated and the patient's health was restored. To establish homoeopathy as a reliable treatment for tinea cruris, more clinical studies are needed.

Declaration of patient consent

The authors certify that they have sought the patient's permission before publishing his clinical data in a journal. The patient is aware that while every attempt will be made to keep his identity secret and that only his initials will be used, anonymity cannot be guaranteed.

Financial support and sponsorship

Nil.

Conflicts of interest

None.

REFERENCES

1. Hui D, Leung AA, Ma C. Approach to Internal Medicine: A Resource Book for Clinical Practice. 5th ed. Switzerland: Springer Nature; 2022. p. 363.
2. Burns T, Breathnach SM, Cox NH, Griffiths C. Rook's Textbook of Dermatology. 7th ed., Vol. 4. Philadelphia, PA: Blackwell Science; 2004.
3. Gupta AK, Chaudhry M, Elewski B. Tinea corporis, tinea cruris, tinea nigra, and piedra. *Dermatol Clin* 2003;21:395-400.
4. Arndt KA, Bowers KE, Alam M, Reynolds R, Tsao S. Manual of Dermatologic Therapeutics: With Essential Diagnosis. 6th ed. Philadelphia, PA: Lippincott Williams and Wilkins; 2002. p. 136.
5. Lakshmanan A, Ganeshkumar P, Mohan SR, Hemamalini M, Madhavan R. Epidemiological and clinical pattern of dermatomycoses in rural India. *Indian J Med Microbiol* 2015;33 Suppl:134-6.
6. Wiederkehr M, Elston DM. Tinea cruris; 2018 Available from: <https://emedicine.medscape.com/article/1091806-overview> [Last accessed on 2022 Sep 16].
7. Ely JW, Rosenfeld S, Stone MS. Diagnosis and management of tinea infections. *Am Fam Physician* 2014;90:702-10.
8. Tierney LM, Saint S, Whooley MA. Current Essentials of Medicine. 4th ed. New York: McGraw-Hill Medical; 2010. p. 410.
9. Bhardwaj OP, Manchanda RK, Gupta R. Evaluation of Bacillinum in tinea infection. *Br Homoeopath J* 1990;79:10-1.
10. Shukla I. Tinea faciei treated with constitutional homoeopathic medicine using Vithoulkas compass: Two evidence-based case reports. *Indian J Res Homoeopath* 2022;16:171-7.
11. Dixit AK, Giri N. Tinea corporis: An evidence-based case report treated with homoeopathic medicine Sepia. *Homoeopath Links* 2020;33:33-40.
12. Schroyens F. Synthesis 9.1: English. 1st ed. Cambridge, UK: RSC Publishing; 2023.
13. Boericke W. Pocket Manual of Homoeopathic Materia Medica. 9th ed. New Delhi: IBPP; 2015. p. 1086.
14. Das AK. A Treatise on Organon of Medicine. 5th ed. Calcutta: Souvik Homoeo Publishers; 2002. p. 1-35.
15. Banerjee SK. Miasmatic Prescribing. 2nd ed. Germany: Narayan Publishers; 2006. p. 189-250.
16. Lamba CD, Gupta VK, van Haselen R, Rutten L, Mahajan N, Molla AM, *et al.* Evaluation of the modified Naranjo criteria for assessing causal attribution of clinical outcome to homeopathic intervention as presented in case reports. *Homeopathy* 2020;109:191-7.
17. Van Haselen RA. Homeopathic clinical case reports: Development of a supplement (HOM-CASE) to the CARE clinical case reporting guideline. *Complement Ther Med* 2016;25:78-85.
18. Gautam P, Goel M. Pityriasis versicolor in an infant treated with homoeopathy: A case report. *Indian J Res Homoeopath* 2022;16:132-8.
19. Bala R, Srivastava A. Constitutional treatment of tinea cruris in homoeopathy-a case report. *Int J Health Sci Res* 2019;9:54-61.

Tinea Cruris traitée par la médecine homéopathique individualisée – Rapport de cas fondé sur des données probantes

Introduction: Tinea cruris, également connue sous le nom de démangeaison jock, est une infection cutanée causée par des dermatophytes qui sont des champignons pathogènes affectant les zones génitales, pubiennes, périnéales et périanales. Tinea cruris touche plus souvent les hommes et les adultes plus que les enfants. La prise en charge conventionnelle implique l'utilisation d'agents antifongiques topiques et d'un traitement oral dans de nombreux cas.

Résumé du cas: Un cas de tinea cruris chez un homme de 30 ans est signalé, qui a été traité efficacement avec un médicament homéopathique individualisé. Basé sur la totalité des symptômes, le médicament homéopathique Natrum muriaticum dans la puissance 200C comme première dose, et l'amélioration a été observée dans les suivis ultérieurs. Dans ce cas, l'attribution causale au médicament prescrit a été établie par le score de critères de Naranjo modifié. Ce cas mis en évidence suggère que tinea cruris peut être géré avec succès avec un traitement homéopathique individualisé.

Tinea cruris behandelt mit individualisierter homöopathischer Medizin - ein evidenzbasierter Fallbericht

Einleitung: Tinea cruris, auch bekannt als *Sommerekzem*, ist eine Hautinfektion, die durch Dermatophyten, pathogene Pilze, verursacht wird und die Genital-, Scham-, Damm- und Perianalbereiche betrifft. Tinea cruris tritt häufiger bei Männern auf und betrifft eher Erwachsene als Kinder. Die konventionelle Behandlung umfasst die Anwendung von topischen Antimykotika und in schweren Fällen eine orale Therapie. **Zusammenfassung des Falls:** Es wird über einen Fall von Tinea cruris bei einem 30-jährigen männlichen Patienten berichtet, der mit einer individualisierten homöopathischen Arznei wirksam behandelt wurde. Aufgrund der Gesamtheit der Symptome wurde das homöopathische Arzneimittel *Natrum muriaticum* in der Potenz 200C als erste Dosis verabreicht, und bei den nachfolgenden Nachuntersuchungen wurde eine Besserung beobachtet. In diesem Fall wurde die kausale Zuordnung zu der verordneten Arznei durch den modifizierten Naranjo-Kriterien-Score festgestellt. Dieser evidenzbasierte Fall zeigt, dass Tinea cruris mit einer individuellen homöopathischen Behandlung erfolgreich behandelt werden kann.

वैयक्तीकृत होम्योपैथी दवा से टीनिया क्रूरिस का उपचार – साक्ष्य आधारित केस रिपोर्ट

परिचय: टीनिया क्रूरिस, जिसे आमतौर पर जॉक इच (jock itch) के नाम से भी जाना जाता है, जो जननांग, जघन, मूलाधार और गुदा के आस-पास के क्षेत्रों को प्रभावित करता है। (डर्माटोफाइट्स जो कि रोगजनक कवक है, इनके कारण होने वाला त्वचा का एक संक्रमण है।) टीनिया क्रूरिस पुरुषों में और बच्चों की तुलना में वयस्कों को अधिक प्रभावित करता है। पारंपरिक उपचार में सामयिक एंटीफंगल एजेंटों और मौखिक उपचार का प्रयोग गंभीर मामलों में किया जाता है। **केस सारांश:** एक 30 वर्षीय पुरुष रोगी में टीनिया क्रूरिस का मामला बताया गया है, जिसका प्रभावी रूप से व्यक्तिगत होम्योपैथी दवा से उपचार किया गया था। लक्षणों की समग्रता के आधार पर, 200C पोटेन्सी में होम्योपैथी दवा नेट्रम म्यूरियाटिकम (*Natrum muriaticum*) की पहली खुराक दी गई और बाद के फॉलो-अप में सुधार देखा गया। इस मामले में, निर्धारित दावा को, संशोधित नारंजो मानदंड द्वारा कारण स्थापित किया गया। इस साक्ष्य-आधारित मामले से यह पता चलता है कि वैयक्तीकृत होम्योपैथी उपचार द्वारा टीनिया क्रूरिस का सफलतापूर्वक प्रबंधन किया जा सकता है।

Tinea Cruris Tratada con Medicina Homeopática Individualizada - Informe de un Caso Basado en la Evidencia

Introducción: La tiña crural, también conocida como tiña inguinal, es una infección cutánea causada por dermatofitos, hongos patógenos que afectan a las zonas genital, púbica, perineal y perianal. La tiña crural afecta con más frecuencia a los hombres y afecta más a los adultos que a los niños. El tratamiento convencional consiste en el uso de antifúngicos tópicos y terapia oral en casos extensos. **Resumen del caso:** Se presenta un caso de tinea cruris en un paciente varón de 30 años, que fue tratado eficazmente con un medicamento homeopático individualizado. Basándose en la totalidad de los síntomas, el medicamento homeopático *Natrum muriaticum* en potencia 200C como primera dosis, y se observó mejoría en los seguimientos posteriores. En este caso, la atribución causal al medicamento prescrito se estableció mediante la Puntuación de Criterios de Naranjo Modificada. Este caso basado en la evidencia sugiere que la tinea cruris puede tratarse con éxito con un tratamiento homeopático individualizado.

个体化 势 法治 股 ——循 病例报告.

介: 股, 也称 动 瘙痒, 是一种由皮肤 菌引起的皮肤感染, 皮肤 菌是影响生殖器、阴部、会阴和肛周区域的致病真菌。股 更常 于男性, 对成人的影响大于儿童。常 治 包括在大量病例中使用局部抗真菌 物和口服 治。**病例:** 报告一例30 男性患者的股, 患者采用个性化 势 法 物 行了有效治。根据症状的 体情况, 势 法 物 *muriaticum* 在 200C 的效力作 第一, 并在随后的随 中 察到改善。在这种情况下, 处方 的因果归因由改良的 Naranjo 准 分确定。这一基于 据的案例表明, 足 可以通过个体化 势 法治 成功。