

# Endometriotic cyst and fibrocystic disease of the breast treated with individualised homoeopathy – A case report

Bhuvanewari Rajachandrasekar\*, Reshma Radhakrishnan

National Homoeopathy Research Institute in Mental Health, Kottayam, Kerala, India

## Abstract

**Introduction:** Endometriosis is one of the benign gynaecological disorders in childbearing women, characterised by the presence of functioning endometrial tissue outside the uterine mucosa. Fibrocystic disease of the breast is the most common and benign lesion among women of reproductive age group seeking medical advice for breast problems during a lifetime. It is characterised by hyperproliferation of connective tissue or fibrosis, which is followed by facultative epithelial proliferation in the breast tissues. **Case Summary:** A case of a left endometriotic ovarian cyst with multiple cystic lesions in the right breast in a 36-year-old patient successfully treated with individualised homoeopathic medicine is reported. She had severe cyclic lower abdominal pain for more than 7 years, and conventional analgesics and even surgical procedures could not afford relief. Homoeopathic treatment was started with *Silicea* based on the totality of symptoms and repertorisation and later switched to *Conium maculatum* as an anti-miasmatic remedy, which showed disappearance of the left endometriotic cyst and reduction in the size of cystic lesion in the right breast with general improvement. The Modified Naranjo Criteria were used to assess causal attribution to the prescribed medicine in this case. Assessment of pain was done using a visual analogue scale. This evidence-based case reported according to the HOM-CASE guidelines suggested that individualised homoeopathic medicines can be used as a useful, safe and non-invasive mode of treatment for ovarian endometriotic cyst, associated with fibrocystic disease of the breast.

**Keywords:** Case report, *Conium mac*, Endometriotic cyst, Fibro cystic breast, *Silicea*

## INTRODUCTION

Endometriosis is an estrogen-dependent chronic inflammatory condition of women seen in the reproductive period, identified by the presence of endometrial glandular epithelium and stroma outside the uterine cavity.<sup>[1]</sup> The risk of endometriosis seems to increase in women aged 25–35 years.<sup>[2]</sup> It affects 20% of infertile women and 15% of women with chronic pelvic pain.<sup>[3]</sup> Ultrasonography is a readily available, user-dependent and inexpensive tool for the diagnosis of endometriotic lesions.<sup>[4]</sup> Management depends on location, size and extent of the lesion, age of the patient, desire for fertility and results of previous therapy. Conventional therapy comprises medical, surgical and a combination of both depending on the severity and response of medical treatment.<sup>[5]</sup> Symptoms of endometriosis are alleviated in the conventional medicine system by hormonal medications and gonadotropin-releasing hormone agonists or antagonists, whereas surgical treatment mostly amounts to laparoscopy, be it diagnostic or therapeutic. Ovarian reserve, follicular density and fecundity rate may be affected

by surgical excision of the cyst. Moreover, various research works suggest that the efficacy of the surgical intervention is controversial.<sup>[6]</sup> For endometriomas, more than 4 cm size laparoscopic cystectomy is recommended. Recurrence of the cyst is possible following invasive surgery. A few published articles report the effectiveness of homoeopathic medicines in the treatment of endometriotic cyst.<sup>[7-9]</sup>

Fibrocystic disease of the breast commonly affects women between 20 and 50 years of age. Mostly, it presents as dense, irregular and lumpy painful lesions. It may be bilateral and multifocal. Several studies suggest that 30–60% of women in the reproductive age groups suffer from this fibrocystic disease.<sup>[10]</sup> Malignant changes were found to be unlikely in

**\*Address for correspondence:** Bhuvanewari Rajachandrasekar, National Homoeopathy Research Institute in Mental Health, Kottayam, Kerala, India. E-mail: dr.bhuvanewari@gmail.com

**Received:** 01 August 2021; **Accepted:** 03 June 2022

This is an open access journal, and articles are distributed under the terms of the Creative Commons Attribution-NonCommercial-ShareAlike 4.0 License, which allows others to remix, tweak, and build upon the work non-commercially, as long as appropriate credit is given and the new creations are licensed under the identical terms.

**How to cite this article:** Rajachandrasekar B, Radhakrishnan R. Endometriotic cyst and fibrocystic disease of the breast treated with individualised homoeopathy – A case report. Indian J Res Homoeopathy 2022;16(2):87-93.

### Access this article online

#### Quick Response Code:

Available in print version only

**Website:**  
www.ijrh.org

**DOI:**  
10.53945/2320-7094.1017

women with non-proliferative lesions. However, there is a fivefold increase in risk to develop breast cancer in women with proliferative lesions with atypical ductal or lobular hyperplasia.<sup>[11]</sup> An ultrasound is the non-invasive, most convenient and commonly used technique for the diagnosis of breast lesions of various categories and to rule out malignancy. The conventional line of management is carried out mainly for alleviating the pain by pain-killers or by removing fluid through fine needle aspiration. Invasive surgical removal is recommended if there is a constant recurrence of pain.<sup>[12]</sup>

A prospective study by Farland *et al.* put forward a correlation between endometriosis and benign breast disease (BBD). In women with endometriosis, there is an increased risk of BBD.<sup>[13]</sup> We report below a case of left ovarian endometriotic cyst of 7 years duration with comorbid cystic disease of the right breast of recent origin. She had a history of a similar lesion in the right ovary, which had been removed surgically along with the ovary. After that, cystic lesions reappeared in the left ovary, conveying that recurrence occurred even after surgical excision. The left ovarian cyst thoroughly resolved along with the reduction in the cystic changes of the right breast to a substantial amount by homoeopathic intervention.

The case has been reported according to the criteria set out in the HOM-CASE guidelines.<sup>[14]</sup> The Modified Naranjo Criteria were used to assess whether the clinical improvements observed could be attributed to the prescribed homoeopathic medicine. Assessment of pain was done using a visual analogue scale, which is a patient-oriented scale.<sup>[15]</sup> This was a 10-point scale marked as 0–10 where zero indicated ‘no pain’ and 10 indicated ‘worst possible pain’.

## PATIENT INFORMATION

A 38-year-old female patient presented to the outpatient department of National Homoeopathy Research Institute in Mental Health, Kottayam, in December 2019 with complaints of severe lower abdominal pain at the beginning of menstruation for more than 7 years. Pain in the lower abdomen persisted for 6–8 h and was relieved by lying on the abdomen or by applying pressure. Her menstrual cycle was regular, without any clots and bleeding lasted for 4–5 days. She was diagnosed with endometriotic cysts of the left ovary. As per ultrasonography of the abdomen and pelvis in July 2019, there was a small cyst with internal echoes in the left ovary measured  $3.6 \times 3.1 \times 3.4$  cm and  $1.8 \times 1.6 \times 1.5$  cm. She also had a complaint of heaviness and tenderness in the right breast for 2 weeks duration and the stitching type of pain which was worse on the slightest movement of the chest, especially breathing. Pain in the breast increased during menses.

The complaint had started almost 1 year after her first delivery, as a sensation of a lump in the right pelvic region at the age of 27 and was diagnosed as the right endometriotic cyst measuring  $17 \times 8 \times 9$  cm. Considering the massive size, emergency surgical intervention was suggested and right ovarian cystectomy was done in November 2008. USG dated

September 2009 showed recurrence of the cysts measuring  $10.68 \times 7.9$  and  $8.22 \times 2.91$  cm. At the age of 28, she was advised for surgical removal of the right ovary along with the cyst. A few months after the oophorectomy, pain in the lower abdomen during menstruation reappeared. Subsequent USG in January 2011 showed recurrent lymphatic cyst and also a large retention cyst. She took analgesics for relieving the pain during the menses. Gradually, the severity of pain increased and a further USG dated February 2012 reported an endometriotic cyst in the left ovary. Since the patient was in her early 30s and she wanted a second child, the surgical removal of the left ovary was not recommended by gynaecologists. However, despite long years of treatment by infertility specialists and gynaecologists, her strive for conceiving a child was not fulfilled. Her cancer antigen 125 and her husband’s semen analysis reports were within normal range. The patient was worried that she could be infertile due to the pathology of endometriosis. She tried other alternative treatments, but there was no significant improvement in her suffering. She continued to take analgesics for the past 7 years during menstruation.

The patient had chickenpox at the age of 34. She had frequent eructation with chest pain during pregnancy. In ultrasonography dated February 2012, the cyst in the ovary was  $2.8 \times 3.5$  cm and it was gradually increasing in size.

Her paternal grandmother had a history of unknown carcinoma. Mother was dyslipidaemic. The patient was anxious about her complaints as she desired to conceive another child naturally, but was not able to for the past 5 years of treatment. She lost all her hope and was in despair. Her appetite and generals were insignificant. She had more sweat on her back. She had a desire for chicken, fish, tea and spicy things. She preferred warm food and found it difficult to tolerate heat. Her other complaints were: Falling of hair for many years after oophorectomy and hair-growth on the chin. She had a sensation of distended abdomen after eating which was relieved by loud eructation, occasionally associated with stitching pain in the chest.

## GENERAL PHYSICAL EXAMINATION

The patient had a moderate built and her height was 153 cm and weight 55 kg. No pallor, cyanosis, icterus, clubbing, oedema or lymphadenopathy were observed. She was afebrile; her pulse rate was 72 beats/min with a respiratory rate of 16/min. Her BP was 130/70 mmHg.

## ANALYSIS OF THE CASE

The patient was prescribed individualised medicine after repertorisation using RADAR OPUS 22.16 software [Figure 1]. As per the repertorial result, the first prescription was done on 5 December 2019. *Silicea* (*Sil 6c*) was prescribed once a day for a week, followed by placebo for a month. After a month follow-up, the patient complained of severe low back pain; so, the same medicine was repeated in raised potency that is, 30C. In the fourth follow-up, patient complaints of severe low back pain and lower abdominal pain persisted even though

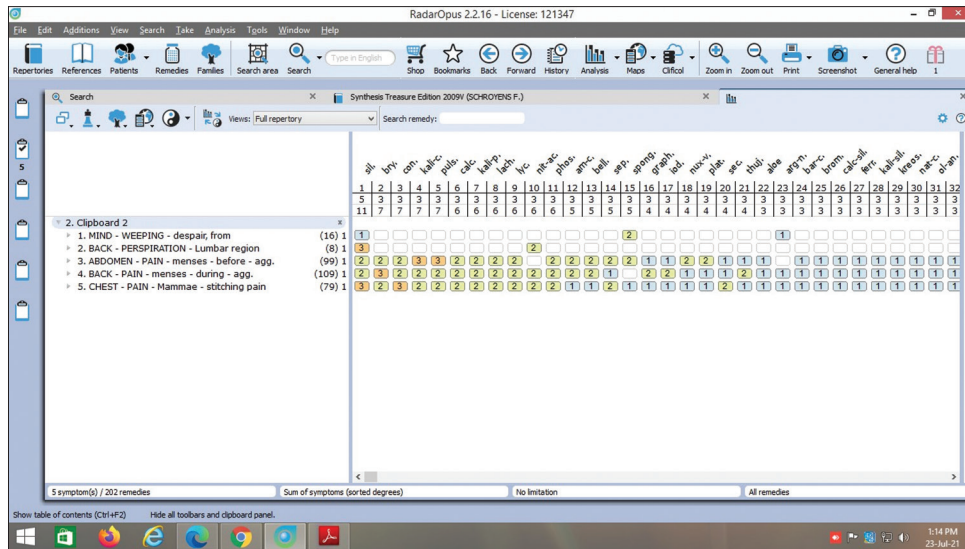


Figure 1: Repertorisation chart

there was a relief for pain in the breast. Subsequently, the case was reanalysed and considering the miasmatic totality, she was given *Conium maculatum* (*Con*) in 30 potency which yielded good results. Case follow-up details are given in Table 1.

## DISCUSSION

This case report shows improvement of symptoms and pathology of endometriomas with individualised and miasmatic remedies, selected, on the basis of totality. The patient had severe dysmenorrhoea for more than 7 years and was prescribed *Sil* on 5 Dec 2019. In her follow-up visit in March 2020, her abdominal complaints worsened and breast complaints improved a little.

An in-depth understanding of the dominant miasm of the patient through the totality of symptoms, individualisation, personal history and family and past histories can give insight into the morbid susceptibility and bring out the cure. In this case, the miasmatic analysis was based on the dominant symptoms of the sycotic miasm such as pathological symptoms (Endometriotic cyst, fibrocystic disease of the right breast, tumours cystic, glands, painful menses, stitching pain abdomen during menses and mental symptoms despair).<sup>[16]</sup> Her paternal grandmother also had a history of unknown carcinoma, her mother was dyslipidaemic.

In the menstruation chapter of 'Boenninghausens characteristics and repertory by Cyrus Maxwell Boger'<sup>[17]</sup> *conium* is presented under the rubrics: 'Concomitants during menses; Mammae' as the highest grade (four marks) remedy and 'Concomitants during menses; Ovaries' as one mark remedy. Therefore, conium 30 was prescribed as an antisycotic drug and repeated weekly for a month to complete the treatment process.

Gradually, her lower abdominal pain also improved; the patient was able to discontinue the use of analgesics for severe dysmenorrhoea. The patient felt delighted about the improvement of her years of suffering. Her USG in January 2021 was normal. The endometriotic cyst resolved with the general well-being

of the patient after homoeopathic treatment. The fibrocystic disease of the right breast had also reduced. Pain in the chest and loud eructation or gastric disturbances also improved.

In the patient's score based on the Modified Naranjo Criteria, zero scores for Criteria 3, 6a, 6b, 7, and 10. Detailing of these scores for Criteria 1 and 2 (Her main complaint was severe lower abdomen pain and backache during menses, which became painless within a plausible period with homoeopathic treatment), 4 and 5 (there was general well-being, along with improvement in loud eructation, distension of abdomen and heaviness of breast), 8 (no other treatment was taken) and 9 (improvement was documented by before and after treatment USG report) as well as the improbability of spontaneous remission with this disorder suggest that the clinical improvement seen could be attributed to the homoeopathic medicine. No initial aggravation was observed (criteria 3=0), the direction of cure (criteria 6b=0) was not established and no old unresolved symptoms reappeared (criteria 7=0) and there is doubt in repeat dosing if conducted, will create similar clinical improvement (criteria 10=0). This allows us to conclude, based on the Modified Naranjo Criteria scores, that there is a causal attribution to disease improvement. Thus, suggesting a definite association between the medicine and the outcome [Table 2].<sup>[14]</sup>

Parveen *et al.*<sup>[7]</sup> presented a case of successful homoeopathic treatment of primary infertility in a female who was long treated for endometriosis. This case report is similar to that case, which was treated with constitutional homoeopathic medicine *Sil* with increasing potencies. Further, through miasmatic analysis, *Syphilinum* was prescribed as an intercurrent remedy. However, there is lack of information of associated fibroadenoma breast after intervention in this study.

Salodiya *et al.*<sup>[9]</sup> treated ovarian endometrioma with LM potency of *Apis mellifica*. The authors highlighted the usefulness of individualised homoeopathic medicines as well as the importance of repertory and repertorisation in pathological cases.

**Table 1: Prescription with follow-up**

Date	Symptoms	Outcome of the assessment	Medicine prescribed with potency and doses
5 December 2019	LMP – 3 December 2019. Baseline symptoms. VAS-8	USG Abdomen and pelvis on July 2019 – small cyst with internal echoes in the left ovary measured 3.6×3.1×3.4 cm and 1.8×1.6×1.5 cm. Mammography breast on November 2019 – Fibrocystic disease of the Right Breast BIRADS FAC II with multiple cystic lesion measured – 2.5×2.7 cm in 8 O'clock position, 0.8×0.9 cm in 6 O'clock position, 0.6×0.7 cm in 5 O'clock position, 0.6×0.8 cm in 2 O'clock position, 1×0.9 cm in 10 O'clock position.	<i>Silicea</i> 6C*/OD**×1 week
7 January 2020	LMP – 4 January 2020. Lower abdominal pain present. (VAS-8). Tenderness and heaviness in the right breast persist. Loud eructation with distended feeling in the abdomen persists.		<i>Sil</i> 6c/OD×1 week
4 February 2020	LMP – 4 February 2020. Severe low back pain and lower abdominal pain during menses present. (VAS-8). Tenderness and heaviness in the right breast relieved. Loud eructation with distended feeling in the abdomen persists.		<i>Sil</i> 30 4D***, 1D/week
17 March 2020	LMP – 3 March 2020. Severe low back pain and lower abdominal pain during menses are present (VAS-8). No tenderness and heaviness in the right breast. Loud eructation with distended feeling in the abdomen persists.		<i>Conium</i> 30 4D, 1D/week
21 April 2020	LMP – 17 April 2020. Lower abdominal pain during menses reduced (VAS-5). No tenderness and heaviness in the right breast. Loud eructation with distended feeling in the abdomen persists.		<i>Conium</i> 30/4D, 1D/week
26 May 2020	LMP – 23 May 2020. Lower abdominal pain during menses reduced (VAS-3). No tenderness and heaviness in the right breast. Loud eructation with distended feeling in the abdomen persists.		<i>Conium</i> 30 4D, 1D/week
23 June 2020	LMP – 12 June 2020. No pain during menses (VAS-0). No tenderness and heaviness in the breast. Loud eructation with distended feeling in the abdomen slightly reduced.	USG on June 2020 – Cyst with dense internal echoes of size 1.9×1.6 cm and 1.8×1.3 cm, Left ovary appears adhered to the uterus, Right mild hydrosalpinx, Mildly bulky uterus with heterogeneous echo texture. USG of Right Breast – Small anechoic focal lesion in 8–9 O'clock position and tiny hypoechoic focal lesions in the inferolateral quadrant.	<i>Conium</i> 30 4D, 1D/week
21 July 2020	LMP – 5 July 2020. No pain during menses (VAS-0), Slight tenderness on the right breast. Loud eructation with distended feeling in the abdomen reduced.		<i>Conium</i> 30 4D, 1D/week
25 August 2020	LMP – 2 August 2020. Slight lower back pain during menses presents (VAS-1). No tenderness and heaviness in the breast. Loud eructation with distended feeling in the abdomen reduced. Numbness of palm present.		<i>Conium</i> 30 4D, 1D/week
22 September 2020	PMP – 3 September 2020 and LMP – 16 September 2020. Low back pain during menses reduced. No tenderness and heaviness in the breast. Loud eructation with distended feeling in the abdomen reduced. Numbness of palm present.		SL/4D, 1D/Week
20 October 2020	LMP – 9 October 2020. Severe pain during menses present (VAS-2). No tenderness and heaviness in the breast. Loud eructation with distended feeling in the abdomen slightly present. Numbness of palm present.		<i>Conium</i> 30/4D, 1D/Week
15 December 2020	LMP – 19 November 2020. No pain during menses (VAS-0). No tenderness and heaviness in the breast. Loud eructation with distended feeling in the abdomen slightly present. Numbness of palm present.	USG Right Breast/Axilla – Simple cysts with no septations in the right breast as 1.6×1.2 cm and 0.5×0.5 cm in 6 O'clock position and 0.6×0.6 cm in 8 O'clock position.	<i>Conium</i> 30/4D, 1D/week
12 January 2021	LMP – 25 December 2020. No pain during menses (VAS-0). No complaint in the breast. No gastric complaints. Numbness of palm present.	USG abdomen/pelvis – The left ovary adherent to the uterus with no evident endometriotic cyst, a slightly retroverted uterus with a small subserous fibroid.	<i>Conium</i> 30/4D, 1D/week

\*C: Centesimal, \*\*OD: Everyday, \*\*\*D: Dose, PMP: Previous Menstrual Period, LMP: Last Menstrual Period, VAS: Visual Analog Scale



**Table 2: Modified Naranjo criteria**

S. No.	Domain	Score
1.	Was there an improvement in the main symptom or condition for which the homeopathic medicine was prescribed?	+2
2.	Did the clinical improvement occur within a plausible time frame relative to the medicine intake?	+1
3.	Was there a homeopathic aggravation of symptoms?	0
4.	Did the effect encompass more than the main symptom or condition (i.e., were other symptoms, not related to the main presenting complaint, Improved or changed)?	+1
5.	Did overall well-being improve? (Suggest using a validated scale or mention about changes in physical, emotional and behavioural elements)	+1
6A.	Direction of cure: Did some symptoms improve in the opposite order of the development of symptoms of the disease?	0
6B.	Direction of cure: Did at least one of the following aspects apply to the order of improvement in symptoms: From organs of more importance to those of less importance? From deeper to more superficial aspects of the individual? From the top downwards?	0
7.	Did 'old symptoms' (defined as non-seasonal and non-cyclical symptoms that were previously thought to have resolved) reappear temporarily during the course of improvement?	0
8.	Are there alternative causes (i.e., other than the medicine) that—with a high probability—could have produced the improvement? (Consider known course of disease, other forms of treatment and other clinically relevant interventions)	+1
9.	Was the health improvement confirmed by any objective evidence? (e.g., investigations, clinical examination, etc.)	+2
10.	Did repeat dosing, if conducted, create similar clinical improvement?	0
	Total Score	8

This case report indicates that homoeopathy is useful in the management of endometriotic cystic disease, where conventional medicine showed only temporary relief to the patient. No adverse effects were observed throughout the course of homoeopathic treatment. Although the study of a single case does not constitute strong evidence, the outcome is encouraging. We propose a study be taken up on a larger population to validate the results of homoeopathy in such comorbid clinical conditions to generalise the outcome of this case study to a wider population.

## CONCLUSION

This evidence-based case report suggests that individualised homoeopathic medicines can be used as a useful, safe and non-invasive mode of treatment for ovarian endometriotic cyst associated with fibrocystic disease of the breast.

## Patient perception

'I am happy that my severe abdominal pain during menses is absent and that I can discontinue the use of analgesics. There is heaviness feeling in the breast and no gastric complaints like loud eructations and distension of the abdomen. I also have a

feeling of well-being which I think is because homoeopathic medicines are not typically hormonal treatments. I am happy to see such improvement in my years of suffering'.

## AUTHORS CONTRIBUTIONS

Dr. Bhuvanewari Rajachandrasekar: Concepts, definition of intellectual content, literature search, data acquisition, data analysis, manuscript preparation, manuscript editing and manuscript review, Guarantor. Dr. Reshma Radhakrishnan: Literature search, data acquisition, data analysis, and manuscript preparation.

## Declaration of patient consent

The authors certify that they have obtained patient consent for anonymously reporting her clinical information and investigation reports in the journal.

## Financial support and sponsorship

Nil.

## Conflicts of interest

None declared.

## REFERENCES

- Vercellini P, Viganò P, Somigliana E, Fedele L. Endometriosis: Pathogenesis and treatment. *Nat Rev Endocrinol* 2014;10:261-75.
- Spaczynski RZ, Duleba AJ. Diagnosis of Endometriosis. In: *Seminars in Reproductive Medicine*. Vol. 21. New York: Theme Medical Publishers, Inc.; 2003. p. 193-208.
- Parasar P, Ozcan P, Terry KL. Endometriosis: Epidemiology, diagnosis and clinical management. *Curr Obstet Gynecol Rep* 2017;6:34-41.
- Hsu AL, Khachikyan I, Stratton P. Invasive and non-invasive methods for the diagnosis of endometriosis. *Clin Obstet Gynecol* 2010;53:413-9.
- Konar H. Endometriosis and adenomyosis. In: *DC Dutta's Textbook of Gynecology*. New Delhi: JP Medical Ltd.; 2016. p. 248-59.
- Macer ML, Taylor HS. Endometriosis and infertility: A review of the pathogenesis and treatment of endometriosis-associated infertility. *Obstet Gynecol Clin* 2012;39:535-49.
- Parveen S, Bhaumik H. Effect of individualised Homoeopathy in the treatment of infertility. *Int J Electrochem* 2018;12:231-9.
- Hunton M. Endometriosis and homoeopathy. *Br Homeopathic J* 1993;82:92-6.
- Salodiya S, Naaz A, Ram H. Ovarian endometrioma treated with LM potency: A case report. *Homeopath Heritage* 2020;39:47-50.
- Wadhwa B. A case report of fibroadenosis alleviated with homoeopathy. *Indian J Res Homoeopathy* 2017;11:196-202.
- Chen YY, Fang WH, Wang CC, Kao TW, Chang YW, Yang HF, *et al*. Examining the associations among fibrocystic breast change, total lean mass, and percent body fat. *Sci Rep* 2018;8:1-6.
- Khan SP, Hussain AI. Diagnosis of fibrocystic disease of breast on ultrasound. *Int J Adv Res* 2019;7:557-60.
- Farland LV, Tamimi RM, Eliassen AH, Spiegelman D, Collins LC, Schnitt SJ, *et al*. A prospective study of endometriosis and risk of benign breast disease. *Breast cancer Res Treat* 2016;159:545-52.
- Lamba CD, Gupta VK, van Haselen R, Rutten L, Mahajan N, Molla AM, *et al*. Evaluation of the modified naranjo criteria for assessing causal attribution of clinical outcome to homeopathic intervention as presented in case reports. *Homeopathy* 2020;109:191-7.
- Crichton N. Visual analogue scale (VAS). *J Clin Nurs* 2001;10:706-6.
- Speight P. A Comparison of the Chronic Miasms, Psora, Pseudopsora, Syphilis, Sycosis. New Delhi: B Jain Publishers (P) Ltd.; 1998.
- Boger CM. Boger Boenninghausen's Characteristics and Repertory with Corrected Abbreviations, Word Index and Thumb Index. 38<sup>th</sup> ed. New Delhi: B. Jain Publishers (P) Ltd.; 2013. p. 675-90.

**Titre: Kyste endométriosique et maladie fibro-kystique du sein traités par homéopathie individualisée - Rapport de cas**

**Résumé: Introduction:** L'endométriose est l'un des troubles gynécologiques bénins des femmes en âge de procréer, caractérisé par la présence de tissu endométrial fonctionnel en dehors de la muqueuse utérine. La maladie fibro-kystique du sein est la lésion bénigne la plus fréquente chez les femmes en âge de procréer qui consultent un médecin pour des problèmes mammaires au cours de leur vie. Elle se caractérise par une hyperprolifération du tissu conjonctif ou fibrose, qui est suivie d'une prolifération épithéliale facultative dans les tissus mammaires. **Résumé du cas:** Nous rapportons le cas d'un kyste ovarien endométriosique gauche avec de multiples lésions kystiques dans le sein droit chez une patiente de 36 ans, traitée avec succès par une médecine homéopathique individualisée. Elle souffrait de douleurs cycliques sévères dans le bas-ventre depuis plus de sept ans, et les analgésiques conventionnels et même les procédures chirurgicales n'ont pas permis de la soulager. Le traitement homéopathique a commencé par Silicea sur la base de la totalité des symptômes et de la répertorisation, puis est passé à Conium maculatum comme remède anti-miasmatique, ce qui a permis de constater la disparition du kyste endométriosique gauche et la réduction de la taille de la lésion kystique du sein droit avec une amélioration générale. Les critères modifiés de Naranjo ont été utilisés pour évaluer l'attribution causale au médicament prescrit dans ce cas. L'évaluation de la douleur a été faite à l'aide d'une échelle visuelle analogique (EVA). Ce cas fondé sur des données probantes, rapporté selon les directives HOM-CASE, suggère que les médicaments homéopathiques individualisés peuvent être utilisés comme un mode de traitement utile, sûr et non invasif pour le kyste endométriosique ovarien, associé à la maladie fibrokystique du sein.

**Titel: Endometriotische Zyste und fibrozystische Erkrankung der Brust, behandelt mit individualisierter Homöopathie – Ein Fallbericht**

**Abstrakt: Einleitung:** Endometriose ist eine der gutartigen gynäkologischen Erkrankungen bei gebärfähigen Frauen, die durch das Vorhandensein von funktionierendem Endometriumgewebe außerhalb der Uterusschleimhaut gekennzeichnet ist. Die fibrozystische Erkrankung der Brust ist die häufigste und gutartige Läsion bei Frauen im gebärfähigen Alter, die im Laufe ihres Lebens wegen Brustproblemen ärztlichen Rat suchen. Sie ist gekennzeichnet durch Hyperprolifération des Bindegewebes oder Fibrose, gefolgt von einer fakultativen Epithelprolifération im Brustgewebe. **Zusammenfassung der Fälle:** Es wird über einen Fall einer linken endometriotischen Ovarialzyste mit mehreren zystischen Läsionen in der rechten Brust bei einer 36-jährigen Patientin berichtet, die erfolgreich mit individualisierten homöopathischen Arzneimitteln behandelt wurde. Sie hatte mehr als sieben Jahre lang starke zyklische Schmerzen im Unterbauch, und herkömmliche Analgetika und selbst chirurgische Eingriffe konnten keine Linderung bringen. Die homöopathische Behandlung wurde mit Silicea auf der Grundlage der Gesamtheit der Symptome und der Reperforierung begonnen und später auf Conium maculatum als antimiasmatiches Mittel umgestellt, das ein Verschwinden der linken endometriotischen Zyste und eine Verringerung der Größe der zystischen Läsion in der rechten Brust mit allgemeiner Besserung zeigte. Die modifizierten Naranjo-Kriterien wurden verwendet, um in diesem Fall die kausale Zuordnung zum verschriebenen Medikament zu beurteilen. Die Schmerzbeurteilung erfolgte mit einer visuellen Analogskala (VAS). Dieser evidenzbasierte Fall, der gemäß den HOM-CASE-Richtlinien berichtet wurde, legte nahe, dass individualisierte homöopathische Arzneimittel als nützliche, sichere und nicht-invasive Behandlungsmethode für endometriotische Ovarialzysten in Verbindung mit fibrozystischer Erkrankung der Brust verwendet werden können.

**शीर्षक: एंडोमेट्रियोटिक गाँठ और स्तन के फाइब्रो-सिस्टिक रोग को व्यक्तिगत होम्योपैथी के साथ इलाज – विषय अध्ययन**

**शीर्षक:** एंडोमेट्रियोटिक गाँठ और स्तन के फाइब्रो-सिस्टिक रोग को व्यक्तिगत होम्योपैथी के साथ इलाज – विषय अध्ययन **सार:** परिचय: एंडोमेट्रियोसिस गर्भवती महिलाओं में सौम्य स्त्री रोग संबंधी विकारों में से एक है, जो गर्भाशय के म्यूकोसा के बाहर एंडोमेट्रियल ऊतक की उपस्थिति को दर्शाता है। स्तन की फाइब्रो सिस्टिक बीमारी प्रजनन आयु वर्ग की महिलाओं के बीच सबसे आम और सौम्य घाव है जिसमें जीवन भर स्तन की समस्याओं के लिए चिकित्सा सलाह की आवश्यकता होती है। यह संयोजी ऊतक या फाइब्रोसिस के अति-प्रतिफलन की विशेषता है, जिसके बाद स्तन ऊतकों में अनाग्रही उपकला का प्रसार होता है। **विषय सारांश:** 36 वर्षीय रोगी में दाएं स्तन में कई गाँठनुमा घावों के साथ एक बाएं एंडोमेट्रियोटिक डिम्बग्रंथि गाँठ के एक विषय को सफलतापूर्वक व्यक्तिगत होम्योपैथिक दवा के साथ इलाज किया गया। उसे सात वर्ष से अधिक समय तक गंभीर बारंबार रूप से निचले पेट में दर्द था, और पारंपरिक दर्दनिवारक और यहां तक कि सर्जिकल प्रक्रियाएं भी राहत नहीं दे सकती थीं। लक्षण सूचिका एवं कुल लक्षणों के आधार पर साइलेसिया द्वारा उपचार प्रारंभ किया गया जिसके पश्चात (प्रति-मियाज्म) के रूप में कोनियम मैकुलेटम में परिवर्तित कर दिया गया, जिससे बाएं एंडोमेट्रियोटिक पुटी के गायब होने और सामान्य सुधार के साथ दाएं स्तन में सिस्टिक घाव के आकार में कमी दिखाई दी। संशोधित नारंजो मानदंड का उपयोग इस मामले में निर्धारित दवा के कारण लक्षण का आकलन करने के लिए किया गया था। दर्द का मूल्यांकन एक दृश्य एनालॉग स्केल (वीएस) का उपयोग करके किया गया था। एचओएम-केस दिशानिर्देशों के अनुसार रिपोर्ट किए गए इस साक्ष्य-आधारित मामले ने सुझाव दिया कि व्यक्तिगत होम्योपैथिक दवाओं का उपयोग डिम्बग्रंथि एंडोमेट्रियोटिक पुटी के लिए उपचार के एक उपयोगी, सुरक्षित और गैर-आक्रामक मोड़ के रूप में किया जा सकता है, जो स्तन के फाइब्रोसिस्टिक रोग से जुड़ा हुआ है।

## **Título: Quiste endometriótico y enfermedad fibroquística de la mama tratada con Homeopatía individualizada: Un caso práctico**

**Resumen: Introducción:** La endometriosis es uno de los trastornos ginecológicos benignos en mujeres en edad fértil, caracterizado por la presencia de tejido endometrial funcional fuera de la mucosa uterina. La enfermedad fibroquística de la mama es la lesión más común y benigna entre las mujeres en edad reproductiva que buscan asesoramiento médico para los problemas de la mama durante toda la vida. Se caracteriza por la hiperproliferación del tejido conjuntivo o fibrosis, seguida por la proliferación epitelial facultativa en los tejidos mamarios. Resumen del caso: Se informa de un caso de quiste ovárico endometriótico izquierdo con múltiples lesiones quísticas en la mama derecha en un paciente de 36 años de edad tratado con éxito con medicina homeopática individualizada. Ella tuvo dolor abdominal inferior cíclico severo por más de siete años, y los analgésicos convencionales e incluso los procedimientos quirúrgicos no podían permitirse el alivio. El tratamiento homeopático se inició con *Silicea* en base a la totalidad de los síntomas y la repertorización y posteriormente se cambió a *Conium maculatum* como remedio anti miasmático, que mostró desaparición del quiste endometriótico izquierdo y reducción del tamaño de la lesión quística en la mama derecha con mejoría general. Los Criterios de Naranjo Modificados se utilizaron para evaluar la atribución causal al medicamento prescrito en este caso. La evaluación del dolor se realizó mediante una escala visual analógica (VAS). Este caso basado en la evidencia reportado de acuerdo con las guías DEL CASO de HOM, sugirió que los medicamentos homeopáticos individualizados pueden ser usados como un modo útil, seguro y no invasivo de tratamiento para el quiste endometriótico ovárico, asociado con enfermedad fibroquística de la mama.

标题: 个体化顺势疗法治疗乳腺子宫内膜囊肿和纤维囊性疾病-一例报告

摘要: 引言: 子宫内膜异位症是生育妇女的良性妇科疾病之一, 特征在于子宫粘膜外存在功能性子宫内膜组织. 乳腺纤维囊性疾病是生育年龄段妇女一生中寻求乳房问题医疗建议的最常见和良性病变. 其特征在于结缔组织过度增殖或纤维化, 随后在乳腺组织中兼性上皮增殖. 个案摘要: 报道了一例左子宫内膜异位性卵巢囊肿, 右乳房有多个囊性病变, 一名36岁患者成功接受个体化顺势疗法治疗. 她有严重的环状下腹部疼痛超过七年, 常规镇痛药甚至外科手术都无法缓解. 顺势疗法的治疗是从砒谷开始的, 基于症状和再治疗的总体性, 后来转用黄斑锥体作为抗瘴气的治疗方法, 显示左子宫内膜囊肿消失, 右乳房囊性病变大小减少, 整体改善. 修改后的纳兰乔标准被用于评估在这种情况下对方药的因果归因. 使用视觉模拟量表 (VAS) 进行疼痛评估. 根据家居个案指南报告的这一基于证据的病例表明, 个体化的顺势疗法; 顺势疗法药物可用作治疗卵巢子宫内膜异位囊肿的有用, 安全和非侵入性模式, 与乳腺纤维囊性疾病.