

A 15-mm urinary calculus expelled with homoeopathic medicine - A case report

Seema Rai^{1*}, K. R. Vineetha²

¹Department of Materia Medica, Dr. B. R. Sur Homoeopathic Medical College, Hospital and Research Centre, Nanak Pura, Moti Bagh, ²Department of Practice of Medicine, Nehru Homoeopathic Medical College and Hospital, New Delhi, India

Abstract

Introduction: Renal or ureteric colic is an acute and severe pain caused by obstruction in the ureter. It usually occurs in the narrower areas of the ureter. It can be associated with severe pain, nausea, vomiting, urinary infections, haematuria, hydronephrosis, etc. **Case Summary:** A case of 15-mm calculus, lodged at the right ureterovesicular junction, presented with severe cutting pain extending downwards from the right lumbar region to the right groin area. The patient had severe pain at the conclusion of urination. Another calculus of size 10 mm in the lower calyx of the left kidney and 3.4-mm concretion in the right kidney was also detected. The homoeopathic medicine *Sarsaparilla* was given on the basis of totality of symptoms for 3 days. The pain reduced in 3 days and subsequent to an acute colicky pain and some bleeding, on the 11th day, the stone was expelled. This case report shows the potential of Homoeopathy in cases of large urinary calculi.

Keywords: Homoeopathy, Nephrolithiasis, *Sarsaparilla*, Ureterovesicular junction, Urinary calculi, Urolithiasis

INTRODUCTION

Nephrolithiasis is the third most common disorder of the urinary tract after urinary tract infection and prostatic hyperplasia. Urolithiasis affects about 12% of the world population at some stage in their lifetime.^[1] It affects all ages, sex and races^[2,3] but occurs more frequently in men than in women within the age of 20–49 years.^[4] In addition to the common potential sequelae associated with kidney stones, such as pain, infection and obstruction, nephrolithiasis is also considered a risk factor for chronic kidney disease.^[5]

Globally, kidney stone disease prevalence and recurrence rates are increasing,^[6] with limited options of effective drugs. The high prevalence and recurrent nature of kidney stones contribute to the large economic burden on society related to stone disease.

Current conventional treatment options include extracorporeal shock wave lithotripsy, percutaneous nephrolithotomy, retrograde intrarenal surgery and laparoscopic ureterolithotomy.^[7]

Homoeopathic literature provides a good scope for treating cases of urolithiasis and at the same time prevents recurrence. The presenting case shows the efficacy of homoeopathic

medicine in expulsion of a large urinary calculus (15 mm) which is otherwise considered to be a surgical case. There was moderate pain and discomfort to the patient during the episode. The case also shows some reduction in size of other calculi present (apart from 15-mm calculus) after treatment with homoeopathic medicine.

PATIENT INFORMATION

A moderate, dark-complexioned male of 24 years of age reported to the outpatient department (OPD) of Nehru Homoeopathic Medical College and Hospital, New Delhi on 25 June 2019 with severe cutting pain in the right lumbar region which extended to the lower abdomen for 4 days.

The pain started gradually around 2 months back as a dull aching sensation in the right lumbar region. The pain continued as such

***Address for correspondence:** Dr. Seema Rai,
Department of Materia Medica, Dr. B. R. Sur Homoeopathic Medical College,
Hospital and Research Centre, Nanak Pura, Moti Bagh (West), New Delhi, India.
E-mail: seemarai_01@yahoo.com

Received: 27.06.2020; **Accepted:** 28.05.2021; **Published:** 29.06.2021.

Access this article online

Quick Response Code:



Website:
www.ijrh.org

DOI:
10.4103/ijrh.ijrh_19_20

This is an open access journal, and articles are distributed under the terms of the Creative Commons Attribution-NonCommercial-ShareAlike 4.0 License, which allows others to remix, tweak, and build upon the work non-commercially, as long as appropriate credit is given and the new creations are licensed under the identical terms.

For reprints contact: WKHLRPMedknow_reprints@wolterskluwer.com

How to cite this article: Rai S, Vineetha KR. A 15-mm urinary calculus expelled with homoeopathic medicine - A case report. *Indian J Res Homoeopathy* 2021;15:155-61.

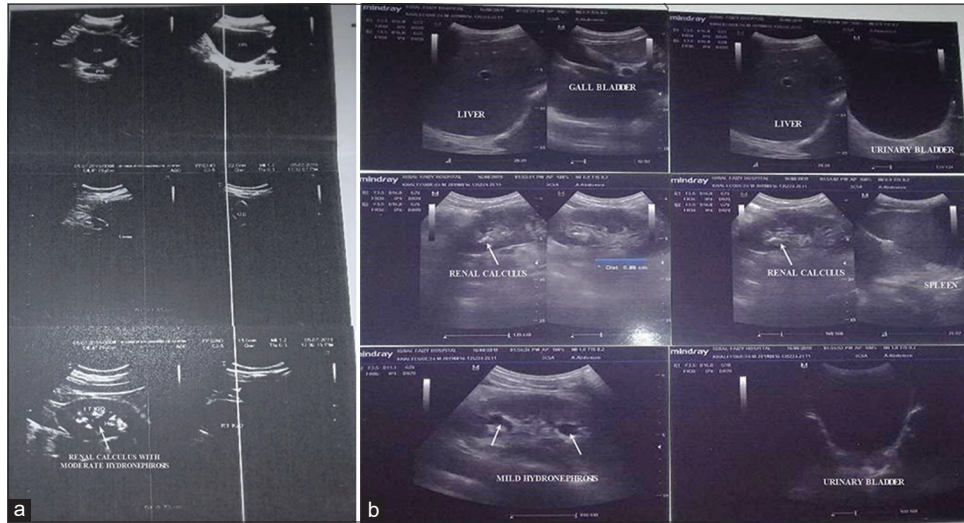


Figure 1: (a and b) USG reports, before (25 June 2019) and after (16 August 2019) treatment

for a month and was ignored by the patient as it was not severe. Subsequently, the pain intensity increased with dysuria and yellowish urine. There was increased frequency and urgency of urination. There was burning sensation while urinating and pain was more at the end of micturition. The pain had suddenly become severe with extension to the lower abdomen for 4 days before the initial presentation. The patient was much depressed due to pain. The urinary flow was interrupted and quantity of urine was reduced. He had taken a few doses of analgesics.

Clinical Findings

A thorough physical examination of the patient revealed no abnormal findings except moderate tenderness in the lumbar region.

Diagnostic assessment

Routine haemogram, serum calcium levels and renal function tests such as serum urea, creatinine, uric acid and serum albumin levels were found to be within normal range. Routine and microscopic examination of urine showed yellowish urine with 4–5 red blood cells. Ultrasound was done which revealed ‘a calculus of 10 mm in the lower pole of the left kidney, a 3.4 mm concretion in the right kidney and a 16 mm calculus in the right ureterovesicular (UV) junction with upstream hydronephrosis’ [Figure 1a].

Assessment of severity of disease condition was done at the first visit and then during all the follow-up visits. The Baseline Assessment Scoring Form, containing 8 items (pain, haematuria, dysuria, number of stones, size of stone, position of stone in kidney/ureter/bladder), was filled up during each visit as a part of a research study going on in renal stones. These symptoms were rated on a 4-point scale, based on the severity of symptoms, from ‘0’ meaning ‘absent’ to ‘3’ meaning ‘severe’. A total of these symptoms’ score was again rated under three categories of mild (score 1–7), moderate (score 8–14) and severe (score 15–23).^[8]

Therapeutic intervention

At the initial presentation, the symptom score of the patient was 16, i.e. severe. Symptoms of the patient were recorded and medicine was selected on the basis of acute symptom totality. *Sarsaparilla* turned out to be the leading

MIND	Remedies	ΣSym	ΣDeg	Symptoms
1 MIND - SADNESS - despair; with	sars.	7	17	1, 2, 3, 4, 5, 6, 7
2 MIND - SADNESS - pain, from	lyc.	5	14	3, 4, 5, 6, 7
BLADDER	berb.	5	12	3, 4, 5, 6, 7
3 BLADDER - URINATION - urging to urinate	canth.	5	9	3, 4, 5, 6, 7
KIDNEYS	oci.	5	7	3, 4, 5, 6, 7
4 KIDNEYS - PAIN - extending to - Bladder	tab.	5	7	3, 4, 5, 6, 7
5 KIDNEYS - PAIN - Ureters - right	arg-n.	4	8	3, 4, 6, 7
6 KIDNEYS - PAIN - Ureters - cutting pain	bell.	4	8	3, 4, 6, 7
7 KIDNEYS - STONES	dios.	4	8	3, 5, 6, 7
	nux-v.	4	8	3, 5, 6, 7
	op.	4	7	3, 4, 6, 7
	lach.	4	6	3, 4, 6, 7
	nit-ac.	4	6	2, 3, 4, 7
	coc-c.	4	5	3, 4, 6, 7
	pareir.	3	9	3, 6, 7

Figure 2: Repertorisation Chart: Synthesis repertory. Version 10.0.028




Figure 3: Dimensions of stone after expulsion

Table 1: Follow-up

Date	Main symptom	Laboratory findings	Symptom score	Medicine prescribed	Basis of prescription
25 June 2019	Severe cutting pain in the right lumbar region which extended to groin. Dull aching in the right lumbar region. Dysuria and yellowish urine	USG - a calculus of 10 mm in the lower pole of the left kidney, a 3.4-mm concretion in the right kidney and a 16-mm calculus in the right ureterovesicular junction causing upstream hydronephrosis. Blood reports - normal. Urine - microscopic haematuria	16	<i>Sarsaparilla</i> 30/TDS/3 days	Reportorial analysis of the totality of symptoms
29 June 2019	Dull aching in the right lumbar region. Urine slightly yellowish		14	<i>Sarsaparilla</i> 30/TDS/3 days	Symptoms better but persisting
3 July 2019	Dull aching in the right lumbar region. Urine slightly yellowish		14	<i>Sarsaparilla</i> 30/TDS/3 days	Symptoms better but persisting
6 July 2019	A stone was expelled following an acute colicky pain followed by some bleeding	Expelled stone was measured, the maximum length of which was 15 mm, whereas the maximum width was 10 mm	16	Sac lac / TDS/3days	Relief to the patient after expulsion of stone
7 July 2019	Slight burning in urethra while urinating		12	Sac lac / TDS/3days	Relief to the patient
10 July 2019	No pain or urinary complaints		12	Sac lac / TDS/	Relief to the patient. Asked to report after USG report
17 August 2019	No pain or urinary complaints	USG - a calculus of 8.8 mm in the lower calyx of the left kidney and concretions in the right kidney of size 2-3 mm Blood reports - normal Urine reports - normal	8	<i>Lycopodium clavatum</i> 200/1 dose	The medicine was changed to <i>Lycopodium clavatum</i> on the basis of totality of the case as a chronic one with symptoms - anger from contradiction, anxiety from anticipation, pain in kidneys with colic, desire for warm drinks, hot patient and kidney stones. On follow-up, there was no acute symptoms or discomfort to the patient. But in USG smaller stones were found in both kidneys.

USG: Ultrasound sonography test

medicine in the repertorisation analysis with synthesis repertory, covering maximum rubrics (7) and scoring highest points (17) [Figure 2].^[9] *Sarsaparilla* was prescribed in the 30C potency thrice daily for 3 days. The patient was also advised for dietary management like intake of plenty of water, lime juice, avoidance of spinach, etc.

Follow-ups and outcomes

On the 2nd visit, the patient reported that the pain had reduced to a moderate level, but persisting. *Sarsaparilla* 30C was repeated for 3 days on follow-up visits [Table 1]. The stone was expelled on the 11th day with an acute colicky pain and slight bleeding. The stone was brought to the OPD by the patient. It was measured, the maximum length of which was 15 mm, whereas the maximum width was 10 mm [Figure 3]. The size of stone, as revealed in the first Ultrasound sonography test (USG) report, was 16 mm. There were some small particles as well which were the broken pieces of the big one. After expulsion of the stone, USG abdomen was performed in the next month only due to non-compliance by the patient earlier, which showed a calculus of size 8.8 mm in the lower calyx of the left kidney and concretions with size of 2–3 mm in the right kidney. There was no calculus in the right UV junction [Figure 1b]. There

was also some reduction in the size of the calculus in the left kidney, which was reduced from 10 mm to 8 mm. The patient is undergoing homoeopathic treatment for the remaining stones. The follow-ups show no discomfort or pain to the patient till now. The dietary restrictions are being followed as such.

DISCUSSION

Urolithiasis places a significant economic burden on the healthcare system, especially in industrialised countries where, owing to changes in lifestyle and diet, the incidence will probably continue to increase for a number of reasons, one of which is global warming.^[10] In various studies conducted by conventional medicine, it is shown that stones measuring 5–7 mm frequently pass spontaneously and stones larger than 10 mm do not pass spontaneously and referral to a urologist for active stone removal is warranted in almost all the large (>10 mm) stones and require procedural intervention.^[11-15]

All the procedures to deal with urinary calculus seem to have physical or surgical approaches and have limitations and may lead to complications. Under surgical approaches, the patients could have faced internal urinary injuries too.^[7,16,17] Recurrence

of the diseases, incomplete cure, with side effects and high cost of remedies and interventions of the conventional medical science needs an alternative therapy such as Homoeopathy for treatment of ureterolithiasis.

Homoeopathic system of medicine has already proved its efficacy in combating various urinary diseases. There are several studies which have shown the effectiveness of the homoeopathic interventions prescribed in cases of nephrolithiasis and dissolution and expulsion of bigger stones through homoeopathic treatment.^[8,18-23] Homoeopathy treats the chronic cases including urolithiasis with the holistic approach where we follow the principle of law of similia. These cases were mostly treated successfully with polycrest remedies or medicines selected on the basis of constitutional totalities.

Many homoeopathic remedies such as *Hydrangea arborescens*, *Berberis vulgaris*, *Ocimum canum*, *Lycopodium clavatum* and *Sarsaparilla* are well-known medicines for treatment of calculus.

The present case report was aimed to present remarkable effect of *Sarsaparilla* in controlling renal calculi. The mention of this is found in homoeopathic literature too.^[24-28] The literature sources suggest its right-sided affinity for calculi, and in this case also, it has shown remarkable result with expulsion of a 15-mm stone; at the same time, it has acted on the calculus present in the left kidney, also leading to slight reduction in the size. Pain and discomfort did not require any painkillers. Selection of medicine was done on the basis of totality of symptoms. This case is in support of the earlier studies that showed effectiveness of homoeopathic intervention in urolithiasis cases on the basis of constitutional totality of the cases.^[8,18-23]

It is concluded that positive response and restoration of health in a gentle manner within specific time, without any surgical intervention, as observed in the present case study, signifies that the dissolution or expulsion of the stones is possible by the well-selected constitutional or individualised treatment and it shows the potential of Homoeopathy in difficult surgical cases.

CONCLUSION

The case report shows that a surgical case of urinary calculus can be well managed under homoeopathic treatment. We can see the potential of Homoeopathy in treating such difficult cases without surgery, which suggests the utility of homoeopathic medicines in urolithiasis. The case also shows some reduction in size of the stone, which could be due to the stone dissolving property of *Sarsaparilla*. There is a need for further research to find out the stone dissolving powers of homoeopathic medicines.

Declaration of patient consent

The authors certify that they have obtained all appropriate patient consent forms. In the form, the patient has given his consent for reporting his images and other clinical information

in the journal. The patient understands that his name and initials will not be published and due efforts will be made to conceal identity, but anonymity cannot be guaranteed.

Financial support and sponsorship

Nil.

Conflicts of interest

None declared.

REFERENCES

1. Chauhan CK, Joshi MJ, Vaidya AD. Growth inhibition of struvite crystals in the presence of herbal extract *Commiphora wightii*. *J Mater Sci Mater Med* 2009;20 Suppl 1:S85-92.
2. Moe OW. Kidney stones: Pathophysiology and medical management. *Lancet* 2006;367:333-44.
3. Romero V, Akpınar H, Assimos DG. Kidney stones: A global picture of prevalence, incidence, and associated risk factors. *Rev Urol* 2010;12:e86-96.
4. Edvardsson VO, Indridason OS, Haraldsson G, Kjartansson O, Pálsson R. Temporal trends in the incidence of kidney stone disease. *Kidney Int* 2013;83:146-52.
5. Gambaro G, Croppi E, Coe F, Lingeman J, Moe O, Worcester E, et al. Metabolic diagnosis and medical prevention of calcium nephrolithiasis and its systemic manifestations: A consensus statement. *J Nephrol* 2016;29:715-34.
6. Knoll T. Epidemiology, pathogenesis and pathophysiology of urolithiasis. *Eur Urol Suppl* 2010;9:802-6.
7. Munjal YP. *API Textbook of Medicine*. Vol. I & II. Mumbai: JP Medical Ltd; 2015. p. 1800.
8. Siddiqui VA, Singh H, Gupta J, Nayak C, Singh V, Sinha MN, et al. A multicentre observational study to ascertain the role of homoeopathic therapy in urolithiasis. *Indian J Res Homoeopathy* 2011;5:30-9.
9. RADAR Computer Programme. Belgium: Version 10 Developed by Archibel Homoeopathic Software Company; 2009.
10. Walter L, Strohmaier WL. Recent advances in understanding and managing urolithiasis. *F1000Res* 2016;5:2651.
11. Türk C, Petřík A, Sarica K, Seitz C, Skolarikos A, Straub M, et al. EAU guidelines on diagnosis and conservative management of urolithiasis. *Eur Urol* 2016;69:468-74.
12. Wright PJ, English PJ, Hungin AP, Marsden SN. Managing acute renal colic across the primary-secondary care interface: A pathway of care based on evidence and consensus. *BMJ* 2002;325:1408-12.
13. Coll DM, Varanelli MJ, Smith RC. Relationship of spontaneous passage of ureteral calculi to stone size and location as revealed by unenhanced helical CT. *AJR* 2002;178:101-3.
14. Demehri S, Steigner ML, Sodickson AD, Houseman EA, Rybicki FJ, Silverman SG. CT-based determination of maximum ureteral stone area: A predictor of spontaneous passage. *AJR Am J Roentgenol* 2012;198:603-8.
15. Tehey DU, Ha YS, Kim WT, Yun SJ, Lee SC, Kim WJ. Expectant management of ureter stones: Outcome and clinical factors of spontaneous passage in a single institution's experience. *Korean J Urol* 2011;52:847-51.
16. Rubin JI, Arger PH, Pollack HM, Banner MP, Coleman BG, Mintz MC, et al. Kidney changes after extracorporeal shock wave lithotripsy: CT evaluation. *Radiology* 1987;162:21-4.
17. Baumgartner BR, Dickey KW, Ambrose SS, Walton KN, Nelson RC, Bernardino ME. Kidney changes after extracorporeal shock wave lithotripsy: Appearance on MR imaging. *Radiology* 1987;163:531-4.
18. Misra A, Nayak C, Carcinosis PB. A boon for paediatric nephrolithiasis: Case reports. *World J Pharm Res* 2018;7:922-31.
19. Sharma S, Wadhvani GG. Experience with homoeopathy in a case of large urethral calculus. *Indian J Res Homoeopathy* 2013;7:176-80.
20. Gupta AK, Gupta J, Siddiqui VA, Mishra A. Case record: A big urinary calculus expelled with homoeopathic medicine. *Indian J Res Homoeopath* 2008;2:50-5.

Rai and Vineetha: A 15-mm urinary calculus expelled with homoeopathic medicine

21. Sumithran PP. A case of multiple urinary calculi. *Indian J Res Homoeopathy* 2016;10:142-9.
22. Chintamani N, Ratna SA, Chaturbhuj N, Umakanta P, Kumar HA, Biswaranjan P. A case report of ureteric calculus treated with homoeopathic medicine, *Hydrangea arborescens* 30. *Indo American Journal of Pharmaceutical Sciences*. 2018 ;5:627-33.1.
23. Gupta G, Acharya A, Nayak C. Urolithiasis and homoeopathy: a case series. *World J Pharm Res*. 2018;7:908-31.
24. Hering C. *Guiding Symptoms of Our Materia Medica*. New Delhi: B Jain Publishers Pvt. Ltd.; 1995.
25. Clarke JH. *A Dictionary of Practical Materia Medica*. Vol. II & III. New Delhi: B. Jain Publishers Pvt. Ltd.; 2005.
26. Farrington EA. *A Clinical Materia Medica*. 10th ed. New Delhi: B Jain Publishers Pvt. Ltd.; 2006.
27. Hughes R. *A Manual of Pharmacodynamics*. New Delhi: B Jain Publishers Pvt. Ltd.; 1994.
28. Hahnemann S. *The Chronic Diseases*. New Delhi: B Jain Publishers Pvt. Ltd.; 1995.

एक 15 मिलीमीटर मूत्रीय पथरी को होम्योपैथिक दवा के माध्यम से निकाला गया था – एक मामला प्रतिवेदन

प्रस्तावना: गुर्दा या यूरेटरिक शूल एक प्रखर एवं तीव्र दर्द है जो मूत्रवाहिनी में अवरुद्धता की वजह से होता है। यह सामान्यतौर पर मूत्रवाहिनी के संकुचित क्षेत्रों में होता है। इसे तीव्र दर्द, मतली, उल्टी, मूत्रवाहिनी संक्रमण, रक्तमेह, हाइड्रोनेफ्रोसिस इत्यादि से जोड़ा जा सकता है। **मामले का सारांश:** एक 15 मिलीमीटर की पथरी वाला मामला, दायें यूरेटेरो-वेसिकुलर संधि-स्थल में स्थित, जो दायें कटि-क्षेत्र से दायें श्रोणि क्षेत्र की तरफ नीचे की ओर बढ़ते हुए तीव्र कटाव दर्द से प्रदर्शित हो रहा है। मरीज को पेशाब करते समय बहुत तेज दर्द हो रहा है। दायें गुर्दे के निचले पुटक में 100 एमएम आकार की एक अन्य पथरी तथा दायें गुर्दे में 3.44 एमएम के संघनन का भी पता लगाया गया था। लक्षणों की संपूर्णता के आधार पर सारसापरिला नामक होम्योपैथिक दवा तीन दिनों के लिए दी गई थी। तीन दिनों में दर्द कम हो गया तथा पेट में तीव्र दर्द और थोड़े से रक्तस्राव के अतिरिक्त, ग्यारहवें दिन पथरी निकल गई थी। इस मामले में प्रतिवेदन ने मूत्रवाहिनी की बड़ी पथरी के मामलों में होम्योपैथी की क्षमता को दर्शाया है।

UN CALCUL URINAIRE DE 15 MM EXPULSÉ AVEC LA MÉDECINE HOMÉOPATHIQUE – UN CAS À RAPPORT

Introduction: La colique rénale ou urétérale est une douleur aiguë et sévère causée par une obstruction de l'uretère. Il se produit généralement dans les zones les plus étroites de l'uretère. Elle peut être associée à des douleurs intenses, des nausées, des vomissements, des infections urinaires, une hématurie, une hydronéphrose, etc. **Résumé du cas:** Un cas de calcul de 15 mm, logé à la jonction urétéro-vésiculaire droite, s'est présenté avec une douleur coupante sévère s'étendant vers le bas de la région lombaire droite à la région de l'aîne droite. Le patient avait une douleur intense à la fin de la miction. Un autre calcul de taille 10 mm dans le calice inférieur du rein gauche et une concrétion de 3,4 mm dans le rein droit a également été détecté. Le médicament homéopathique Sarsaparilla a été administré pour 3 jours sur la base de la totalité des symptômes. La douleur a diminué en 3 jours et à la suite d'une douleur aiguë de colique et de quelques saignements, le 11e jour, la pierre a été expulsée. Ce rapport de cas montre le potentiel de l'homéopathie dans les cas de gros calculs urinaires.

UN CÁLCULO URINARIO DE 15 MM EXPULSADO CON MEDICINA HOMOEOPÁTICA - REPORTE DE UN CASO

Introducción: El cólico renal o ureterico es un dolor agudo y severo causado por la obstrucción en el uréter. Generalmente ocurre en las áreas más estrechas del uréter. Puede estar asociada con dolor severo, náuseas, vómitos, infecciones urinarias, hematuria, hidronefrosis, etc. **Resumen del caso:** Un caso de cálculo de 15 mm, alojado en la unión uretero-vesicular derecha, presentaba un fuerte dolor de corte que se extendía hacia abajo desde la región lumbar derecha hasta la zona inguinal derecha. El paciente tuvo dolor severo al final de la micción. También se detectó otro cálculo de tamaño 10mm en el cáliz inferior del riñón izquierdo y 3,4mm en la concreción del riñón derecho. La medicina homoeopática Sarsaparilla se dio sobre la base de la totalidad de los síntomas durante 3 días. El dolor se redujo en 3 días y después de un dolor colicky agudo y un poco de sangrado, en los 11th días que la piedra fue expulsada. Este informe de caso muestra el potencial de la Homeopatía en casos de cálculos urinarios grandes.

EIN MIT HOMÖOPATHISCHER MEDIZIN VERTRIEBENER 15-MM-HARNSTEIN – EIN FALLBERICHT

Einleitung: Nieren - oder Ureterkolik ist ein akuter und starker Schmerz, der durch Obstruktion im Harnleiter verursacht wird. Sie tritt gewöhnlich normalerweise in den engeren Bereichen des Harnleiters auf. Sie kann mit starken Schmerzen, Übelkeit, Erbrechen, Harnwegsinfektionen, Hämaturie, Hydronephrose usw. verbunden sein. **Fallzusammenfassung:** Ein Fall von 15 mm Kalkül, am rechten uretero-vesikulären Übergang abgelegt, mit starken Schnittschmerzen dargestellt, die sich vom rechten Lendenbereich nach unten in die rechte Leistengegend erstrecken. Patient hatte starke Schmerzen am Ende des Wasserlassens. Ein weiterer Kalkül der Größe 10mm im unteren Kelch der linken Niere und 3,4 mm Konkretion in der rechten Niere wurde ebenfalls nachgewiesen. Die homöopathische Medizin Sarsaparilla wurde auf der Grundlage der Gesamtheit der Symptome für 3 Tage gegeben. Der Schmerz verringerte sich in 3 Tagen nach und nach einem akuten kolikartigen Schmerz und einigen Blutungen wurde am 11. Tag der Stein ausgestoßen am 11. Dieser Fallbericht zeigt das Potenzial der Homöopathie bei großen Harnsteinen.

顺势疗法治疗15毫米尿路结石-个案报告

导言: 肾或输尿管绞痛是由输尿管阻塞引起的急性和剧烈疼痛。它通常发生在输尿管较窄的区域。它可以与严重的疼痛, 恶心, 呕吐, 尿路感染, 血尿, 肾积水等有关。病例摘要: 一例15毫米结石, 位于右输尿管-水泡交界处, 呈现从右腰区向下延伸至右腹股沟区的严重切割疼痛。患者在排尿结束时有剧烈疼痛。另外还检测到左肾下萼10mm大小的结石和右肾3.4mm的结石。顺势疗法药物蒺藜在症状的基础上给予3天。疼痛在3天内减轻, 随后出现急性绞痛和一些出血, 在第11天将石头驱逐出境。本病例报告显示了在大尿结石病例中顺势疗法的潜力。