

Homoeopathic Treatment of Viral Warts with *Calcarea phosphorica*

Nidhi Mahajan*, Ashish Mahajan, Aditi Bhinda, Sapna Salodiya
Central Research Institute of Homoeopathy, Jaipur, Rajasthan, India

Abstract

Introduction: Viral warts are the most common cutaneous infection caused by human papillomavirus. Warts can be treated by many available modalities such as cryotherapy, chemical cauterization, curettage, electrodesiccation and laser removal. However, most of these therapies can cause scarring. They also cause application-site reaction and recurrence. The homoeopathic literature has a plethora of medicines for the treatment of warts. **Case Summary:** A 4-year-old girl presented with reappearance of multiple warts on the face after a month of laser treatment. This time, the warts were on the right side of the forehead and one on the right cheek and were persisting for 8 months. The patient responded well to individualised homoeopathic treatment, i.e. *Calcarea phosphorica* 200 in single dose with complete recovery within 1 month without subsequent relapse. Even though the medicine is mentioned in the fourth grade against the rubric 'Face – Warts' in the Complete Repertory and is not used commonly in the cases of warts, it acted beneficially. Hence, this case emphasises the importance of individualised homoeopathic treatment based on characteristic general symptoms.

Keywords: *Calcarea phosphorica*, Homoeopathy, Viral warts

INTRODUCTION

Viral warts are a common skin condition, which can range in severity from a minor nuisance that resolve spontaneously to a troublesome, chronic condition.^[1] These are small skin protuberances caused by human papillomavirus (HPV), are not life-threatening, but can be unsightly, embarrassing, uncomfortable and potentially contagious^[2] and may be transmitted by direct or indirect contact.^[3]

Common warts mainly present in children although people at any age can be affected. Warts, in general, are benign but sometimes they may become malignant and develop into verrucous carcinoma. The diagnosis of a wart is usually made on a clinical examination and physical findings.^[4]

Warts need to be distinguished either clinically or histologically from other keratotic lesions on the hands or feet such as actinic keratosis, knuckle pads or more rarely, squamous cell carcinoma or focal palmoplantar keratoderma. On the feet, corns and calluses or callosities can be confused with warts.^[5]

Warts may regress naturally but over a prolonged time. Recurrences are also known.^[2] Recurrence rate of up to 30%

has been reported with cryotherapy, probably due to lack of immune response. The viruses might remain in the skin after treatment and then lead to the growth of new warts later.^[6]

Treatment of warts is especially challenging in the paediatric patient population because of the pain associated with many of the available treatments.^[7] Overall, trials comparing cryotherapy with placebo showed no significant difference in effectiveness. Adverse effects, such as pain, blistering and scarring, were not consistently reported but are probably more common with cryotherapy.^[1] Treatment-resistant warts are a common and frustrating problem for patients, parents and providers alike. No wart treatment is uniformly effective.^[8]

Much of the contemporary society is more interested in fast and impressive cures, even if these may bring side effects, whereas Homoeopathy can offer solutions with a personalised approach

***Address for correspondence:** Dr. Nidhi Mahajan,
Central Research Institute of Homoeopathy, Jaipur, Rajasthan, India.
E-mail: drnidhimahajan1@gmail.com

Received: 27.05.2020; **Accepted:** 20.11.2020; **Published:** 29.12.2020

Access this article online

Quick Response Code:



Website:
www.ijrh.org

DOI:
10.4103/ijrh.ijrh_56_20

This is an open access journal, and articles are distributed under the terms of the Creative Commons Attribution-NonCommercial-ShareAlike 4.0 License, which allows others to remix, tweak, and build upon the work non-commercially, as long as appropriate credit is given and the new creations are licensed under the identical terms.

For reprints contact: WKHLRPMedknow_reprints@wolterskluwer.com

How to cite this article: Mahajan N, Mahajan A, Bhinda A, Salodiya S. Homoeopathic treatment of viral warts with *Calcarea phosphorica*. Indian J Res Homoeopathy 2020;14:279-86.

that requires long hours of case study by the homoeopath to find the correct personal remedy that aims to bring about positive results, which the therapy can produce in deep chronic diseases.^[9]

Hence, the search for an effective, safe, cost-effective and environmental-friendly medicine that is easy to apply continues.^[2]

Homoeopathic approach

Warts can be categorised under local maladies which signify those changes and ailments that appear on the external parts of the body and as mentioned in §189 and §193, local maladies cannot arise persist or even grow worse without some internal cause. So, for the treatment of these affections, an internal medicine should be selected on the basis of totality of symptoms.^[10]

CASE REPORT

A 4-year-old girl presented at the outpatient department at Central Research Institute of Homoeopathy, Jaipur, with multiple warts on the right side of the forehead and one on the right cheek for 8 months. The past history revealed that she was treated for warts on the face with laser treatment 9 months back, which gave her temporary relief for 1 month, but these warty growths reappeared.

There were 5–6 small warts, 2–5 mm of size on the right side of the forehead and 1 wart of 2 mm on the right cheek without any pain, itching or any other sensation for 8 months.

The patient had a history of fever 1 month ago for which she took allopathic treatment and recovered in 2 days. All milestones of the child were achieved on time, except late in learning to walk, but now the patient's walk was as per her age. She had been vaccinated on time with no adverse events. Pregnancy history of mother marked no significant event.

Local examination of the skin

- Location of warts – Right side of the forehead near the hairline and right cheek
- Number of warts – 5–6 warts on the right side of the forehead and 1 on the right cheek
- Pattern of distribution – On exposed area, in group on the right side of the forehead and isolated on the right cheek
- Characteristics of warts – Flat and smooth on the right side of the forehead and fleshy on the right cheek
- Shape of warts – Round and flat
- Surface of warts – Smooth
- Pain Non-specific
- Discharge – Absent
- Itching – Absent
- Other systemic examinations were normal.

The definitive diagnosis of viral warts was based on characteristic manifestations, morphology and distribution of lesions, following the guidelines of ICD-10, code B-07.

Homoeopathic generals

Mental generals

The patient was very restless, continuously moving and unable to sit at one place. She had violent anger and bites during anger. She was mostly dissatisfied if was to remain at home. She liked to travel and go somewhere all the time.

Physical generals

The appetite of child was increased as she took food frequently. She ate two chapattis per meal and after every half an hour, again asked for something to eat. She had desire for salty food as she preferred chips, *Bhujia*, *Kachori* (salty Indian snacks), etc.

Analysis of the case

After analysis and evaluation, the characteristic symptoms were used in constructing the totality of the case. “Restlessness, desires to travel, discontented, biting in anger and late in learning to walk” were important mental symptoms in this case. Excessive appetite and desire for salty food were physical generals. Small warts on the right side of the face were the particular symptoms in this case. Miasmatic evaluation for the presenting symptoms was done with the help of *The Chronic Diseases* by Dr. Samuel Hahnemann,^[11] which showed the predominance of Sycotic Miasm.

The selection of remedy was based on repertorisation of the case using complete repertory, version 10.0 of RADAR software [computer program]. Version 10.0. Belgium. Archibel. 2009.^[12] The repertorisation chart is shown in Figure 1 where the top five medicines were *Calcarea phosphorica* 22/8, *Calcarea carbonica* 20/8, *Causticum* 18/8, *Sulphur* 16/7 and *Carcinosin* 11/7.

On the basis of repertorial analysis and with the consultation of Boericke's *Materia Medica*,^[13] *Calc. phos.* was selected as the first prescription, as discontentment and desire to travel was very marked in the patient, as also in *Cal. phos.* in comparison to *Cal. Carb.* and *Caust.* (24 October 2019) [Table 1]. After prescribing a single dose of *Cal. phos.* 200, good improvement was seen. Multiple warts on the right

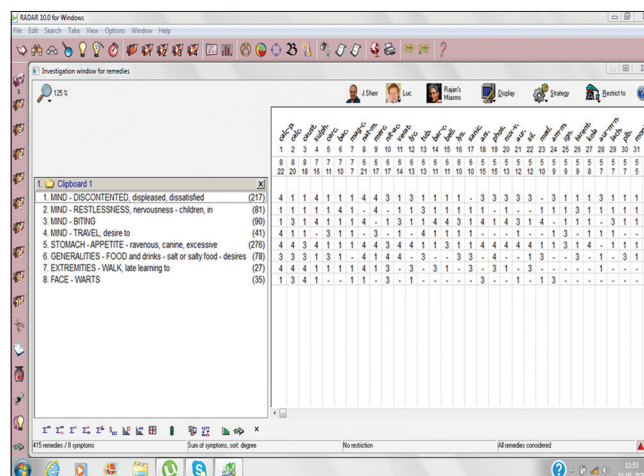


Figure 1: Repertory sheet showing repertorisation of the case

side of the forehead reduced in size and pedunculated wart on the right side of cheek slightly detached. On further visit on 20 November 2019, only placebo was prescribed, and rest of the warts fell off with no new warts or relapse till May 2020.

DISCUSSION

Because warts is a one-sided disease,^[10] efforts should be made to form the totality of symptoms based on characteristic mental, physical and particular symptoms of the patient.

Here, *Cal. phos.* was prescribed in 200 potency as per the totality of symptoms. Although it is not mentioned under the rubric Face – Warts in Kent’s Repertory^[14] and Synthesis Repertory,^[15] it is found in the fourth grade in Complete Repertory.^[16] The patient responded within 2 weeks of the treatment with complete remission of warts in 3 weeks which had persisted for 8 months. Previously, the patient had undergone laser treatment, but the warts relapsed after 1 month, but no recurrence was reported after homoeopathic treatment as per the last telephonic review in May 2020. In several cases, warts show spontaneous remission within 1 year,^[17] but many

Table 1: Timeline including follow-up

Date	Signs and symptoms	Prescription medicine with potency and dose
24 October 2019	Multiple small warts on the right side of the forehead and 1 line pedunculated wart on the right cheek [Figures 2 and 3] Number of warts – right cheek – 1, right side of the forehead – 5 to 6 small warts	<i>Calcarea phosphorica</i> 200/single dose Placebo 30/tds 7 days
05 November 2019	Multiple small warts on the right side of the forehead are slightly reduced in size and one pedunculated wart on the right cheek was slightly detached from the peduncle with a visible blood clot Number of warts – right cheek – 1, right side of the forehead – 5 to 6 small warts [Figures 4 and 5]	Placebo 30/tds /14 days
20 November 2019	No warts seen and appetite normal [Figures 6 and 7]	Placebo 30/tds/7 days

Table 2: Monarch inventory (improved version of the modified Naranjo criteria for Homoeopathy)^[18]

Domains	Yes	No	Not sure or N/A	Score for successfully treated case	Justification
Was there an improvement in the main symptom or condition for which the homoeopathic medicine was prescribed?	+2	-1	0	2	Warts were the main complaint which disappeared after treatment and did not reappear till date
Did the clinical improvement occur within a plausible timeframe relative to the medicine intake?	+1	-2	0	1	The complaint was persisting for 8 months but resolved within 20 days after medicine
Was there a homoeopathic aggravation of symptoms?	+1	0	0	0	Not observed
Did the effect encompass more than the main symptom or condition (i.e., were other symptoms, not related to the main presenting complaint, improved or changed)?	+1	0	0	1	Appetite which was ravenous earlier became normal after treatment
Did overall well-being improve? (suggest using a validated scale or mention about changes in physical, emotional, and behavioural elements)	+1	0	0	1	Overall well-being improved as patient did not fall ill during and after treatment
Direction of cure: Did some symptoms improve in the opposite order of the development of symptoms of the disease?	+1	0	0	0	Not observed
Direction of cure: Did at least one of the following aspects apply to the order of improvement in symptoms From organs of more importance to those of less importance? From deeper to more superficial aspects of the individual? From the top downward?	+1	0	0	0	Not observed
Did ‘old symptoms’ (defined as nonseasonal and noncyclical symptoms that were previously thought to have resolved) reappear temporarily during the course of improvement?	+1	0	0	0	Not observed
Are there alternative causes (i.e. other than the medicine) that – with a high probability –could have produced the improvement? (consider known course of disease, other forms of treatment, and other clinically relevant interventions)	-3	+1	0	1	As the patient had undertaken laser therapy, the warts recurred within a month, but after homoeopathic intervention, warts disappeared and did not recur till date
Was the health improvement confirmed by any objective evidence? (e.g., investigations, clinical examination, etc.)	+2	0	0	1	Yes by photographs (before and after)
Did repeat dosing, if conducted, create similar clinical improvement?	+1	0	0	0	Not observed

Total score: 7. N/A: Not available



Figure 2: Number of warts – Right side of the forehead 5–6 small warts and 1 wart on the right side of the cheek on first visit on 24 October 2019



Figure 3: Number of warts – Right side of the forehead 5–6 small warts and 1 wart on the right side of the cheek on first visit on 24 October 2019. Side view

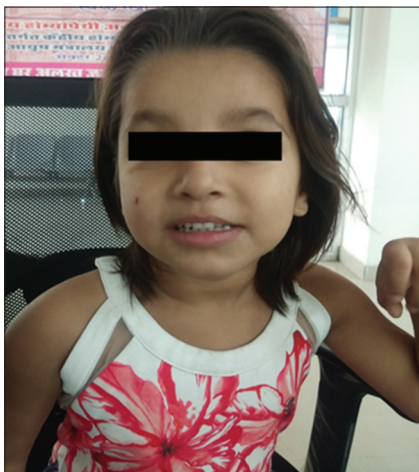

Figure 4: Inflammation of wart on the cheek with reduction in the number of warts on the forehead on second visit on 5 November 2019

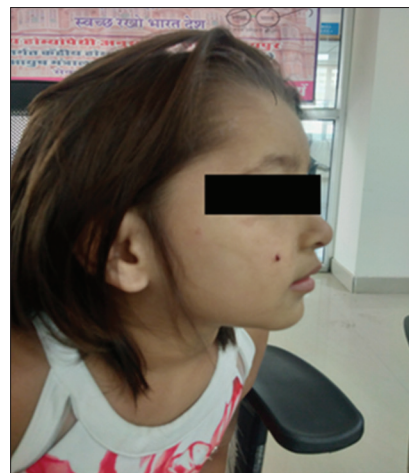

Figure 5: Inflammation of wart on the cheek with reduction in the number of warts on forehead on second visit on 5 November 2019

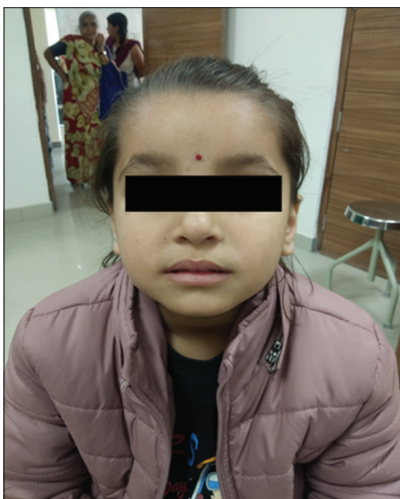

Figure 6: Warts disappeared from the forehead and cheek on 3rd visit on 20 November 2019

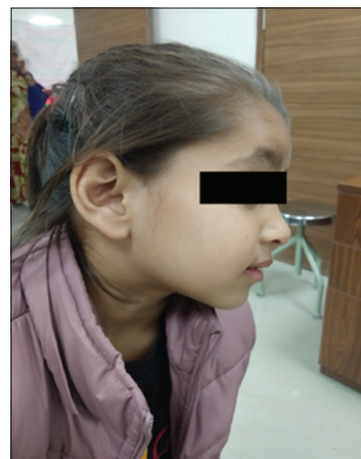

Figure 7: Warts disappeared from the forehead and cheek on 3rd visit on 20 November 2019

are resistant to treatment or recur after treatment, as in this case. The warts recurred after laser therapy. The case was assessed for the likelihood of causality between the homoeopathic intervention and outcome as per Modified Naranjo criteria for Homoeopathy,^[18] and the total score of outcome was 7 [Table 2]. This suggests the causal relationship between homoeopathic medicine prescribed and cure in this case.

Thuja, *Ruta*, *Cal. Carb.*, *Dulcamara*, *Nitric acid* and *Caust.* are the commonly used medicines for the treatment of warts^[19] and have shown results in randomised controlled trials (RCT).^[20] However, when the patient jumps away out of the ordinary group of remedies, it is that the treating physician has to go outside of the beaten track and find another remedy that also corresponds to the nature of disease.^[21]

Interestingly, no apparent difference between the effects of homoeopathic therapy and placebo in children with common warts was found in an RCT.^[22]

Although RCTs are the gold standard for evaluating the efficacy of treatment in conventional medicine, they may not be suitable for Homoeopathy at large due to the individualised nature of treatment. Moreover, these have a good internal validity, but external validity may be compromised as real-time settings are usually ignored. Therefore, due importance may be given to case reports in the field of Homoeopathy as each case is a new case with characteristic symptoms and may require any medicine from the armamentarium of homoeopathic *Materia Medica* and not only the specified medicines mentioned under the therapeutics for a particular disease.

The ultimate wart treatment would resolve all, or a great percentage, of warts, be painless, create no scarring, offer HPV immunity for a lifetime and be available to all patients,^[23] as observed in this case treated with Homoeopathy in a painless way, without scarring.

CONCLUSION

Individualised, constitutional homoeopathic medicine plays a very important role in treating patients. This is a single case report to serve as an evident role of *Calc. phos.* as constitutional medicine, which otherwise is not commonly used for the treatment of warts. Further study may be considered in evaluating the role of this remedy in viral warts. Therefore, further prospective study of *Calc. phos.* is suggested in the cases of aforementioned viral warts to confirm its scientific validation.

Declaration of patient consent

The authors certify that they have obtained written consent, duly signed by the patient's maternal grandmother (as patient is minor) and she has even given consent for the photographs and other clinical information to be reported in the journal. The maternal grandmother of the patient was made to understand that the name and initials of the patient will not be published and due efforts will be made to conceal the identity of the child.

Financial support and sponsorship

Nil.

Conflicts of interest

None declared.

REFERENCES

1. Kwok CS, Gibbs S, Bennett C, Holland R, Abbott R. Topical treatments for cutaneous warts. *Cochrane Database Syst Rev* 2012;12:CD001781.
2. Shahid SK. Recent patents in anti-wart treatment. *Pharm PatAnal* 2020;9:53-62. Available from: <https://www.ncbi.nlm.nih.gov/pubmed/32314659>. [Last accessed on 2020 Apr 21].
3. Al Aboud AM, Nigam PK. *Wart (Plantar, Verruca Vulgaris, Verrucae)*. Treasure Island (FL): Stat Pearls Publishing; 2020. Available from: <https://www.ncbi.nlm.nih.gov/books/NBK431047/>. [Last accessed on 2020 Apr 15].
4. Zandi S, Ahmad Zadeh R, Yousefi S, Gharibi F. Promising new wart treatment: A randomized, placebo-controlled, clinical trial. *Iran Red Crescent Med J* 2016;18:e19650. Available from: <https://www.ncbi.nlm.nih.gov/pubmed/27761268>. [Last accessed on 2020 Apr 15].
5. Sterling JC, Gibbs S, Haque Hussain SS, Mohd Mustapa MF, Handfield-Jones SE. British Association of Dermatologists' guidelines for the management of cutaneous warts 2014. *Br J Dermatol* 2014;171:696-712. Available from: <https://onlinelibrary.wiley.com/doi/10.1111/bjd.13310>. [Last accessed on 2020 Apr 23].
6. Surabhi S, Vineet R, Garg Vijay K. Immunomodulators in warts: Unexplored or ineffective. *IADVL* 2015;60:118-29. Available from: <http://www.e-ijd.org/article.asp?issn=0019-5154;year=2015;volume=60;issue=2;spage=118;epage=129;aulast=Sinha>. [Last accessed on 2020 Apr 28].
7. Friedman PC, Fridman G, Fridman A. Using cold plasma to treat warts in children: A case series. *Pediatr Dermatol* 2020;37:706-9. Available from: <https://www.ncbi.nlm.nih.gov/pubmed/32323887>. [Last accessed on 2020 Apr 23].
8. Dasher DA, Burkhart CN, Morrell DS. Immunotherapy for childhood warts. *Pediatr Ann* 2009;38:373-9. Available from: <https://www.ncbi.nlm.nih.gov/pubmed/19685657>. [Last accessed on 2020 Apr 29].
9. Vithoulkas G. Can Homeopathy, a Particularly Mild Therapeutic Approach, Survive and Grow in a World of Violence? *Homeopathy* 2020;109:179-81. Available from: <https://www.ncbi.nlm.nih.gov/pubmed/32408371>. [Last accessed on 2020 May 05].
10. Hahnemann S. *Organon of Medicine*. 6th ed. New Delhi: B Jain Publishers; 2002. p. 227-8.
11. Hahnemann S. *The Chronic Disease, their Peculiar Nature and their Homoeopathic Cure*, Translated from Second Enlarged German Edition of 1835, by Prof Louis H Tafel with Annotations by Richard Hughes, edited by Pemberton Dudley. 13th Impression. New Delhi: B Jain Publishers; 1998.
12. Schroyens F. *Radar 10 Homoeopathic Repertory Software*. CDROM. Available from: <http://www.archibel.com/radar10.html>. [Last accessed on 2020 May 21].
13. Boericke W. *Pocket Manual of Homoeopathic Materia Medica and Repertory*. 9th Reprint ed. New Delhi: B Jain Publishers; 2007. p. 152-3.
14. Kent JT. *Repertory of the Homoeopathic Materia Medica*. Enr. Indian ed. New Delhi: B Jain Publishers (P) Ltd; 2006.
15. Schroyens F. *Synthesis: Repertorium Homoeopathicum Syntheticum*. 9.1th ed. New Delhi: B Jain Publishers (P) Ltd.; 2014.
16. Zandvoort R. *The complete Repertory*. 1st ed. Leidschendam: IRHIS Publishers; 1996.
17. Bruggink SC, Eekhof JA, Egberts PF, van Blijswijk SC, Assendelft WJ, Gussekloo J. Natural course of cutaneous warts among primary schoolchildren: A prospective cohort study. *Ann Fam Med* 2013;11:437-41. Available from: <https://www.ncbi.nlm.nih.gov/pubmed/24019275>. [Last accessed on 2020 Apr 29].
18. Lamba CD, Gupta VK, van Haselen R, Rutten L, Mahajan N, Molla AM, *et al.* Evaluation of the modified naranjo criteria for assessing causal attribution of clinical outcome to homeopathic intervention as presented in case reports. *Homeopathy* 2020;109:191-7. Available from: <https://www.>

- ncbi.nlm.nih.gov/pubmed/32215892. [Last accessed on 2020 May 05].
19. Oza PM. Homeopathic management of warts. *Indian J Drugs Dermatol* 2016;2:45-7. Available from: <http://www.ijdd.in/text.asp?2016/2/1/45/184085>. [Last accessed on 2020 Apr 10].
 20. Manchanda RK, Mehan N, Bahl R, Warts AR. *Clinical Studies and Publications*. Directorate of AYUSH, Homoeopathic Wing; 2020. Available from: <http://homeo.delhigovt.nic.in/wps/wcm/connect/doi-homeopathy/Homeopathy/Home/Clinical+Studies+And+Publications/Warts>. [Last accessed on 2020 May 12].
 21. Kent JT. *Lectures on Homoeopathic Philosophy with Classroom Notes and Word Index*. 7th ed. New Delhi: B Jain Publishers; 2007.
 22. Kainz JT, Kozel G, Haidvogel M, Smolle J. Homoeopathic versus placebo therapy of children with warts on the hands: A randomized, double-blind clinical trial. *Dermatology* 1996;193:318-20. Available from: <https://bmcmedresmethodol.biomedcentral.com/articles/10.1186/1471-2288-12-49>. [Last accessed on 2020 May 12].
 23. Kuykendall-Ivy TD, Johnson SM. Evidence-based review of management of nongenital cutaneous warts. *Cutis* 2003;71:213-22. Available from: <https://pubmed.ncbi.nlm.nih.gov/12661750/>. [Last accessed on 2020 May 12].

कैल्केरिया फॉस्फोरिका से वायरल मस्से (वार्ट्स) का होम्योपैथिक उपचार: एक केस रिपोर्ट

परिचय: वायरल मस्से (वार्ट्स) मानव पैपिलोमा वायरस द्वारा होने वाला सामान्य कुटेनियस संक्रमण हैं। मस्सों का उपचार कई उपलब्ध पद्धतियों द्वारा किया जाता है, जैसे कि क्रायोथेरापी, कैमिकल कॉटेराइजेशन, क्युरेटेज, इलेक्ट्रोडेसिकेशन और लेजर द्वारा समाप्ति। हालाँकि, इनमें से अधिकतर उपचार क्षत के चिन्ह छोड़ सकते हैं। इनके कारण उपचार स्थल पर प्रतिक्रिया और पुनरावृत्ति भी होती है। होम्योपैथिक साहित्य में मस्सों के उपचार के लिए बहुत सारी औषधियों का उल्लेख है। **सारांश:** एक 4 वर्ष की लड़की को लेजर उपचार के एक महीने पश्चात् चेहरे पर कई मस्सों की पुनरावृत्ति के साथ उपचार के लिए प्रस्तुत हुई। इस बार, मस्से उसके माथे के दाहिनी ओर और एक मस्सा दाँये गाल पर स्थित था और वे 8 महीनों से कायम थे। इस रोगी को व्यक्तिगत होम्योपैथी उपचार से अच्छा लाभ मिला, अर्थात् कैल्केरिया फॉस्फोरिका 200 की एकमात्र खुराक से बिना पुनरावृत्ति के एक महीने के अंदर सम्पूर्ण आरोग्य प्राप्त हुआ। भले ही, इस औषधि का उल्लेख 'कम्प्लीट रेपर्टरी' में 'चेहरे के मस्से' शीर्ष से चौथे श्रेणी में हुआ है और इसका उपयोग साधारणतया मस्सों के केसों में नहीं किया जाता, परन्तु इसका प्रभाव लाभकारी पाया गया। इसलिए, यह केस विशेषीकृत सामान्य लक्षणों पर आधारित व्यक्तिगत होम्योपैथी उपचार के महत्त्व पर बल देता है।

Traitement homéopathique des verrues virales avec *Calcarea phosphorica*: un rapport de cas

Introduction: Les verrues virales sont l'infection cutanée la plus courante causée par le papillomavirus humain. Les verrues peuvent être traitées par de nombreuses modalités disponibles telles que la cryothérapie, la cautérisation chimique, le curetage, l'électrocoagulation et l'élimination au laser. Cependant, la plupart de ces thérapies peuvent provoquer des cicatrices. Ils provoquent également des réactions et des récurrences au site d'application. La littérature homéopathique a une pléthore de médicaments pour le traitement des verrues. **Résumé du cas:** Une fillette de 4 ans s'est présentée avec la réapparition de plusieurs verrues sur le visage après un mois de traitement au laser. Cette fois, les verrues étaient sur le côté droit du front et une sur la joue droite et ont persisté pendant 8 mois. Le patient a bien répondu au traitement homéopathique individualisé, c'est-à-dire *Calcarea phosphorica* 200 en une seule dose avec une guérison complète en 1 mois sans rechute ultérieure. Même si le médicament est mentionné en quatrième année dans la rubrique «Visage - Verrues» du Répertoire complet et n'est pas couramment utilisé dans les cas de verrues, il a agi de manière bénéfique. Par conséquent, ce cas souligne l'importance d'un traitement homéopathique individualisé basé sur des symptômes généraux caractéristiques.

Tratamiento homeopático de las verrugas virales con fosfáica de *Calcárea*: Un informe de caso

Introducción: Las verrugas virales son la infección cutánea más común causada por el virus del papiloma humano. Las verrugas pueden ser tratadas por muchas modalidades disponibles como crioterapia, cauterización química, curetaje, electrodesicación y eliminación de láser. Sin embargo, la mayoría de estas terapias pueden causar cicatrización. También causan reacciones en el lugar de aplicación y recurrencia. La literatura homeopática tiene una plétora de medicamentos para el tratamiento de las verrugas. **Resumen del caso:** Una niña de 4 años se presentó con reaparición de múltiples verrugas en la cara después de un mes de tratamiento con láser. Esta vez, las verrugas estaban en el lado derecho de la frente y una en la mejilla derecha y persistían durante 8 meses. El paciente respondió bien al tratamiento homeopático individualizado, es decir, *Calcarea phosphorica* 200 en una sola dosis con recuperación completa en 1 mes sin recaída posterior. Aunque el medicamento se menciona en el cuarto grado contra la rubrica 'cara - verrugas' en el Repertorio completo y no se utiliza comúnmente en los casos de verrugas, actuó de manera beneficiosa. Por lo tanto, este caso enfatiza la importancia del tratamiento homeopático individualizado basado en síntomas generales característicos.

Homöopathische Behandlung von Viralen Warzen mit *Calcarea phosphorica*: Ein Fallbericht

Einleitung: Virale Warzen sind die häufigsten kutanen Infektion verursacht durch das humane papillomavirus. Warzen können behandelt werden, indem Sie viele Modalitäten wie Kryotherapie, Chemische Verätzungen, Kürettage, electrodessication und laser-Entfernung. Allerdings werden die meisten dieser Therapien kann zu Narbenbildung. Sie verursachen auch Anwendung-Ort-Reaktion und Wiederholung. Die Homöopathische Literatur hat eine fülle von Medikamenten für die Behandlung von Warzen. **Zusammenfassung:** Ein 4-Jahr-altes Mädchen präsentiert mit Wiederauftreten des multiplen Warzen auf dem Gesicht nach einem Monat, laser-Behandlung. Diese Zeit, die Warzen wurden auf der rechten Seite der Stirn und einen auf der rechten Wange waren persistierenden für 8 Monate. Der patient reagierte gut auf individuelle Homöopathische Behandlung, D. H. *Calcarea phosphorica* 200 in einer einzigen Dosis mit vollständiger Erholung innerhalb von 1 Monat ohne weiteren Rückfall. Obwohl die Medizin ist bereits in der vierten Klasse gegen die Rubrik "Gesicht – Warzen" im Complete Repertory und ist nicht Häufig in den Fällen von Warzen, handelte es vorteilhaft. Deshalb ist dieser Fall unterstreicht die Bedeutung einer individualisierten homöopathischen Behandlung basiert auf dem Merkmal Allgemeine Symptome.

与卡尔卡雷磷的病毒疣的同源治疗：病例报告

介绍：病毒疣是人类乳头瘤病毒引起的最常见的皮肤感染。疣可以通过许多可用的方式治疗，如冷冻疗法，化学烧灼，刮除，电极干燥和激光去除。然而，大多数这些疗法可能会导致疤痕。它们还会导致应用现场反应和复发。顺势疗法文献有大量的治疗疣的药物。案例摘要：经过一个月的激光治疗，一名4岁女孩脸上再次出现多处疣。这一次，疣在额头的右侧，一个在右脸颊，并坚持了8个月。患者对个性化同病治疗反应良好，即磷石灰石200单剂量，在1个月内完全恢复，没有随后的复发。即使在四年级提到的药反对标题'脸疣'在完整的剧目，并不常用于疣的情况下，它采取行动有益。因此，这种情况下强调个性化的顺势疗法治疗基于特征性的一般症状的重要性。