

Homoeopathic treatment of hepatic haemangioma with ovarian cyst

Abhijit Chakma*¹, Manas Ranjan Sarangi²

¹Regional Research Institute for Homoeopathy, Agartala, Tripura, ²Central Council for Research in Homoeopathy, Ministry of Ayush, Government of India, New Delhi, India

Abstract

Introduction: This is a case of multimorbidity in a 35-year-old patient suffering from hepatic hemangioma with ovarian cyst. There was hepatomegaly with multiple well-defined homogeneously echogenic nodular lesion (largest nodule of size 1.64 X 1.64 cm) in both lobes of liver suggestive of haemangioma. The right ovarian cyst was 2.26 X 1.25 cm in size with pelvic congestion syndrome. **Case Summary:** This case was treated with individualized homoeopathy for a period of 5 months at the outpatient department (OPD) of Regional Research Institute for Homoeopathy, Agartala. Homoeopathic medicine *Pulsatilla*, was given to the patient on the basis of individualistic approach. The patient not only improved in her presenting complaints but also there was change in diagnostic parameters. Post treatment outcome corroborated with follow up laboratory investigations that showed significant changes. Ultrasonography revealed no obvious abnormality after homoeopathic treatment with improvement in pelvic congestion syndrome. This case report suggests that a correctly chosen homoeopathic medicine can be beneficial even in complicated and unusual cases.

Keywords: Hepatic haemangioma, Homoeopathy, Individualisation, Outcome in Relation to Impact on Daily Living, Ovarian cyst, *Pulsatilla*

INTRODUCTION

Hepatic haemangioma (HH) is the most common benign liver tumour and is frequently detected incidentally during imaging examinations,^[1,2] consisting of clusters of blood-filled cavities, lined by endothelial cells, fed by the hepatic artery. Typical haemangiomas, the so-called capillary haemangiomas, range from a few mm to 3 cm, do not increase in size over time and therefore are unlikely to generate future symptomatology. Small (0 mm–3 cm) and medium (3 cm–10 cm) haemangiomas are well-defined lesions and may not require active treatment if there are no troublesome complaints. However, the so-called giant liver haemangiomas, of up to 10 cm (most commonly) and even 20+ cm in size (according to occasional reports) can and usually will develop symptoms and complications that require prompt surgical intervention or other kind of therapy.^[3] HH generally presents with upper abdominal pain. The cause of HH is not known, it may be congenitally determined and there are researchers who reported cases of HH running in families, suggesting a possible genetic connection, others

with mesenchymal origins.^[3] There are no data in literature to advocate for malignant transformation. Prime management for HH is supervision through imaging methods at every 6 months or annually. According to the existing data, there is no known pharmacological therapy which is able to reduce the size of HH. Surgery is indicated if there is rapid growth in size or pain despite analgesics or both.^[4] In Homoeopathy, there are no scientific papers found in terms of successful treatment outcome in HH. The positive outcome of this case shall add to an evidence of the usefulness of Homoeopathy in treating such a disease.

Ovarian cysts (OCs) are sacs filled with fluid which are present in or on the ovaries and are common during

***Address for correspondence:** Dr. Abhijit Chakma, Regional Research Institute for Homoeopathy, (Under Central Council for Research in Homoeopathy), Joy Krishna Kobra Para Road, Khumulwng, Jirania, Agartala - 799 045, Tripura, India.
E-mail: dr.abhijit24@gmail.com

Received: 09.04.2019; **Accepted:** 22.11.2019; **Published:** 27.12.2019.

This is an open access journal, and articles are distributed under the terms of the Creative Commons Attribution-NonCommercial-ShareAlike 4.0 License, which allows others to remix, tweak, and build upon the work non-commercially, as long as appropriate credit is given and the new creations are licensed under the identical terms.

For reprints contact: reprints@medknow.com

How to cite this article: Chakma A, Sarangi MR. Homoeopathic treatment of hepatic haemangioma with ovarian cyst. *Indian J Res Homoeopathy* 2019;13:244-50.

Access this article online

Quick Response Code:



Website:
www.ijrh.org

DOI:
10.4103/ijrh.ijrh_28_19

the reproductive period.^[5-7] Patients with OC may have symptoms of irregular or non-existent periods, acne, weight gain, pelvic pain, high blood pressure, lower back pain, breast tenderness, abdominal pressure, dysmenorrhoea, dyspareunia and nausea.^[8] The two most common types of cysts are: (i) Follicle cysts – In a normal menstrual cycle, an ovary releases an egg each month and grows inside a tiny sac called a follicle. When the egg matures, the follicle breaks open to release the egg. Follicle cysts form when the follicle does not break open to release the egg. This causes the follicle to continue growing into a cyst; (ii) Corpus luteum cysts – Once the follicle breaks open and releases the egg, the empty follicle sac shrinks into a mass of cells called corpus luteum. Corpus luteum cysts form if the sac does not shrink. Instead, the sac reseals itself after the egg is released, filling up fluid inside. Most corpus luteum cysts go away after a few weeks. They may bleed or twist the ovary and cause pain.^[5-7,9] When managing giant benign OCs, laparoscopy is considered a safe and minimally invasive surgical procedure. Ultrasound-guided drainage with excision of giant OCs is a safe and appropriate modality of treatment.^[10] Various articles are found on effectiveness of homoeopathic medicines in ovarian cystic diseases, but most of them are mainly case reports.^[11-15] This case report enlightens the readers about Homoeopathy as a treatment option for treating haemangioma with OC.

CASE REPORT

A female patient aged 35 years who was under supervision of a gynaecologist for some time came to the outpatient department of Regional Research Institute for Homoeopathy, Agartala, with complaints of dull-aching pain in the lower

back (lumbosacral region) and in the lower abdomen (both occurs on and off but aggravated during menses; >from warm application). There was pain in the right upper quadrant of abdomen (no specific modalities) with scanty menses for the last 11 months. Investigations revealed a cyst in the right ovary with HH and anaemia. With no significant change in complaints with 5–6 months of allopathic treatment, she switched over to Homoeopathy. On further enquiry, it was elucidated that all these complaints had started gradually, but pain in the right hypochondrium was worsening for the last 1½ months.

The patient had a past history of cholecystectomy 4 years ago with no known post-operative complications and family history, except for the fact that her mother has been suffering from rheumatic problems. The patient was of moderate built, fair complexion, homemaker by profession and was social and living happily with her spouse and one son. The mental generals reflected a very mild, gentle, co-operative nature, and loved company with desire for spices and dry fish. She had intolerance to meat (pork) which caused loose, mucoid stool. She was thirstless and thermally chilly (felt excessive chill in the winter season). Menses were regular but scanty and clotted for the last 2–3 years. Local and systemic examination revealed mild pallor with no other obvious abnormality.

Diagnostic focus and assessment

Investigations such as blood (routine), blood sugar (fasting and post-prandial), liver function test, ultrasonography (USG – whole abdomen and transvaginal), cervical Pap smear, quantiferon TB Gold, urine (routine and

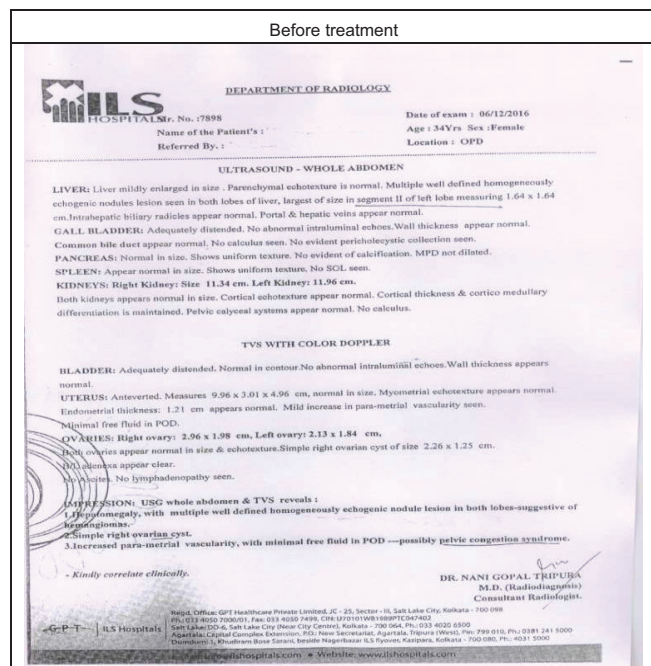


Figure 1: Ultrasound after treatment

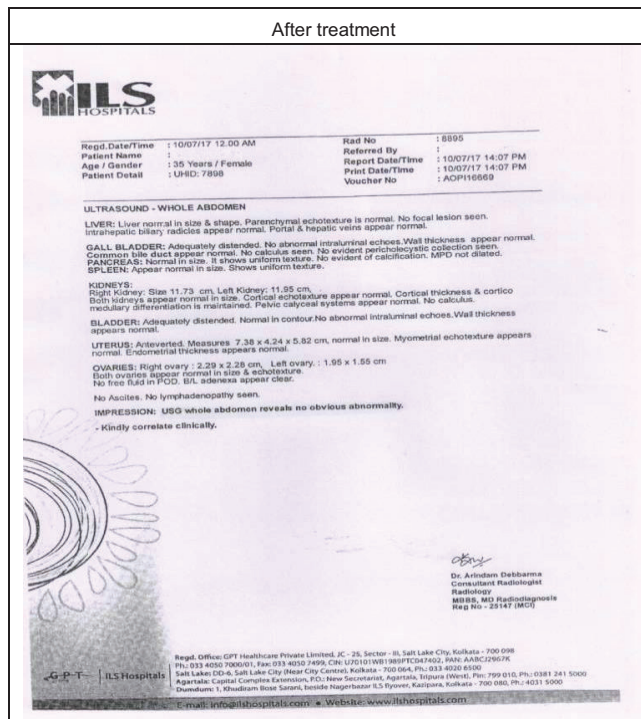


Figure 2: Ultrasound after treatment

Table 1: Miasmatic analysis

Rubric	Chapter	Miasm	Page number
Mildness	Mind	Psora	62
Company, desire for, alone, while aggravation	Mind	Psora	11
Heat, vital lack of	Generalities	Psora	1242
Thirstless	Stomach	Psora	477
Food, pork, aggravation	Generalities	Not classified	1240
Menses, scanty	Genitalia, female	Psora, Lt. Psora	654
Menses, clotted	Genitalia, female	Psora, sycosis	652
Anaemia	Generalities	Sycosis	1228
Pain, aching, dull, hypochondria, right	Abdomen	Psora	505
Pain, aching, dull, hypogastrium, menses during	Abdomen	Psora	507
Pain, hypogastrium, warmth, amel.	Abdomen	Psora	508
Pain, aching, lumbosacral region	Back	Psora	827
Tumours, ovaries, cysts	Genitalia, female	Psora, sycosis	670

culture) and Vitamin-D were carried out. USG (whole abdomen and transvaginal) and blood (routine) suggested hepatomegaly with multiple well-defined homogeneously echogenic nodule lesions in both the lobes – suggestive of haemangioma (larger one is 1.64 cm × 1.64 cm) and right OC (2.26 cm × 1.25 cm) with pelvic congestion syndrome and low haemoglobin (9.80 g%). All other reports were normal. Post-treatment outcome corroborated with follow-up laboratory investigations with significant changes. USG (whole abdomen) revealed no obvious abnormality after 3–4 months of continuous homoeopathic treatment with improvement in pelvic congestion syndrome and haemoglobin level [Figures 1-4].

Therapeutic intervention

After analysing the symptoms of the case, the characteristic generals and particular symptoms were considered for framing the totality. Among important mental generals were prominent mildness, gentle attitude, liking for company and feeling bad when alone; decreased thirst, chilly patient, intolerance to meat (pork), desire for spices, scanty and clotted menstrual flow are among important physical generals, and particular symptoms such as pain in the right hypochondrium and low back pain were considered for final selection of the medicine. Miasmatic evaluation of all the presenting symptoms was done with the help of Repertory of miasms,^[16] which showed the predominance of Psora, as shown in Table 1. Repertorial analysis using Synthesis Repertory from the Radar software was done considering the above symptomatology.^[17] The repertorisation chart is presented at Figure 5. The first six medicines with maximum score (based on mental and physical generals, important particular symptoms) in the descending order are *Lycopodium*, *Pulsatilla*, *Arsenic*, *Belladonna*, *Sepia* and *Natrum mur*. After going through textbooks of Materia Medica,^[18,19] medicines such as *Lycopodium* – a right sided, hot, male-dominant drug does not cover the eliminating symptoms; *Arsenicum album* – although chilly patient but mental, restlessness, anxiety and thirstlessness are lacking; *Belladonna* – an acute remedy with opposite mentality to *Pulsatilla* and *Sepia* – a

commonly used drug for climacteric complaints, especially heat flushes, irregular menses with relaxed pelvic organs, resulting in uterine prolapse were considered. The mild nature observed while talking, behaviour of the patient along with thirstlessness and aggravation from pork were very prominent in the patient and thus considered as eliminating rubrics: *Pulsatilla* seemed to be the most suitable remedy in this case and prescribed in the 30th potency on the 1st visit considering mildness, feels bad when alone; less thirst, intolerance to meat (pork), anaemia, scanty and clotted menstrual flow were among other important physical generals. Particular symptoms such as pain in the hypogastrium during menses and cyst in the ovary were also considered.

Prescription

The medicine was of SBL Pvt. Ltd Pharmaceutical Company and procured from local market.

Improvement assessment

The timeline of the case including the 1st visit and subsequent follow-up is given in Table 2. Time-to-time assessment of complaints was done with the help of Outcome in Relation to Impact on Daily Living (ORIDL)^[20] instrument, and after 3–4 months of treatment, clinical improvement corroborated with laboratory investigations [Table 3]. Before and after treatment, key investigations are given in Figure 1.

DISCUSSION

No scholarly articles were found in PubMed, Researchgate, Google Scholar, ISeek, CORE-Hom and AYUSH Research Portal (search made during December 2018 to March 2019) regarding works carried out till date on scope of Homoeopathy in HH. However, a few case reports on Ovarian Cyst treated with Homeopathy have been published.^[11-15] but mostly are of case reports. This is a rare case successfully treated with homoeopathic medicines. In this case individualistic approach, attitude and manner of conversation of patient, her mental condition temperament, characteristic physical

Table 2: Follow-up and outcomes

Date of 1 st visit and follow-ups	Complaints/description	Medicine prescribed	ORIDL score (outcome)
1 st visit-10 February 2017	LMP was on 2 February 2017 (scanty, clotted flow lasted for 2 days); had pain in lower abdomen with mild low back pain during menses	<i>Pulsatilla</i> 30C; 6 doses, BD followed by placebo for 7 days	To be assessed in subsequent follow-ups
2 nd visit-27 February 2017	No significant change in complaints of pain in right side of abdomen and mild-to-moderate low back pain	<i>Pulsatilla</i> 200C; 4 doses, BD followed by placebo for 7 days	Pain in the right hypochondrium=0 Low back pain=0 Overall well-being=0
3 rd visit-13 March 2017	No pain in right hypochondria for the last 3-4 days. Back pain improved. All generals are almost same. No new complaints	Placebo given for 7 days	Pain in the right hypochondrium = +3 Low back pain = +2 Overall well-being = +2
4 th visit-17 March 2017	Old complaints are better. New complaint of dull, aching pain in right thigh for 1 day following blunt trauma with bluish discoloration. LMP-3 March 2017 but pain in lower abdomen less than last menstrual cycle with no back pain. Flow scanty, clotted and lasted for 3 days	<i>Arnica</i> 30C; 9 doses, TDS for 3 days	Pain in the right hypochondrium = +3 Low back pain = +3 Pain in lower abdomen = +2 Scanty menses=0 Clotted menstrual flow=0 Overall well-being = +2
5 th visit-24 March 2017	Bluish discoloration persisting but pain much improved. No appearance of old complaints	Again <i>Arnica</i> 30C; 6 doses, BD repeated	Pain in the right hypochondrium = +3 Low back pain = +3 Pain in right thigh = +3 Overall wellbeing = +2
6 th visit-4 April 2017	Both pain and bluish discoloration disappeared. LMP-1 April 2017 lasted for 3 days; flow mild improved but clotted; no pain in abdomen. On and off pain in the back and right hypochondrium	<i>Pulsatilla</i> 200C; 4 doses, OD followed by placebo for 15 days	Pain in the right hypochondrium = +2 Low back pain = +2 Pain in right thigh = +4 Pain in lower abdomen = +3 Scanty menses = +1 Clotted menstrual flow=0 Overall well-being = +2
7 th visit-24 April 2017	Pain in the back and right hypochondrium was improving but aggravated for the last 3 days. General weakness, drowsiness for 2-3 days. Patient had pork 2 days back but no such problem of loose, mucoid stool observed this time	<i>Pulsatilla</i> 1000C; 2 doses, OD followed by placebo for 20 days	Pain in the right hypochondrium = -1 Low back pain = -2 Pain in right thigh = +4 Loose, mucoid stools after pork = +3 Overall well-being = -1
8 th visit-18 May 2017	LMP-2 May 2017 flow moderate with no pain in lower abdomen and first time no clot observed. Low back pain completely disappeared within 5 days of intake of last medicine but the pain in the right hypochondrium still continuing on and off	<i>Pulsatilla</i> 1000C; 1 dose followed by placebo for 15 days	Pain in the right hypochondrium = +2 Low back pain = +3 Pain in lower abdomen = +3 Scanty menses = +2 Clotted menstrual flow = +3 Pain in right thigh = +4 Overall well-being = +3
9 th visit-12 June 2017	Patient is doing well; no old symptoms or new complaints. LMP-1 June 2017 where flow was moderate, no clots and lasted for 4 days. She was advised for USG (W/A) and blood (R/E)	Placebo for 15 days	Pain in the right hypochondrium = +3 Low back pain = +3 Pain in lower abdomen = +4 Scanty menses = +3 Clotted menstrual flow = +3 Pain in right thigh = +4 Overall well-being = +4
10 th visit-12 July 2017	Patient doing well and reporting after 1 month with USG report which showed normal study and there was also increase in Hb level but below normal. She was advised to take meals regularly with iron rich food items. Patient did not turn up for any further visits almost for the last 1½ years. She is still chilly, mildness and other mentals are same as earlier but pork aggravation, presenting complaints and menstruation-related complaints are much improved	Placebo given for 15 days	Pain in the right hypochondrium = +4 Low back pain = +4 Pain in lower abdomen = +4 Pain in right thigh = +4 Overall well-being = +4

OD: Once daily; BD: Twice daily; TDS: Thrice daily; OPD: Outpatient department; USG: Ultrasonography; LMP: Last menstrual period; W/A: Whole abdomen; R/E: Routine examination; ORIDL: Outcome in Relation to Impact on Daily Living; Hb: Haemoglobin

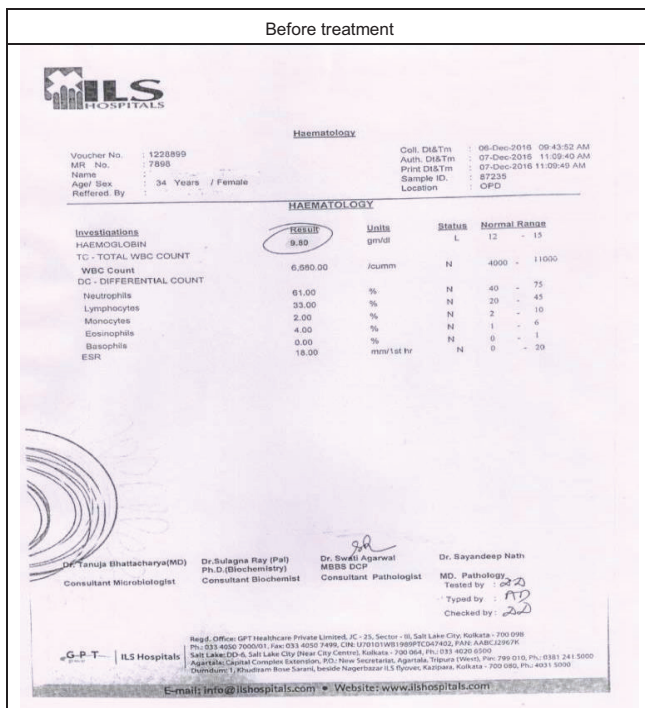


Figure 3: Blood test report before treatment

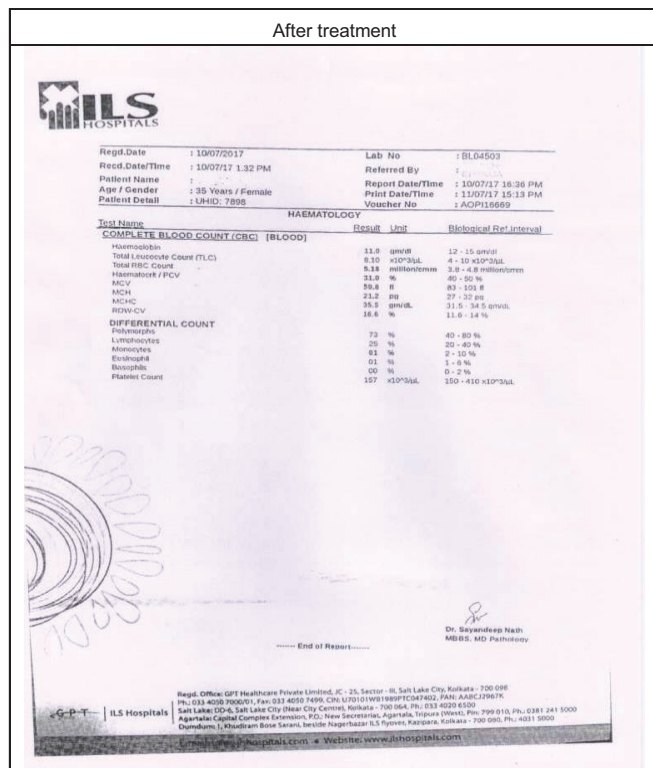


Figure 4: Blood test report after treatment

Table 3: Outcome in relation to impact on daily living score

Score	Condition
+ 4	Cured/Back to normal
+ 3	Major improvement
+ 2	Moderate improvement, affecting daily living
+ 1	Slight improvement, no effect on daily living
0	No change/Unsure
- 1	Slight deterioration, no effect on daily living
- 2	Moderate deterioration, affecting daily living
- 3	Major deterioration
- 4	Disastrous deterioration

1. The main complaint for which you came for treatment

2. Your overall well-being

generals and particulars were taken into consideration. The ORIDL instrument^[20] (formerly referred to as the Glasgow Homoeopathic Hospital Outcomes Scale) has been used in this case to measure patient's views of the outcome of their care. The scale allows the person to assess their outcome by relating this to impact on their daily life.

Although HH and OCs have chances of self-regression, we cannot wait for a considerable period to let them resolve spontaneously. There are reports where probability for self-regression of HH or OC is mentioned ranging from a few weeks to months, but none of them has given tangible data or mentioned about any observational studies to assert that HH and OCs are self-regressing. There is no conclusive scientific evidence that these abnormal growths may turn into malignancy; however, to avoid unseen complications,

sometimes, surgical removal is suggested.^[4,10] At this juncture, Homoeopathy may have a role to play as it is safe to use, it may help to annihilate the abnormal growth and restore the health. The beauty and core concept of Homoeopathy is individualisation, i.e., treat the patient not the disease. With individualistic approach, this patient was benefitted by homoeopathic medicines (positive ORIDL score).

Both the HH and OC were improved as evident from follow-up investigation. Pork aggravation altered; low back pain secondary to pelvic congestion also improved. Although this single case report cannot draw any certain conclusion, more number of case reports and observational studies/clinical trials on HH and OC are warranted.

Acknowledgement

We are thankful to Dr. Anil Khurana, Director General In-charge, Dr. Raj K. Manchanda, Ex-Director General, CCRH, for their suggestions to report such success stories in systematic manner for dissemination among scientific community. Last but not the least, we are grateful to the patient who gave consent to share this case report.

Informed consent

Due consent was obtained from the patient to disseminate the information as scientific case report. The patient understands that her name, photographs and initials will not be published.

Financial support and sponsorship

Nil.

	lyc.	puks.	ars.	bell.	rep.	nat-m.	sil.	caud.	nat-c.	cyd.	alum.	acon.	ark-c.	nat-ar.	thu.	tub.
	1	2	3	4	5	6	7	8	9	10	11	12	13	14	15	16
Clipboard 1																
1. MIND - MILDNESS (118) 3	2	3	3	1	2	3	3	1	1	1	1	2	1	1	2	1
2. MIND - COMPANY - desire for - alone agg.; when (84) 2	2	1	3	1	1	1	1	1	1	1	-	-	-	-	-	-
3. STOMACH - THIRSTLESS (216) 3	2	3	2	2	2	1	1	1	1	2	2	1	2	1	1	1
4. GENERALS - HEAT - lack of vital heat (291) 2	2	2	2	1	2	2	3	3	1	1	2	2	2	2	2	2
5. GENERALS - FOOD and DRINKS - pork - agg. (34) 5	1	3	1	1	3	2	1	1	2	3	1	1	2	2	1	1
6. GENERALS - FOOD and DRINKS - spices - desire (127) 1	1	2	1	-	1	1	-	1	-	-	1	1	1	1	-	1
7. FEMALE GENITALIA/SEX - MENSES - scanty (251) 3	2	3	2	1	3	3	2	2	2	3	2	1	-	2	1	-
8. FEMALE GENITALIA/SEX - MENSES - clotted (151) 1	2	3	-	3	1	1	-	2	-	3	-	-	1	-	1	2
9. FEMALE GENITALIA/SEX - MENSES - clotted - dark clots (44) 2	2	2	-	3	-	-	-	-	2	-	-	-	-	-	-	-
10. GENERALS - ANEMIA (263) 2	1	3	3	2	2	3	1	2	2	2	1	1	1	1	-	1
11. ABDOMEN - PAIN - Hypochondria - right (184) 1	3	-	2	3	1	2	1	3	2	1	2	1	1	-	1	-
12. ABDOMEN - PAIN - Hypogastrium - menses - during - agg. (58) 3	1	3	2	2	3	2	1	1	1	-	-	-	-	-	-	-
13. ABDOMEN - PAIN - Hypogastrium - warmth - amel. (3) 2	-	-	2	-	-	-	-	-	-	-	-	-	-	-	-	-
14. BACK - PAIN - Lumbosacral region - aching (19) 1	-	-	-	-	-	1	-	-	-	-	-	-	-	-	-	-
15. FEMALE GENITALIA/SEX - TUMORS - Ovaries - cysts (70) 1	1	1	1	1	1	1	1	-	-	-	-	-	-	-	1	-
16. GENERALS - TUMORS - hemangioma (8) 1	-	-	-	-	-	-	-	-	-	-	-	-	1	-	-	-

Figure 5: Repertorisation sheet

Conflicts of interest

None declared.

REFERENCES

- Heiken JP. Distinguishing benign from malignant liver tumours. *Cancer Imaging* 2007;7:S1-14.
- Kim JM, Chung WJ, Jang BK, Hwang JS, Kim YH, Kwon JH, et al. Hemorrhagic hemangioma in the liver: A case report. *World J Gastroenterol* 2015;21:7326-30.
- Bajenaru N, Balaban V, Savulescu F, Campeanu I, Patrascu T. Hepatic hemangioma –Review. *J Med Life* 2015;8:4-11.
- Schwartz SI, Husser WC. Cavernous hemangioma of the liver. A single institution report of 16 resections. *Ann Surg* 1987;205:456-65.
- Dawn CS. *Textbook of Gynaecology and Contraception*. 8th ed. Calcutta: Dawn Books Publication; 1985.
- Difference between Ovarian Cyst and Pcos; 11 July, 2017. Available from: <https://www.londonwomenscentre.co.uk/info/news/difference-ovarian-cysts-pcos>. [Last updated on 2017 Jul 11; Last accessed on 2019 Mar 15].
- Horowitz NS. Management of adnexal masses in pregnancy. *Clin Obstet Gynecol* 2011;54:519-27.
- Ross EK, Kebria M. Incidental ovarian cysts: When to reassure, when to reassess, when to refer. *Cleve Clin J Med* 2013;80:503-14.
- Trimble EL. The NIH consensus conference on ovarian cancer: Screening, treatment, and follow-up. *Gynecol Oncol* 1994;55:S1-3.
- Abduljabbar HS, Bukhari YA, Al Hachim EG, Alshour GS, Amer AA, Shaikhoon MM, et al. Review of 244 cases of ovarian cysts. *Saudi Med J* 2015;36:834-8.

- Gimeno ML. Homoeopathic treatment of ovarian cysts. *Br Homeopath J* 1991;80:143-8.
- Das D, Samadder A, Kayal SK, Khuda-Bukhsh AR. Removal of large sized ovarian cysts by potentized homeopathic remedies: A myth or a dependable alternative option. *Int J Complement Alt Med* 2016;3:88.
- Das D, Khuda-Bukhsh AR. A patient with uterine fundal leiomyoma and a large hemorrhagic cyst in right ovary cured by homeopathic remedies – A case report. *Indian J Med Case Rep* 2016;5:13-9.
- Das D, Haque S, Samadder A, Kayal SK, Khuda-Bukhsh AR. Removal of large sized ovarian cysts in three patients by administration of a single remedy, Thuja occidentalis: Hormonal assay and ultrasonographic images. *J Integrative Med Ther* 2016;3:9.
- Gupta G, Singh N, Singh R, Singh S, Nayak C, Khuran A. Evidence based clinical study on the effect of homoeopathic medicines in cases of ovarian cysts. *Indian J Res Homoeopathy* 2011;5:36-42.
- Patel RP. Chronic miasms in homoeopathy and their cure with classification of their rubrics/symptoms. In: Dr. Kent's Repertory (Repertory of Miasms). Indian edition. Kottayam: Hahnemann Homoeopathic Pharmacy; 1996.
- Schroyens F. *Synthesis – Repertorium Homoeopathicum Syntheticum*. 9.1 Ver. New Delhi: B Jain Publishers (P) Ltd.; 2009.
- Boericke W. *New Manual of Homoeopathic Materia Medica and Repertory*. 9th ed. New Delhi: B Jain Publishers (P) Ltd.; 2001.
- Allen HC. *Keynotes and Characteristics with Comparisons of some of the Leading Remedies of the Materia Medica*. 9th ed. New Delhi: B Jain Publishers (P) Ltd.; 1986.
- Reilly D, Mercer SW, Bikker AP, Harrison T. Outcome related to impact on daily living: Preliminary validation of the ORIDL instrument. *BMC Health Serv Res* 2007;7:139.

डिम्बग्रंथि पुटीका के साथ यकृत रक्तवाहिकाबुंद का प्रकरण

परिचय : यह डिम्बग्रंथि पुटीका के साथ यकृत रक्तगुल्म से पीड़ित 35 वर्षीय रोगी में बहुरुग्णता का प्रकरण है। यकृत के दोनों लोबों में कई तरह से परिभाषित समरूप से इकोजनिक नाडुलर घाव (आकार सबसे बड़ा नोड्यूल 1.64 X 1.64 सेमी) थे जो हिमेंजिओमा होना प्रदर्शित कर रहे थे, साथ ही यकृत का आकार बढ़ा हुआ था। पेल्विक कंजेशन सिंड्रोम के साथ दाएं डिम्बग्रंथि पुटीका का आकार 2.26 X 1.25 से.मी. था। पेल्विक कंजेशन सिंड्रोम के साथ दाएं डिम्बग्रंथि पुटीका का आकार 2.26 X 1.25 से.मी. था।

प्रकरण सार : इस प्रकरण का उपचार अग्रतला के क्षेत्रीय होम्योपैथी अनुसंधान संस्थान के बाह्य रोगी विभाग (ओपीडी) में 5 महीने की अवधि के लिए व्यक्तिषः होम्योपैथी के साथ किया गया था। होम्योपैथिक दवा पल्सेटिला, रोगी को व्यक्तिगतवादी दृष्टिकोण के आधार पर दी गई थी। रोगी को न केवल उसकी विद्वमान शिकायतों में सुधार हुआ, बल्कि नैदानिक मापदंडों में भी परिवर्तन हुआ। उपचार के बाद के परिणामों को प्रयोगशाला में जांच के साथ मिलान किया गया, जिसमें महत्वपूर्ण बदलाव दिखाई दिए। पेल्विक कंजेशन सिंड्रोम में सुधार के साथ होम्योपैथिक उपचार के बाद अल्ट्रासोनोग्राफी में कोई असामान्यता नहीं थी। इस मामले की रिपोर्ट बताती है कि जटिल और असामान्य मामलों में भी सही ढंग से चुनी गई होम्योपैथिक दवा फायदेमंद हो सकती है।

Un cas d'hémangiome hépatique avec kyste ovarien traité par l'homéopathie

Introduction : Il s'agit d'un cas de multimorbidité chez une patiente de 35 ans souffrant d'hémangiome hépatique avec kyste ovarien. Il y avait une hépatomégalie avec de multiples lésions nodulaires échogènes homogènes bien définies (le plus grand nodule mesurait 1,64 x 1,64 cm) dans les deux lobes du foie suggérant un hémangiome. Le kyste ovarien droit mesurait 2,26 x 1,25 cm et était accompagné d'un syndrome de congestion pelvienne. **Résumé du cas :** Ce cas a été traité par homéopathie personnalisée pendant une période de 5 mois au service de consultations externes de l'Institut régional de recherche en homéopathie d'Agartala. Le médicament homéopathique *Pulsatilla* a été administré à la patiente conformément à une approche individualiste. Non seulement la patiente s'est moins plainte mais il y a également eu un changement dans les paramètres de diagnostic. Les résultats après le traitement ont été corroborés par des examens de laboratoire de suivi qui ont montré des changements significatifs. L'échographie n'a révélé aucune anomalie évidente après le traitement homéopathique et a révélé une amélioration du syndrome de congestion pelvienne. Ce rapport de cas suggère qu'un médicament homéopathique bien choisi peut être bénéfique même dans des cas compliqués et inhabituels.

Caso de hemangioma hepático con quiste de ovario tratado con homeopatía

Introducción: Se trata de un caso de multimorbilidad en un paciente de 35 años con un hemangioma hepático y quiste de ovario. Se constató una hepatomegalia con múltiples lesiones nodulares bien definidas, homogéneamente ecogénicas (nódulo más grande de tamaño: 1,64 X 1,64 cm) en ambos lóbulos hepáticos, que es indicativa de hemangioma. El quiste de ovario tenía un tamaño de 2,26 x 1,25 cm con síndrome de congestión pélvica. **Resumen del caso:** Este caso se trató con homeopatía individualizada durante un periodo de 5 meses en el departamento ambulatorio del *Regional Research Institute for Homoeopathy*, Agartala. La paciente recibió el medicamento homeopático *Pulsatilla*, sobre la base de un planteamiento individualizado. Durante el tratamiento, no solo mejoraron sus molestias, sino que también se produjo un cambio en los parámetros diagnósticos. La ecografía reveló ninguna anomalía obvia después del tratamiento homeopático con mejoría en el síndrome de congestión pélvica.

Este informe de caso clínico indica que un medicamento homeopático correctamente elegido puede ser beneficioso incluso en casos inhabituales y complicados.

Homöopathische Behandlung eines Leberhämangioms mit Ovarialzyste

Einführung: Es handelt sich um eine 35-jährige multimorbide Patientin mit einem Hämangiom der Leber und Ovarialzyste. Sie wies eine Hepatomegalie mit multiplen nodulären homogen echogenen und gut definierten Läsionen (Ausmaß des größten Knotens: 1,64 x 1,64 cm) in beiden Leberlappen auf, mit Verdacht auf ein Hämangiom. Das Ausmaß der rechten Ovarialzyste war 2,26 x 1,25 cm mit einem pelvinem Kongestionssyndrom. **Zusammenfassung des Falls:** Dieser Fall wurde mit individualisierte Homöopathie während eines 5-monatigen Zeitraums in der Ambulanzabteilung des *Regional Research Institute for Homoeopathy*, Agartala (Indien) behandelt. Die Patientin erhielt das homöopathische Arzneimittel *Pulsatilla*, das ihr auf der Basis eines individualistischen Ansatzes verabreicht wurde. Es besserten sich nicht nur die Beschwerden der Patientin, sondern es ergaben sich auch Veränderungen in den diagnostischen Parametern. Die Ergebnisse nach der Behandlung wurden in den Laborkontrollen bestätigt, die signifikante Veränderungen zeigten. Es konnten keine offensichtlichen Anomalien im Ultraschall nach der Behandlung festgestellt werden. Das pelvine Kongestionssyndrom hatte sich verbessert. Dieser Fallbericht zeigt, daß ein gut ausgewähltes homöopathisches Mittel positive Auswirkungen auf komplizierte und ungewöhnliche Fälle haben kann.

一個以順勢療法處理肝臟血管瘤合併卵巢囊腫的個案

簡介：這是一位35歲的肝臟血管瘤合併卵巢囊腫的多發病病例。肝臟腫大伴多發清晰的均勻回聲結節性病變（最大結節大小為1.64x1.64 cm），位於肝臟兩葉，顯示有血管瘤。右側卵巢囊腫大小為2.26x1.25cm，伴有盆腔充血綜合症。

病例總結：本病例在阿加爾塔拉地區人類腫瘤研究所門診部（OPD）進行了為期5個月的個人化治療。在個人化治療的基礎上給予患者順勢療法藥物--白頭翁。患者不僅在主訴方面有所改善，而且在診斷參數方面也有所改變。隨訪化驗室調查證實了治療後的結果，顯示出顯著的變化。超聲波檢查顯示在使用順勢療法治療後，盆腔充血綜合症得到改善並已無明顯異常。本病例報告表明，即使在複雜和不尋常的個案中，正確選擇的順勢療法藥物可以有助益。