

# Case of lumbar spondylosis treated with Homoeopathic medicine *Calcarea fluorica*

Ranjit Sonny\*

Regional Research Institute (Homoeopathy), Under CCRH, Government of India, Guwahati, Assam, India

## Abstract

Chronic Low Back Pain (CLBP) is one of the most common problems with which people of all age groups report to physicians. It is a very troublesome complaint affecting day-to-day life, leading to decreased productivity. Amongst all the causes, lumbar spondylosis is one of the major causes of CLBP. Lumbar spondylosis commonly affects middle to later age groups. This case report describes patient with symptoms of recurrent pain in low back for the last 10 years. X-ray of the lumbosacral (L.S.) spine showed features of osteophyte confirming the diagnosis of lumbar spondylosis. After careful case-taking, homoeopathic medicine *Calcarea fluorica* in different potencies was prescribed as per homoeopathic principles with ever-increasing improvement. Pain in the low back gradually diminished. Ultimately, the patient got rid of all the symptoms with general improvement. After that, he was on placebo for 5 months. X-ray of the L.S spine done after treatment revealed no feature of lumbar spondylosis along with remission of osteophyte.

**Keywords:** *Calcarea fluorica*, Homoeopathy, Lumbar spondylosis, Osteophyte

## INTRODUCTION

Homoeopathy is the second largest way of treatment in terms of use and practice. Various difficult and rare cases are successfully treated by homoeopathic medicines. Through this article, a case of lumbar spondylosis is shared with the profession which had been treated with homoeopathic medicine *Calcarea fluorica*.

Low back pain is the leading cause of activity limitation and work absence throughout the world, imposing a high economic burden on individuals, families, communities, industries and governments.<sup>[1]</sup> Amongst different causes, lumbar spondylosis is the important cause of Chronic Low Back Pain (CLBP). Different age groups may suffer from this problem hampering their regular duties. There are a number of systems of medicine prevailing all over the world at our disposal. We all are aware with the usefulness of Homoeopathy in chronic conditions. Our Materia Medica reports many medicines whose sphere of action encompasses the complaints of spine. Amongst them, *Calcarea fluorica* is very effective if prescribed on the basis of symptom similarity. This case reflects the prowess of *Calcarea fluorica* in controlling low back pain due to lumbar spondylosis. Lumbar spondylosis is the osteoarthritis

of lumbar spine caused by degenerative changes in the spine. Osteophyte (a kind of exostosis) formation in the body of the spine is the frequent presentation in the skiagram. Pain, instability and stiffness in the low back are the usual symptoms present. Lumbar spondylosis usually presents as CLBP which is defined as pain symptoms in low back persisting beyond 3 months. There are a considerable number of people suffering from low back pain. Risk factors include obesity, female gender, older age, prior history of back pain, restricted spinal mobility, high levels of psychological distress, minimal physical activity, smoking and job dissatisfaction.<sup>[2]</sup> Amongst different causes, restricted spinal mobility arising out of lumbar spondylosis is the important cause.

The lifetime prevalence of non-specific (common) low back pain is estimated at 60%–70% in industrialised countries. The 2010 Global Burden of Disease Study estimated that

**\*Address for correspondence:** Dr. Ranjit Sonny,  
C/O Justice P. K. Sakia, H.NO. 11, Niribili Path, Ghoramara,  
Guwahati - 781 028, Assam, India.  
E-mail: [drranjitsonnymd@gmail.com](mailto:drranjitsonnymd@gmail.com)

**Received:** 21.10.2017; **Accepted:** 20.05.2019

### Access this article online

Quick Response Code:



Website:  
[www.ijrh.org](http://www.ijrh.org)

DOI:  
10.4103/ijrh.ijrh\_56\_17

This is an open access journal, and articles are distributed under the terms of the Creative Commons Attribution-NonCommercial-ShareAlike 4.0 License, which allows others to remix, tweak, and build upon the work non-commercially, as long as appropriate credit is given and the new creations are licensed under the identical terms.

**For reprints contact:** [reprints@medknow.com](mailto:reprints@medknow.com)

**How to cite this article:** Sonny R. Case of lumbar spondylosis treated with Homoeopathic medicine *Calcarea fluorica*. Indian J Res Homoeopathy 2019;13:125-30.

low back pain is amongst the top 10 diseases and injuries that account for the highest number of disability-adjusted life years worldwide.<sup>[1]</sup>

While jotting down this case, different websites such as PubMed, ScienceDirect.com, Karger.com and Liebertpub.com and some other journals were searched. Few studies were found in respect to CLBP. In one of the studies, it was concluded that Homoeopathy is ineffective for any type of pain.<sup>[3]</sup>

Two double-blind, randomised placebo-controlled studies were found, but in those studies, a combination of homoeopathic medicines was used.<sup>[4,5]</sup> In one of the studies, homoeopathic medicine was used for CLBP, but whether single medicine or multiple medicines used are not clear.<sup>[6]</sup> However, no case report was found where *Calcarea flourica* used for CLBP caused by lumbar spondylosis.

## CASE REPORT

It was a diagnosed case of lumbar spondylosis represented by M47.8 under ICD-10 classification. A businessman aged 61 years, Hindu by religion, came for the treatment on 4<sup>th</sup> February 2017. He was suffering from CLBP for the last 10 years. X-ray of the lumbosacral (L.S.) spine showed lumbar spondylosis with osteophyte formation on the body of the spine [Figure 1]. He took allopathic treatment for 1 month almost 1½ years ago without desired relief followed by no treatment for the last 1 year except regular morning walk. The modalities of the pain were aggravation from the first motion and amelioration by continued motion and pressure. There was relief from warm application also.

### Homoeopathic generalities

#### Mental

Mentally, he was irritable. There was an episode of grief due to death of 35 years old son 2 years ago. However, that attack of grief was causing no severe affection to the patient. The patient had coped himself with that.

#### Physical

The patient was fatty, flabby with big belly and dark complexion and short stature in height. Appetite was good, desire for sweet, salty food and meat. There was aversion to sour. Stool was regular and twice daily, semisolid. He had sound sleep. There were no significant dreams.

### Past history

There was a history of hypertension, for which he was taking antihypertensive drug prescribed by an allopathic physician. Anal fistula was operated 20 years ago.

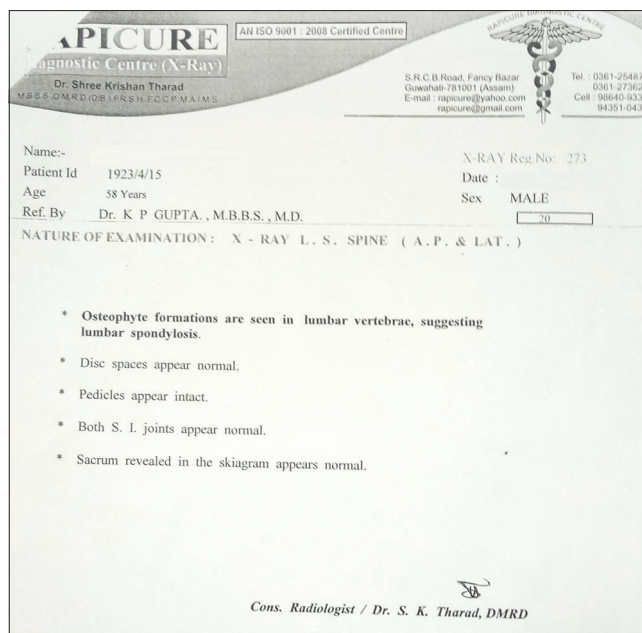
### Family history

In family history, both paternal and maternal, nothing significant was found.

Other systemic examinations were normal.

### Miasmatic analysis

Miasmatic analysis of all the presenting symptoms, including



**Figure 1:** X-ray of lumbosacral spine showing osteophyte dated 16/04/2015

mentals and physical generals, was done by referring to different classical books on miasms.<sup>[7]</sup> It was found that this case is of mixed-miasm with syphilitic predominance.

### Repertorisation

After case-taking and analysis, the characteristic symptoms were taken and converted into rubrics for repertorisation as follows:

- Back-pain-lumbo-sacral region
- Back-pain-motion-beginning of-agg
- Back-pain-motion-continued motion-amel
- Back-pain-warm-applications-amel
- Generals-exostosis.
- Generals-food and drinks-sweets-desire
- Generals-food and drinks-salt-desire
- Generals-food and drinks-meat-desire
- Generals-food and drinks-sour foods, acids-aversion

Repertorisation was done following Synthesis repertory<sup>[8]</sup> in Radar 10.0<sup>[9]</sup> on the basis of 9 rubrics. Following medicines appear as given in the repertorisation chart [Figure 2]. In the repertorisation chart, *Phosphorus* appeared as the topmost medicine, but *Calcarea flourica* was prescribed by referring to Materia Medica. The presenting symptom of the patient with modalities was more prominent in *Calcarea flourica* in comparison to the other medicines, especially with osteophyte formation.

### Treatment and follow-up

After case-taking, *Calcarea flourica* 30/4 doses was prescribed. The patient started improving, but no satisfactory relief of pain was found. *Calcarea flourica* 200/2 doses was given in the next follow up. Pain in low back diminished, but after 5 days, pain slightly reappeared. 1M potency of the same

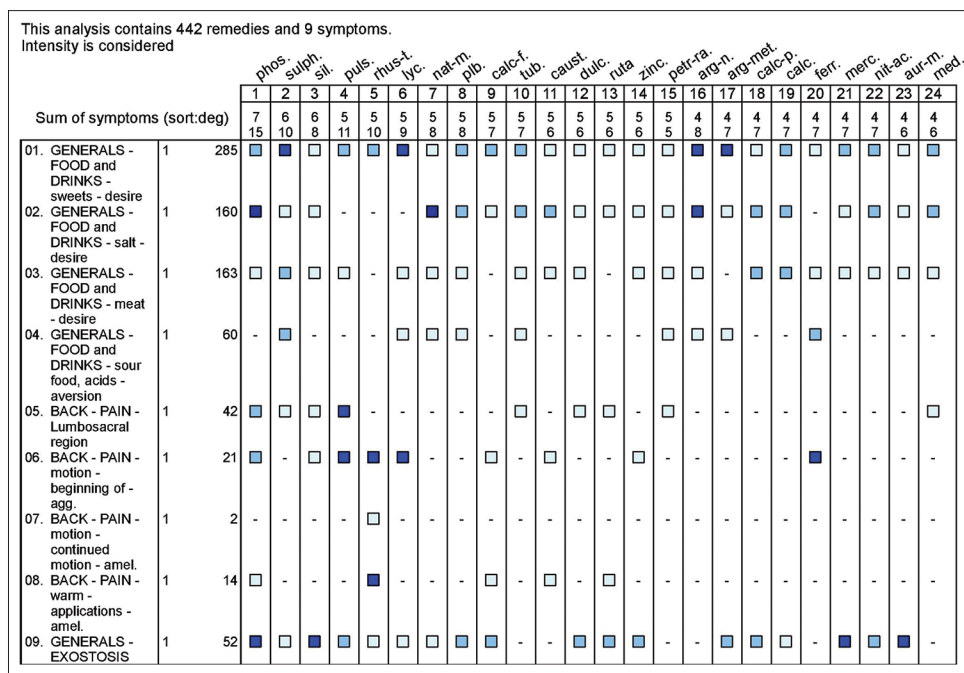


Figure 2: Repertorisation chart, RADAR 10.0 Software, 4<sup>th</sup> Feb, 2018

medicine was then prescribed. Pain was relieved completely but after 15 days again reappeared. *Calcarea fluorica* was again repeated in the same potency. That gave desired result and there was no reappearance of pain again. The patient was taking placebo for the last 5 months. In the meantime, X-ray of L.S spine was done, which showed remission of osteophyte [Figure 3] which was present previously. Before the last visit, he had travelled more than 1000 km by train even then there was no reappearance of pain. In the last visit, the patient came with acute upper respiratory tract infection, for which *Hepar sulphuris* 30/4 doses was prescribed on the basis of indications. Date-wise treatment and follow-ups are given in Table 1.

### DISCUSSION

After case analysis, it was found that the low back pain was emerging from bony defect. X-ray of the L.S. spine showed bony outgrowth in the form of osteophyte. Symptom of the patient was pain in low back < first motion > by continued motion. There was relief from warm massage. Such symptoms indicated *Calcarea fluorica*. This type of pain is also present in *Rhus toxicodendron*, but the sphere of action of *Rhus toxicodendron* is mainly the affections of soft tissue. Here, the involvement of spine led me to prescribe *Calcarea fluorica*. *Calcarea fluorica* was evolved from Schussler's 'bone salt' (CaF<sub>2</sub>) to full-fledged homoeopathic medicine after drug proving by Mezger in 1953 under the direction of Dr Leeser.<sup>[10]</sup> It is found in the surface of bones, in the enamel of teeth, in elastic fibres and in the cells of the epidermis. *Calcarea fluorica* prescribed in 30, 200 and 1M as per homoeopathic principles not only relieved the patient symptomatically but also helped resolve the pathology i.e. osteophyte formation. The patient

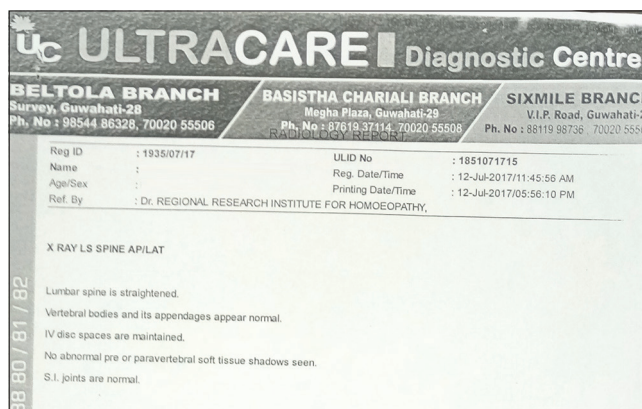


Figure 3: X-ray of lumbosacral spine done after treatment showing no osteophyte

continued antihypertensive drugs for hypertension. Symptoms of *Calcarea fluorica* in low back pain with the involvement of spine as stated by different stalwarts of Homoeopathy are quoted below:

Clarke – ‘It has been principally used for dispersing bony growths’ lumbago from strains; < after rest, > after moving a little and from warmth.<sup>[11]</sup>

Boger – ‘Exostoses’. ‘Lumbago’.<sup>[12]</sup>

Boericke – ‘Chronic lumbago; aggravated when beginning to move and ameliorated on continuous motion. Osseous tumours (exostosis)’. ‘Pain in the lower part of back with burning’.<sup>[13]</sup>

This case shows that symptoms similarity between the patient and of the medicine is the most important thing, irrespective of the name of the disease.<sup>[14]</sup>

**Table 1: Prescriptions and follow-ups**

| Date              | Symptoms   | Medicine                                    | Doses × days |
|-------------------|--|---|--------------|
| 4 February 2017   | Baseline presentation  | <i>Calcarea fluorica</i> 30                 | OD × 4       |
|                   | X-ray L.S. spine on 16 April 2015 shows osteophyte in lumbar vertebrae suggesting lumbar spondylosis | Placebo 30                                  | OD × 14      |
| 18 February 2017  | Better, pain low back less by 25%  | <i>Calcarea fluorica</i> 200                | OD × 2       |
| 4 March 2017      | Better, pain right side of low back diminished completely  | Placebo 30                                  | OD × 14      |
|                   | Pain in lumbosacral region less by 25%   | Placebo 30                                  | OD × 14      |
| 20 March 2017     | Better, LBP much relieved  | <i>Calcarea fluorica</i> 1 M                | OD × 2       |
|                   | Erectile dysfunction for 1 and ½ month   | Placebo 30                                  | OD × 14      |
| 12 April 2017     | Erectile dysfunction slightly improved   | <i>Calcarea fluorica</i> 1 M                | OD × 2       |
|                   | Reappearance of pain in right side of lumbosacral region and right leg <lying on affected side       | Placebo 30                                  | OD × 14      |
| 29 April 2017     | LBP and pain in right leg much less  | Placebo 30                                  | OD × 14      |
| 8 May 2017        | LBP diminished completely  | Placebo 30                                  | OD × 14      |
|                   | Pain in right leg for four days  |   |              |
| 23 May 2017       | LBP and pain right leg absent  | Placebo 30                                  | OD × 14      |
| 7 June 2017       | No LBP, occasional pain in right calf  | Placebo 30                                  | OD × 14      |
| 22 June 2017      | No complaint   | Placebo 30                                  | OD × 14      |
|                   | Blood uric acid level on 7 June 2017-7.75 mg/dl  |   |              |
| 11 July 2017      | No complaint   | Placebo 30                                  | OD × 14      |
| 14 July 2017      | No complaint   | Placebo 30                                  | OD × 14      |
|                   | Appetite good<br>Sleep sound.  |   |              |
| 26 July 2017      | X-ray L.S. spine dated 12 July 2017 shows no osteophyte in lumbar spine, no lumbar spondylosis       |   |              |
|                   | Patient is better. No pain   | Placebo 200                                 | OD × 7       |
| 2 August 2017     | Patient is better  | Placebo 200                                 | OD × 20      |
|                   | Mild pain in right leg for 6 days  | Application of hot fomentation to right leg |              |
| 28 September 2017 | No pain in low back  | <i>Hepar sulphuris</i> 30                   | BD × 2       |
|                   | Cough with feverish sensation and chilliness<br>Hoarseness of voice                                  | Placebo 30                                  | OD × 7       |
| 12 October 2017   | History of taking chilled water and exposure to blow of wind while travelling in train               |   |              |
|                   | No pain  | Placebo 30                                  | OD × 14      |
|                   | Generally feels better<br>Sleep sound<br>Stool regular<br>Serum uric acid on 27/9/17-4.2 mg/dl       |   |              |

OD: Once a day; BD: Twice a day; LBP: Low back pain; L.S: Lumbosacral

Indication, i.e., symptom, is the only weapon in our hand to treat diseases. During drug proving, we find numerous symptoms of a particular drug; amongst them, there are few characteristics and rare symptoms which represent the medicine as a whole which are termed keynote symptoms or ‘prognostic factors’ by the modern homoeopathic researchers. We should look for those symptoms in patients and match with that of medicine consulting repertory if required.

## CONCLUSION

This case, of cured osteophyte along with diminution of symptoms, provides a clinical evidence of successful homoeopathic management of one of the most common and troublesome conditions-lumbar spondylosis.

## Declaration of patient consent

The authors certify that they have obtained all appropriate patient consent forms. In the form the patient(s) has/have given his/her/their consent for his/her/their images and other clinical information to be reported in the journal. The patients understand that their names and initials will not be published and due efforts will be made to conceal their identity, but anonymity cannot be guaranteed.

## Financial support and sponsorship

The study was funded by Ministry of AYUSH, Government of India.

## Conflicts of interest

None declared.

## REFERENCES

1. World Health Organisation. Geneva: Priority Diseases and Reasons for Inclusion. Available from: [http://www.who.int/medicines/areas/priority\\_medicines/Ch6\\_24LBP.pdf](http://www.who.int/medicines/areas/priority_medicines/Ch6_24LBP.pdf). [Last accessed on 2017 Sep 20].
2. Fauci AS, Braunwald E, Kasper DL, Hauser SL, Longo DL, Jameson JL. Harrison's Principles of Internal Medicine. 17<sup>th</sup> ed., Vol. 1. New York: MacGraw Hill Companies Inc.; 2008. p. 115.
3. Ernst E, Pittler MH. Experts' opinions on complementary/alternative therapies for low back pain. *J Manipulative Physiol Ther* 1999;22:87-90.
4. Morris M, Pellow J, Solomon EM, Tsele-Tebakang T. Physiotherapy and a homeopathic complex for chronic low-back pain due to osteoarthritis: A randomized, controlled pilot study. *Altern Ther Health Med* 2016;22:48-56.
5. Beer AM, Fey S, Zimmer M, Teske W, Schremmer D, Wiebelitz KR, et al. Effectiveness and safety of a homeopathic drug combination in the treatment of chronic low back pain. A double-blind, randomized, placebo-controlled clinical trial. *MMW Fortschr Med* 2012;154 Suppl 2:48-57.
6. Gmünder R, Kissling R. The efficacy of homeopathy in the treatment of chronic low back pain compared to standardized physiotherapy. *Z Orthop Ihre Grenzgeb* 2002;140:503-8.
7. Mast HH. The Foundation of The Chronic Miasms in The Practice of Homoeopathy, Florida: Lutea Press, LLC; 2005.
8. Schroyens F. *Synthesis Repertorium Homeopathicum Syntheticum*. 9.1 ed. New Delhi: B. Jain Publishers (P) Ltd.; 2009.
9. Radar 10-EH. Belgium: Archibel Homeopathic Software; 2009.
10. Julian OA. *Dictionary of Homoeopathic Materia Medica of 131 New Homoeotherapeutics*. Reprint ed. New Delhi: B. Jain Publishers (P) Ltd.; 2006. p. 64-5.
11. Clarke JH. *A Dictionary of Practical Materia Medica*. Vol. 1. New Delhi: B. Jain Publishers (P) Ltd.; 2013. p. 353-4.
12. Boger CM. *A Synoptic Key to the Materia Medica*. Low Priced Edition. New Delhi: B. Jain Publishers (P) Ltd.; 2002:147-8.
13. Boericke W. *Boericke's New Manual of Homoeopathic Materia Medica with Repertory*. Reprint Edition. New Delhi: B. Jain Publishers (P) Ltd.; 2008:133-5.
14. Hahnemann S. *Organon of Medicine*. Low Price Edition. New Delhi: B. Jain Publishers (P) Ltd.; 2002:71-2.

### कल्केरिया फ्लोरिका के साथ उपचारित कशेरुकासन्धिशोथ

जीर्ण निचली पीठ का दर्द सबसे आम समस्याओं में से एक है जिससे ग्रस्त सभी आयु वर्ग के लोग चिकित्सकों को सूचित करते हैं। यह ऊर्जा को कम कर, दिन-प्रतिदिन के जीवन को प्रभावित करने वाली एक बहुत ही परेशान करने वाली समस्या है। सभी कारणों में, कमर संबंधी कशेरुकासन्धिशोथ, जीर्ण निचली पीठ के दर्द (सीएलबीपी) के प्रमुख कारणों में से एक है। कमर संबंधी कशेरुकासन्धिशोथ आमतौर पर मध्यम आयु वर्ग के लोगों को प्रभावित करता है। इस मामले में एक मरीज पिछले 10 वर्षों से पीठ के निचले हिस्से में बार-बार होने वाले दर्द के लक्षणों को प्रस्तुत किया। रीढ़ के एक्स-रे में कमर संबंधी कशेरुकासन्धिशोथ की पुष्टि करने वाली विशेषताएं दिखाई दी। मामले में सावधानी बरतते हुए, होम्योपैथिक औषधि कैल्केरिया फ्लोरिका को विभिन्न पोटेंसीज में दिया गया। दर्द की तीव्रता धीरे-धीरे कम हो गई। अंततः रोगी सामान्य सुधार के साथ-साथ दर्द से मुक्त था। उपचार उपरांत किए गए रीढ़ के एक्स-रे में कमर संबंधी कशेरुकासन्धिशोथ के साथ-साथ अस्थि-पंजर संबंधी कोई लक्षण दिखाई नहीं दिए। इसलिए यह मामला फिर से पुष्टि करता है कि होम्योपैथी जीर्ण स्थितियों जैसे कमर संबंधी कशेरुकासन्धिशोथ का प्रभावी ढंग से उपचार करती है।

### Étude de cas : Un cas diagnostiqué de lombarthrose traitée avec le calcarea flourica

La lombalgie chronique est un des problèmes les plus communs qui incite les gens de tout âge à consulter un médecin. Il s'agit d'un symptôme très gênant qui nuit à la vie quotidienne menant ainsi à une baisse de la productivité. Parmi toutes les causes, la lombarthrose est une des principales causes de la lombalgie chronique (LC). La lombarthrose affecte généralement les personnes d'âge moyen ou avancé. Dans le cas présent, un patient s'est présenté avec des symptômes de douleur récurrente dans le bas du dos depuis 10 ans. Une radiographie de la colonne vertébrale lombaire a révélé des caractéristiques confirmant le diagnostic d'arthrose lombaire. Après une étude détaillée du cas, le médicament homéopathique *Calcarea flourica* a été prescrit à des dilutions différentes. L'intensité de la douleur a progressivement diminué. Finalement, le patient n'avait plus de douleur et a montré une amélioration générale. Une radiographie de la colonne lombaire faite après le traitement n'a révélé aucun signe de lombarthrose et a montré la disparition des ostéophytes. Ce cas confirme donc l'efficacité de l'homéopathie dans le traitement des problèmes de santé chroniques tels que l'arthrose lombaire.

### **Caso diagnosticado de espondilosis lumbar tratada con *Calcareafluórica***

El dolor lumbar crónico es uno de los problemas más comunes por el que personas de todos los grupos de edades consultan con el médico. Se trata de un problema muy molesto que afecta la vida cotidiana y da lugar a una reducción de la productividad. La espondilosis lumbar es una de las causas principales del Dolor Lumbar Crónico (DLC). La espondilosis lumbar suele afectar a grupos de edades medianas o mayores. En este caso, un paciente se presentó con síntomas de dolor lumbar recurrente durante los últimos 10 años. La radiografía de la columna lumbar mostró características que confirmaban el diagnóstico de espondilosis lumbar. Tras una toma detenida del caso, se prescribió el medicamento homeopático *Calcareafluórica* en diferentes potencias. El dolor fue disminuyendo de forma gradual. Finalmente, el paciente estaba asintomático y mostraba una mejoría general. La radiografía de la columna lumbar, tomada tras el tratamiento, mostró ausencia de signos de espondilosis lumbar y la remisión de los osteofitos. En consecuencia, este caso reafirma que la homeopatía trata eficazmente las patologías crónicas como la espondilosis lumbar.

### **Fallbericht einer mit *Calcarea fluorica* behandelten lumbalen Spodylose mit gesicherter Diagnose**

Chronische Kreuzschmerzen sind eines der häufigsten Probleme, mit denen Menschen aller Altersgruppen Ärzte konsultieren. Dies ist eine sehr problematische Beschwerde, die sich auf den Alltag auswirkt und zu einer verminderten Produktivität führt. Unter allen Ursachen ist die Spodylose der Lendenwirbelsäule eine der Hauptursachen für chronische Schmerzen im unteren Rückenbereich (CLBP). Die Spodylose der Lendenwirbelsäule betrifft häufig mittlere bis ältere Altersgruppen. In diesem Fall hatte ein Patient in den letzten zehn Jahren Symptome mit wiederkehrenden Schmerzen im unteren Rückenbereich. Das Röntgenbild der Lendenwirbelsäule zeigte Merkmale, die die Diagnose einer Lendenwirbelsäulenspodylose bestätigten. Nach sorgfältiger Fallaufnahme wurde das homöopathische Arzneimittel *Calcarea fluorica* in verschiedenen Potenzen verordnet. Die Schmerzintensität nahm allmählich ab. Letztendlich war der Patient frei von Schmerzen und es kam zu einer allgemeinen Besserung. Röntgenaufnahmen der Lendenwirbelsäule, die nach der Behandlung durchgeführt wurden, zeigten keine Hinweise auf ein lumbales Spodylose und eine Remission von Osteophyten. Dieser Fall bestätigt erneut, dass die Homöopathie in chronischen Beschwerden, wie die lumbale Spodylose, wirksam ist.

### **Diagnosed Case of Lumbar Spondylosis Treated With *Calcarea Flourica***

#### **以氟化鈣治療診斷為腰椎間盤退化的個案**

慢性腰痛是各年齡組的人向醫生報告的最常見問題之一。這是一個非常麻煩的不適，影響日常生活，導致生產力下降。在所有的病因中，腰椎間盤退化是引起慢性腰痛（CLBP）的主要原因之一。腰椎間盤退化通常影響中年至老年年齡組別。在這種情況下，患者在過去十年中出現了背部復發性疼痛的症狀。腰椎X射線片顯示出確診腰椎間盤退化的特徵。在仔細觀察個案後，處方了不同層級的順勢療法藥物—氟化鈣。疼痛強度逐漸減弱。最終，病人從疼痛中解脫出來，同時整體也得到了改善。治療後的腰椎X射線片未發現腰椎間盤退化的特徵而且骨贅也有舒緩。因此，該個案再次證明順勢療法可有效治療腰椎間盤退化等慢性疾病。