

Homoeopathic drug dilutions of *Thuja occidentalis* attenuate complete Freund's adjuvant-induced arthritis in Wistar rats

Sachin S. Patil¹, Umesh B. Mahajan¹, Sameer N. Goyal^{1,2}, Sateesh Belemkar³, Chandragouda R. Patil^{1*}

¹Department of Pharmacology, R. C. Patel Institute of Pharmaceutical Education and Research, ²Principal, SVKM's Institute of Pharmacy, ³Department of Pharmacology, School of Pharmacy and Technology Management, SVKM's Narsee Moonjee Institute of Management and Studies, Shirpur, Dhule, Maharashtra, India

Abstract

Context: *Thuja occidentalis* is prescribed in Homoeopathy in treating rheumatoid arthritis. We speculated the anti-arthritis mechanism of Homoeopathic dilutions of *Thuja occidentalis* against the complete Freund's adjuvant (CFA)-induced arthritis in rats. **Materials and Methods:** Arthritis was induced ($n = 28$) by subplantar injection of 0.1 ml CFA in the right hind paw of rats. The oral dose of crude *Thuja occidentalis* was 30 mg/kg/b. i. d and that of Homoeopathic dilutions was 0.1 ml/b. i. d. Orally administered diclofenac at 5 mg/kg/day served as a standard. The treatments continued for 24 days. The severity of arthritis was determined weekly as rise in paw volume, mechanical allodynia and changes in body weight. On the 25th day, X-ray imaging of the arthritic paws was recorded, and the biopsy samples extracted from the paws were subjected to the estimation of pro-inflammatory cytokines and histological evaluations. **Results:** *Thuja occidentalis* Homoeopathic dilutions and its crude form protected rats against the CFA-induced arthritic lesions. The mother tincture, 6cH, 30cH and 200cH dilutions of *Thuja occidentalis* significantly reduced the CFA-induced rise in paw volume, reduced the mechanical allodynia and also reduced the levels of interleukin (IL) IL-1, IL-6 and tumour necrosis factor alpha in paw tissue. CFA-induced articular changes, oedema, cellular infiltrations and cartilage damage were reduced by *Thuja occidentalis* dilutions. The radiological images indicated that *Thuja occidentalis* treatment reduced the CFA-induced joint swelling, bone erosion and joint space narrowing. **Conclusion:** Our findings substantiate the anti-arthritis effects of *Thuja occidentalis* Homoeopathic dilutions against CFA-induced arthritis and indicate that Homoeopathic dilutions of *Thuja occidentalis*, particularly 6cH dilution, exert more potent anti-arthritis effects than its crude form.

Keywords: Complete Freund's adjuvant, Cytokines, Homoeopathy, *Thuja occidentalis*

INTRODUCTION

Thuja occidentalis is grown as an ornamental plant. In alternative medicines, *Thuja occidentalis* has been used in the treatment of inflammatory and rheumatic conditions.^[1] The mother tincture (MT) and Homoeopathic dilutions of *Thuja occidentalis* are used in the treatment of upper respiratory tract infections and inflammatory conditions associated with infections including bronchitis, pharyngitis, otitis media and sinusitis.^[1,2] The *in vitro* and *in vivo* experimental studies on the extracts of *Thuja occidentalis* have reported its immunostimulatory effects including increased proliferation of splenocytes in mice, induction of interleukin (IL) IL-1, IL-6 and tumour necrosis factor alpha (TNF- α) from the mouse macrophage^[3] induction of CD4+ T-cell and production of IL-2 and interferon- γ .^[4] However, in the tumour-bearing mice, aqueous extract of *Thuja occidentalis*

and its polysaccharide fraction have been reported to stimulate cell-mediated immunity. Treatment of tumour-bearing mice with *Thuja occidentalis* resulted in increased natural killer cell activity, antibody-dependent cellular cytotoxicity and antibody-dependent complement-mediated cytotoxicity. The treatment with *Thuja occidentalis* extracts decreased the elevated level of IL-1 β , IL-6, granulocyte-macrophage colony-stimulating factor and TNF- α in the serum of metastatic tumour-bearing mice. This study concluded that

***Address for correspondence:** Dr. Chandragouda R. Patil, Department of Pharmacology, R. C. Patel Institute of Pharmaceutical Education and Research, Shirpur, Dhule - 425 405, Maharashtra, India. E-mail: pchandragouda@yahoo.com

Received: 03.09.2018; **Accepted:** 02.01.2019

This is an open access journal, and articles are distributed under the terms of the Creative Commons Attribution-NonCommercial-ShareAlike 4.0 License, which allows others to remix, tweak, and build upon the work non-commercially, as long as appropriate credit is given and the new creations are licensed under the identical terms.

For reprints contact: reprints@medknow.com

How to cite this article: Patil SS, Mahajan UB, Goyal SN, Belemkar S, Patil CR. Homoeopathic drug dilutions of *Thuja occidentalis* attenuate complete Freund's adjuvant-induced arthritis in Wistar rats. Indian J Res Homoeopathy 2018;12:202-11.

Access this article online

Quick Response Code:



Website:
www.ijrh.org

DOI:
10.4103/ijrh.ijrh_49_18

Thuja occidentalis inhibited the production of pro-inflammatory cytokines and stimulated cell-mediated immune response.^[5] Aqueous extract of *Thuja occidentalis* and polysaccharide fraction have been reported to reduce the paw oedema induced by carrageenan, dextran sulphate, serotonin, bradykinin, histamine and prostaglandin E₂.^[6] This study has reported that the *Thuja occidentalis* extract reduced the myeloperoxidase activity, decreased pro-inflammatory cytokine levels and reduced oxidative stress in mice challenged with different phlogistic agents.^[6] All these evidences suggest that *Thuja occidentalis* extract may have a role in the treatment of inflammatory and autoimmune conditions. In Homoeopathy, *Thuja occidentalis* is prescribed in the treatment of rheumatoid arthritis. However, controlled clinical trials on the Homoeopathic dilutions of *Thuja occidentalis* as an anti-arthritic medicine have either proved non-conclusive or have reported no benefit over the placebo.^[7,8] A prior study conducted by our group revealed that the Homoeopathic dilutions of *Thuja occidentalis* inhibit the lipopolysaccharide-induced pro-inflammatory cytokine release and oxidative stress in the mouse macrophage cell line (RAW-264.7) *in vitro*.^[9] Similar effects were observed in the *in vivo* model of lipopolysaccharide (LPS)-challenged mice. The MT, 3cH, 6cH, 30cH and 200cH Homoeopathic dilutions of *Thuja occidentalis* inhibited the *in vitro* and *in vivo* effects of bacterial polysaccharides on the mouse macrophages.^[9] The immunomodulatory and anti-inflammatory activities of the *Thuja occidentalis* aqueous extract and its polysaccharide-rich extract have been verified through *in vitro* and *in vivo* experimental models.^[10] In the present study, we evaluated the anti-arthritic effects of Homoeopathic dilutions of *Thuja occidentalis* against the complete Freund's adjuvant (CFA)-induced arthritis in rats.

MATERIALS AND METHODS

Animals

Male Wistar rats (150–200 g) were used for the study. The animals were obtained from the Central Animal House Facility, Department of Pharmacology, R. C. Patel Institute of Pharmaceutical Education and Research, Shirpur. Animals were housed in well-ventilated polypropylene cages and maintained under standard conditions (25°C ± 2°C, 12:12 h light and dark cycle) in the departmental animal house. The animals were fed with standard pelletized feed (Amrut Rat feed, Pune) and water was provided *ad libitum*. The study was approved by the Institutional Animal Ethical Committee registered with the Committee for the Purpose of Control and Supervision of Experiments on Animals, India (Approval No: IAEC/RCP/IPER/2017–18/15).

Drug and chemicals

Homoeopathic dilutions of *Thuja occidentalis* were manufactured by Sintex Industries Pvt. Ltd., Ahmedabad, India, with the following batch specifications: MT (MT51/THO), *Thuja occidentalis* 6cH (230THO6), *Thuja occidentalis* 30cH (230THO30) and *Thuja occidentalis* 200cH (230THO).

The *Thuja occidentalis* leaf extract (crude form) was supplied by Indian Pharmacopoeia Laboratory, Ghaziabad (Authentication Letter No. HPL/P. 19029/Part-1/2013-2014/399). CFA (Difco, USA. Lot No. 0090500) was purchased through an Indian distributor. Diclofenac sodium (Brand: Dynapar Injection, Batch No. D23S118) was purchased from a local Vendor. ELISA Kits for TNF- α (Cas No. 88–7324), IL-1 β (Cas No. 88–7013) and IL-6 (Cas No. 88–7064) were obtained from eBioscience, USA.

Experimental protocol

Male Wistar rats were divided into eight groups, with each containing four animals. Group I was control and received a single daily dose of 1 ml normal distilled water by oral gavage, Group II CFA-injected group, Group III was standard and received a standard drug diclofenac at 5 mg/kg, p. o., Group IV to Group VII received MT, 6cH, 30cH and 200cH. Group VIII received *Thuja occidentalis* leaf powder twice daily at 30 mg/kg of body weight as a suspension in the 0.5% carboxymethyl cellulose (CMC) in water.

Induction of arthritis in rats

Arthritis was induced by subplantar injection of 0.1 ml of adjuvant into the right hind paw of each rat on day 0.^[10]

Dosage preparation and administration

The Homoeopathic dilutions of *Thuja occidentalis* were prepared as 0.1 ml of each dilution was added to 1.0 ml of sterile distilled water and administered through oral gavage to respective groups twice daily.^[9] *Thuja occidentalis* crude powder was suspended in 0.5% CMC and administered through oral gavage at a dose of 30 mg/kg. Care was taken to abstain animals from food immediately before and after drug administration for at least 2 h.^[11] *Thuja occidentalis* crude form and dilutions were administered twice daily once for 21 days starting from the day of CFA injection.

Evaluation parameters

Evaluation of the severity of arthritis

The primary and secondary lesions and paw volume of injected and non-injected paws were measured using a digital Plethysmometer (UGO Basile 7140, Italy). The lesions were measured on 0, 7th, 14th, 21st and 25th days after injection of the adjuvant.^[12]

Evaluation of mechanical allodynia

The Von Frey plantar test is a measure for acute mechanical pain sensitivity. An Electronic Von Frey anesthesiometer, (IITC Life Sciences, Australia) was used to measure the paw withdrawal threshold (PWT). The PWT was reported as the pressure in grams required to elicit paw withdrawal. The PWT was determined on days 0, 7, 14 and 21.^[13]

Effect on change in body weight

Changes in body weight have also been used to assess the course of the disease and the response to therapy of anti-inflammatory drugs; as the incidence and severity of arthritis increased, the changes in the body weight of the rat also occurred during the course of experimental period of every 3rd day.^[14]

Radiological analysis

On the day 25, animals were anaesthetised with anaesthetic ether. Radiographs of the adjuvant injected hind paws were taken with an X-ray instrument (Portable 100mA LF X Ray Machine, Vision Medicaid Equipment Pvt. Ltd, India). The film focus distance was 60", and the machine was operated at 43 kV peak, 2 mA. The radiographs of each rat were evaluated for radiographic changes by a board-certified radiologist for the following changes and scores were given according to the severity:

- Soft-tissue swelling around the joints of hind paws (0–4)
- Periarticular bone resorption (0–4)
- Periarticular bony erosions (0–4)
- Joint space narrowing (0–4).

Grading of cellular infiltration (polymorphonuclear cells, macrophages or lymphocytes), angiogenesis, synovial hyperplasia, pannus formation, narrowing of joint space, cartilage destruction and bone erosion of the ankle joints were examined in a blind fashion by two independent observers using a semi-quantitative scale from 0 (normal), 1 (mild changes), 2 (moderate changes) and 3 (severe changes).^[15]

Biochemical analysis of the biopsy samples obtained from the complete Freund's adjuvant-injected paw

Preparation of homogenate

On the 25th day of dosing, the rats were sacrificed by using high dose of ketamine and xylazine. The hind paw tissue biopsy samples were collected. A 10% tissue homogenate was prepared in ice-cold phosphate-buffered saline by using homogeniser followed by sonication for 5 min. The homogenate was stored at –20°C till further analysis.^[14]

Determination of pro-inflammatory cytokines

Pro-inflammatory cytokines were determined in the homogenate of hind paw tissue by using sandwich ELISA. Cytokines such as TNF- α , IL-6 and IL-1 β were determined according to protocol provided by manufacturer, and the values were calculated from optical density.^[16]

Histopathological analysis

At the end of the experiment, hind paw of rat was isolated and stored in 10% formalin solution. Thin sections of rat paw were taken and fixed in paraffin and stained using haematoxylin and eosin. Arthritic scores were measured by proving blinded slide to pathologist.

Classification of articular changes

On histopathological examination of the distal tibia, tarsal bones, hind joint and tibiotarsal joint, the articular changes were classified into the following three categories:

- Soft-tissue changes, including that of the synovium and periarticular soft tissues
- Bony changes, including both reactive and destructive alterations
- Articular changes, with particular attention to the articular cartilage, pannus formation, ankylosis and joint obliteration. Each of these parameters was scored on a

scale of 0–3.^[14]

where

0 = absent, 1 = mild, 2 = moderate and 3 = severe.

Components of the histopathological grading system are as follows:

Each parameter was graded mild, moderate or severe, using the following criteria.

Scoring table:

0 = absent, 1 = mild, 2 = moderate and 3 = severe.^[17]

Statistical analysis

The data were expressed as mean \pm standard error of the mean. The statistical analysis was performed using one-way and two-way analysis of variance followed by Bonferroni's multiple comparison *Post hoc* test and Holm–Sidak's multiple comparisons test; *** $P < 0.001$; ** $P < 0.01$, * $P < 0.05$ as compared with the CFA group; ### $P < 0.001$ as compared with the normal group. * $P < 0.05$ was considered statistically significant.

RESULTS

Effect of *Thuja occidentalis* on the CFA-induced rise in the volume of the ipsilateral paw

CFA injection induced a time-dependent and significant rise in the paw volumes. On the 25th day, average volume of the CFA-injected paws was almost double than the normal paw volume. *Thuja occidentalis* MT, 6cH and 30 cH dilutions significantly reduced the ipsilateral paw volume that indicated a reduction in the inflammatory changes induced by CFA injection ($P < 0.001$). The crude form, MT and 200cH dilutions were less effective in reducing the inflammatory changes induced by CFA. The effect of *Thuja occidentalis* 6cH dilution was most potent amongst its tested dilutions. The standard drug diclofenac restricted the paw inflammation and on 25th day of observation, the paw volume of this group was almost similar to that of the normal control group as shown in Figure 1.

Effect of *Thuja occidentalis* on the complete Freund's adjuvant-induced rise in the volume of the contralateral paw

The rise in the volume of contralateral paw indicates immune-mediated component of the effect of CFA. All the tested dilutions of *Thuja occidentalis* along with its crude form significantly inhibited the rise in the volume of contralateral paw ($P < 0.001$). MT treatment was least effective in reducing the paw volume. *Thuja occidentalis* dilutions appeared to be as effective as diclofenac in reducing the volume of the contralateral paw [Figure 2].

Effect of *Thuja occidentalis* on the paw withdrawal threshold

The mechanical allodynia was determined in the CFA-injected paws. It was observed that CFA-induced inflammation was associated with significant allodynia evident as a decrease in the pressure required to elicit paw withdrawal ($P < 0.001$).

Thuja occidentalis dilutions 6cH, 30cH and 200cH were effective in increasing the PWT, whereas the MT and crude form were the least effective [Figure 3]. The PWT of rats treated with diclofenac was similar to that of the control group.

Effect of *Thuja occidentalis* treatments on the body weight changes in the complete Freund's adjuvant-treated rats

The pain and immobility associated with the CFA-induced inflammation lead to decrease in the food intake. Such reduced weight gain was evident in only CFA-treated rats. In the rats treated with 6cH dilution, the body weight gain was similar to that of the normal group. The groups treated with other *Thuja occidentalis* dilutions had weight gain during the observation period of 25 day; however,

the weight gain was lesser as compared to the control group [Figure 4].

Thuja occidentalis treatments inhibited the radiological changes induced by complete Freund's adjuvant

The joint radiographs of representative rats from each group were analysed for changes such as swelling, bone resorption, bone erosion and narrowing of the joint spaces. CFA induced soft-tissue swelling, narrowed the joint space and induced bone erosion and resorption. These changes were inhibited by the *Thuja occidentalis* treatment [Figure 5]. The radiological alterations were arbitrarily scored by a blinded radiologist [Table 1].

Effect of *Thuja occidentalis* on the release of

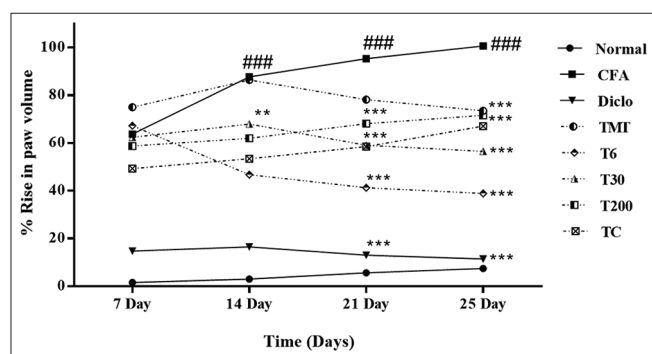


Figure 1: Effect of *Thuja occidentalis* on the complete Freund's adjuvant-induced rise in the volume of the ipsilateral paw. CFA: Complete Freund's adjuvant-injected rats; Diclo: Standard group; TMT: *Thuja* mother tincture; T6: *Thuja* 6cH; T30: *Thuja* 30cH; and T200: *Thuja* 200cH; TC: *Thuja* crude drug. Data were expressed as mean \pm standard error of the mean; $n = 4$. Repeated measure analysis of variance followed by Holm-Sidak's multiple comparisons test; $P < 0.05$; $F = 42.06$. *** $P < 0.001$ as compared with complete Freund's adjuvant group; ### $P < 0.001$ as compared with normal group

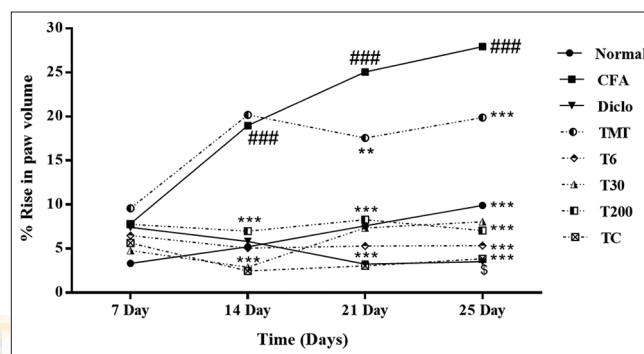


Figure 2: Effect of *Thuja occidentalis* on the complete Freund's adjuvant-induced rise in the volume of the contralateral paw. Data were expressed as mean \pm standard error of the mean; $n = 4$. Repeated measure analysis of variance followed by Holm-Sidak's multiple comparisons test; $P < 0.05$; $F = 10.25$. *** $P < 0.001$ as compared with Complete Freund's adjuvant group; ### $P < 0.001$ as compared with normal group. CFA: Complete Freund's adjuvant injected rats; Diclo: Standard group; TMT: *Thuja* mother tincture; T6: *Thuja* 6cH; T30: *Thuja* 30cH; and T200: *Thuja* 200cH; TC: *Thuja* crude drug

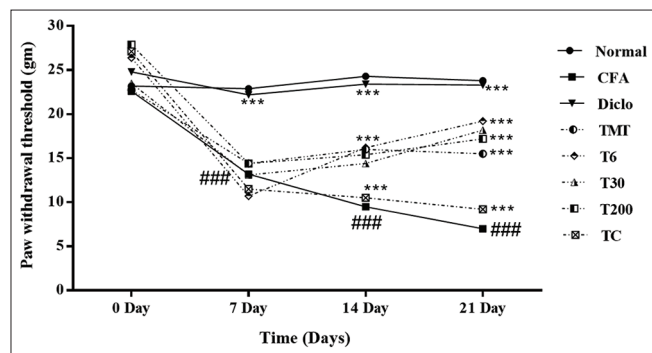


Figure 3: Effect of *Thuja occidentalis* on the paw withdrawal threshold. Data were expressed as mean \pm standard error of the mean; $n = 4$. Repeated measures analysis of variance followed by Holm-Sidak's multiple comparisons test; $P < 0.05$; $F = 4.75$. *** $P < 0.001$ as compared with complete Freund's adjuvant group; ### $P < 0.001$ as compared with normal group. CFA: complete Freund's adjuvant-injected rats; Diclo: standard group; TMT: *Thuja* mother tincture; T6: *Thuja* 6cH; T30: *Thuja* 30cH; and T200: *Thuja* 200cH; TC: *Thuja* crude drug

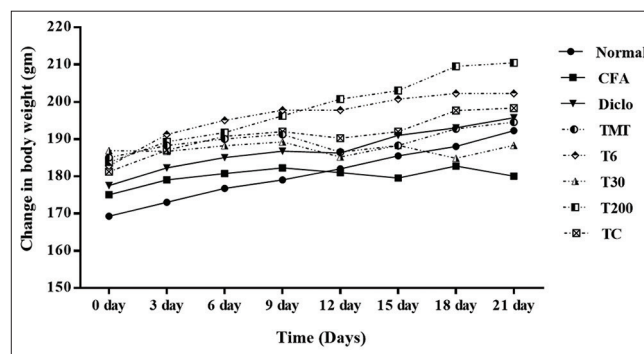


Figure 4: Effect of *Thuja occidentalis* treatments on the body weight changes in the complete Freund's adjuvant-treated rats. Data were expressed as mean \pm standard error of the mean; $n = 4$. Repeated measure analysis of variance followed by Holm-Sidak's multiple comparisons test; $P < 0.05$; $F = 26.51$. *** $P < 0.001$ as compared with CFA group; ### $P < 0.001$ as compared with normal group. CFA: Complete Freund's adjuvant-injected rats; Diclo: standard group; TMT: *Thuja* mother tincture; T6: *Thuja* 6cH; T30: *Thuja* 30cH; and T200: *Thuja* 200cH; TC: *Thuja* crude drug

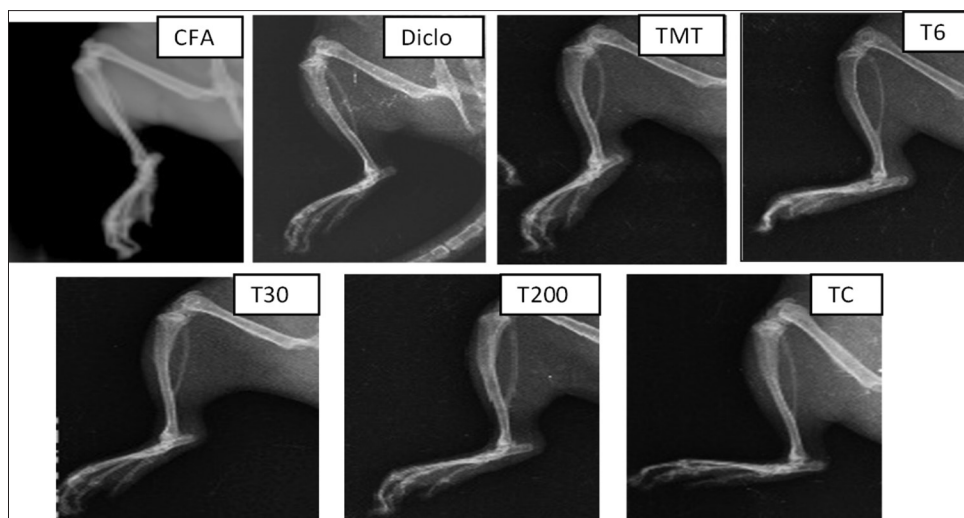


Figure 5: *Thuja* treatments inhibited the radiological changes induced by complete Freund's adjuvant

pro-inflammatory cytokines

CFA injection induced a significant increase in the tissue levels of TNF- α , IL-6 and IL-1 β as compared to the normal group ($P < 0.001$). Treatment with *Thuja occidentalis* reduced such rise in the pro-inflammatory cytokines invariably in all the tested dilutions including MT ($P < 0.001$) as shown in Figure 5. The effects of all the tested dilutions of *Thuja occidentalis* were consistent and significant ($P < 0.001$) as compared to CFA-injected rats [Figure 6].

Effect of *Thuja occidentalis* treatment on the joint changes induced by complete Freund's adjuvant injection

The histological evaluations revealed that there was disruption of bone and joint structures along with severe mononuclear infiltration in the bone joints of the CFA-injected rats. Bone and joint structure in the diclofenac-treated rats had dense bony plates and intact articular cartilages. The joint histology of rats treated *Thuja occidentalis* prevented bone and cartilage destruction [Figure 7]. *Thuja occidentalis* treatment reduced oedema and inflammatory infiltrations into the joint spaces. The histological alterations were scored and are mentioned in Table 2.

DISCUSSION

The leaf extract of *Thuja occidentalis* is used as a source material in the formulation of Homoeopathic dilutions of *Thuja occidentalis*. The chemical constituents of *Thuja occidentalis* have been exhaustively explored and their pharmacological actions are well reported. The extracts and isolated constituents of *Thuja occidentalis* possess diverse biological effects including anti-inflammatory and analgesic,^[18] immunomodulatory,^[19] and antimicrobial.^[20]

Through the present study, we evaluated the effects of different Homoeopathic dilutions of *Thuja occidentalis* against the CFA-induced arthritis in rats. The effect of powdered *Thuja occidentalis* leaves was also studied. We compared the effects of the crude form with the MT, 6cH, 30cH and 200cH dilutions.

Table 1: Effect of *Thuja* on the radiological alterations induced by complete Freund's adjuvant

	CFA	Diclo	TMT	T6	T30	T200	TC
Swelling of tissue around jointed	3	1	2	1	2	2	1
Periarticular bone resorption	2	1	1	1	2	2	2
Periarticular bone erosion	2	1	1	1	2	2	2
Narrowing of the joint space	3	1	1	1	1	2	2

Scoring: 0: Normal; 1: Very mild; 2: Mild; 3: Moderate; 4: Severe; CFA: CFA-injected rats; Diclo: Standard group; TMT: *Thuja* mother tincture; T6: *Thuja* 6cH; T30: *Thuja* 30cH; and T200: *Thuja* 200cH; TC: *Thuja* crude drug; CFA: Complete Freund's adjuvant

Table 2: Effect of *Thuja* on the complete Freund's adjuvant-induced perturbations in the joint histology

Group	Soft tissue changes	Bone changes	Articular changes
Normal	0	0	0
CFA	2	2	2
Diclo	0	1	1
TMT	1	1	1
T6	0	1	0
T30	1	1	1
T200	0	0	1
TC	0	0	1

Scoring: 0: Absent; 1: Mild; 2: Moderate; and 3: Severe; CFA: CFA-injected rats; Diclo: Standard group; TMT: *Thuja* mother tincture; T6: *Thuja* 6cH; T30: *Thuja* 30cH and T200: *Thuja* 200cH; TC: *Thuja* crude drug; CFA: Complete Freund's adjuvant

The dosing schedule and route of administration were selected considering the earlier reports.^[6,9]

The crude form of *Thuja occidentalis* administered at 30 mg/kg/b. i. d doses was found to be less effective in reducing the CFA-induced inflammation in rats. *Thuja occidentalis* has

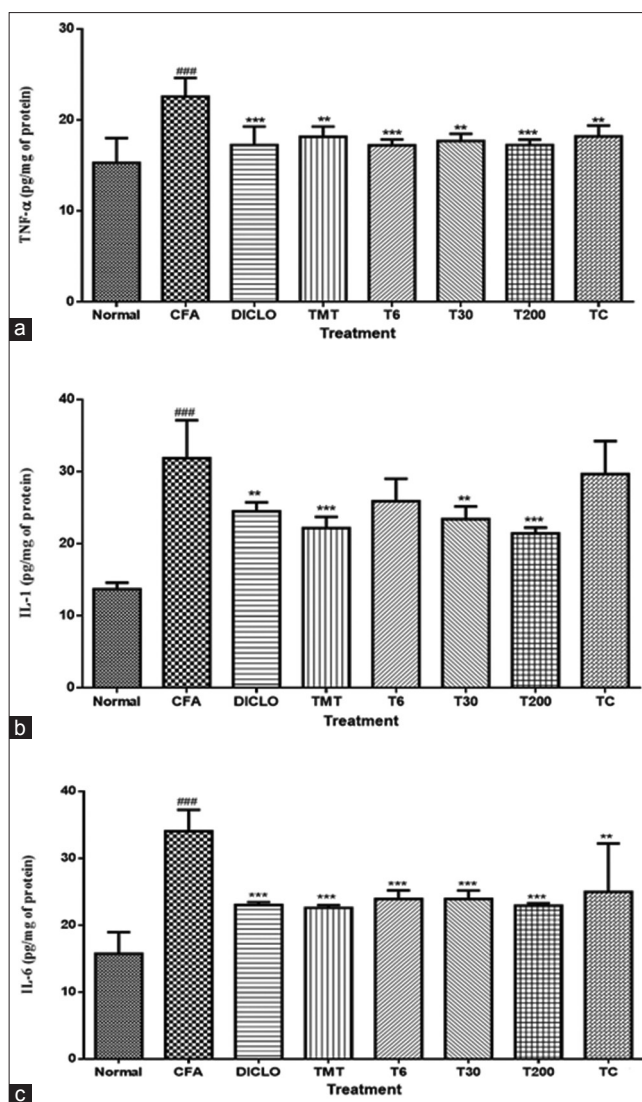


Figure 6: Effect of Homoeopathic dilutions of *Thuja occidentalis* on the release of cytokines in complete Freund's adjuvant-induced arthritis. (a) TNF- α ; (b) IL-1 β ; (c) IL-6. The data were expressed as mean \pm standard error of the mean. The statistical analysis was performed using one-way analysis of variance followed by Bonferroni's multiple comparison test; *** $P < 0.001$; ** $P < 0.01$, * $P < 0.05$ as compared with the complete Freund's adjuvant group; ### $P < 0.001$ as compared with the normal group. * $P < 0.05$ was considered statistically significant. CFA: Complete Freund's adjuvant-injected rats; Diclo: Standard group; TMT: *Thuja* mother tincture; T6: *Thuja* 6cH; T30: *Thuja* 30cH; and T200: *Thuja* 200cH; TC: *Thuja* crude drug

been reported to exert anti-inflammatory effects against the carrageenan-induced paw inflammation in rats at 3, 10 and 30 mg/kg intraperitoneal doses.^[6]

Another study has reported that *Thuja occidentalis* extract inhibits carrageenan-induced paw oedema in rats at 200 mg/kg and 400 mg/kg oral doses. These doses also reduced the acetic acid-induced writhing and increased the formaldehyde-induced paw withdrawal latency.

Janadri and Gowda^[18] indicate that oral administration of the *Thuja occidentalis* extract needs higher doses for induction of anti-inflammatory and analgesic activities as compared to the intraperitoneal doses. In our study, we administered the *Thuja occidentalis* crude form at 30 mg/kg dose and hence, lack of anti-inflammatory activity and anti-hyperalgesic activity may be attributed to this small dose administered orally. The

Homoeopathic dilutions of *Thuja occidentalis* also exerted significant anti-hyperalgesic activity in arthritic rats.

In the present study, we observed the striking ability of Homoeopathic dilutions of *Thuja occidentalis* to reduce the CFA-induced inflammation and analgesia, which indicates that the Homoeopathic dilutions provide advantage over the administration of the crude form by oral route.

In case of pro-inflammatory cytokine concentrations in the CFA-treated rat paw tissue, there was significant decrease in the levels of the pro-inflammatory cytokines. The crude *Thuja occidentalis*-treated groups, however, were less effective in reducing the IL-1 β and IL-6 levels as compared to the Homoeopathic dilutions. The extracts of *Thuja occidentalis* leaves and the polysaccharide fraction are known immunomodulators.

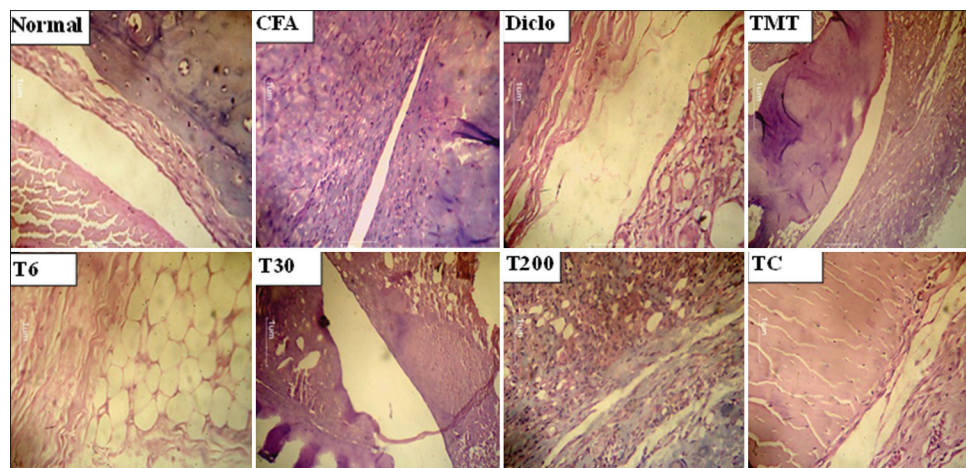


Figure 7: Effect of *Thuja occidentalis* treatment on joint changes induced by complete Freund's adjuvant injection. CFA: Complete Freund's adjuvant-injected rats; Diclo: Standard group; TMT: *Thuja* mother tincture; T6: *Thuja* 6cH; T30: *Thuja* 30cH; and T200: *Thuja* 200cH; TC: *Thuja* crude drug

These effects of *Thuja occidentalis* Homoeopathic dilutions were reproducibly proved using the model of LPS (1 µg/ml)-induced cytokine release from RAW-264.7 cells and human whole-blood culture *in vitro* and also using model of LPS (0.5 mg/kg, i. p.) induced cytokine release and oxidative stress *in vivo* in mice.^[9]

Similar decrease in the pro-inflammatory cytokine levels was observed in the CFA-injected paws tissue of the rats treated with Homoeopathic dilutions of *Thuja occidentalis*. In congruence with these effects on the paw inflammation, hyperalgesia and cytokine release, *Thuja occidentalis* treatments significantly protected the paw joints and surrounding tissues from the CFA-induced alterations. The X-ray and histology images indicate that the crude form and MT of *Thuja occidentalis* were comparatively less efficient in inhibiting the histological perturbations and bone damage induced by CFA.

As a standard drug, we used orally administered diclofenac at 5 mg/kg dose. Chronic administration of diclofenac exerts deteriorating effects on the bone density, and this has been reported earlier in the CFA-induced arthritis model in rats.^[14] Similar effects of diclofenac were evident in the X-ray images captured for the present study. It was observed that the periarticular bone resorption, periarticular bone erosion and the narrowing of the joint spaces were prominent in the rats receiving diclofenac. Whereas, *Thuja occidentalis* Homoeopathic dilutions reversed the CFA-induced arthritic changes.

The inflammation induced by CFA in the contralateral paw indicates the immune-mediated alterations. These secondary lesions provide the extent of immune-mediated inflammatory alterations which are affected by the immunosuppressive agents. The secondary lesions enable the distinction between the anti-inflammatory and the immune suppressive effects of the test drugs. In the present study, we could not find significant difference in the pattern of reduction of paw volume in the CFA-injected and the contralateral paws. Hence, with the present set of data developed by us, it is

not possible to differentiate whether the observed effects of *Thuja occidentalis* dilutions against CFA-induced arthritis involve its anti-inflammatory or immunomodulatory activity. The reduction in the pro-inflammatory cytokines in *Thuja occidentalis*-treated rats, however, indicates that the decreased cytokine levels may involve in the suppression of humoral immune response.

Though the present study does not provide any mechanistic insight into the anti-arthritic effects of the Homoeopathic dilutions of *Thuja occidentalis*, it provides a proof for their efficacy in reducing the characteristic alterations induced by CFA.

CONCLUSION

The major concern in acceptance of homoeopathic medicines is the lack of reproducibility in experimental and clinical proving of therapeutic efficacies. However, a recent upsurge in the evaluations of the Homoeopathic drugs and their dilutions using validated bioassay has instigated renewed interest in the pharmacology of Homoeopathic drugs. The present findings provide evidence to support the anti-arthritic efficacy of Homoeopathic dilutions of *Thuja occidentalis* using validated experimental models of CFA-induced arthritis in rats.

Acknowledgements

We would like to thank Dr Pankaj S. Deore for his kind help in radiological analysis and to the Director, Homeopathic Pharmacopoeia Laboratory, Ghaziabad, India, for generous supply of authenticated sample of crude form of *Thuja*. Thanks are due to Dr Shivang Swaminarayan, Sintex Healthcare, Ahmedabad, India, for supplying the test drugs and kind support for the research work.

Financial support and sponsorship

We acknowledge the financial support received under the Extramural Research (EMR) scheme (23-126/2010-11/CCRH/Tech/EMR/888) from CCRH under the Ministry of AYUSH, Government of India, New Delhi, India.

Conflicts of interest

None declared.

REFERENCES

- Naser B, Bodinet C, Tegtmeier M, Lindequist U. *Thuja occidentalis* (*Arbor vitae*): A review of its pharmaceutical, pharmacological and clinical properties. *Evid Based Complement Alternat Med* 2005;2:69-78.
- Baran D. *Arbor vitae*, a guarantee of health. *Rev Med Chir Soc Med Nat Iasi* 1991;95:347-9.
- Spelman K, Burns J, Nichols D, Winters N, Ottersberg S, Tenborg M. Modulation of cytokine expression by traditional medicines: A review of herbal immunomodulators. *Altern Med Rev* 2006;11:128-50.
- Gohla SH, Haubeck HD, Schrum S, Soltau H, Neth RD. Activation of CD4-positive T cells by polysaccharide fractions isolated from the Cupressaceae *Thuja occidentalis* L. (*Arborvitae*). *Haematol Blood Transfus* 1989;32:268-72.
- Offergeld R, Reinecker C, Gumz E, Schrum S, Treiber R, Neth RD, et al. Mitogenic activity of high molecular polysaccharide fractions isolated from the Cupressaceae *Thuja occidentalis* L. Enhanced cytokine-production by thapopolysaccharide, g-fraction (TPSG). *Leukemia* 1992;6 Suppl 3:189S-91S.
- Silva IS, Nicolau LA, Sousa FB, Araújo S, Oliveira AP, Araújo TS, et al. Evaluation of anti-inflammatory potential of aqueous extract and polysaccharide fraction of *Thuja occidentalis* Linn. in mice. *Int J Biol Macromol* 2017;105:1105-16.
- Linde K, Melchart D. Randomized controlled trials of individualized homeopathy: A state-of-the-art review. *J Altern Complement Med* 1998;4:371-88.
- Fisher P, Scott DL. A randomized controlled trial of homeopathy in rheumatoid arthritis. *Rheumatology (Oxford)* 2001;40:1052-5.
- Mahajan UB, Walke AK, Kardile MV, Goyal SN, Sidharth S, Kundu CN, et al. Anti-inflammatory homoeopathic drug dilutions restrain lipopolysaccharide-induced release of pro-inflammatory cytokines: In vitro and in vivo evidence. *Indian J Res Homo* 2017;11:158-69.
- Oshioka T, Fujii E, Endo M, Tokunaga Y, Shiba N, Hohsho H, et al. Anti-inflammatory potency of dehydrocurdione, a zedoary-derived sesquiterpene. *Inflamm Res* 1998;47:476-81.
- Patil CR, Rambhade AD, Jadhav RB, Patil KR, Dubey VK, Sonara BM, et al. Modulation of arthritis in rats by *Toxicodendron pubescens* and its homeopathic dilutions. *Homeopathy* 2011;100:131-7.
- Kshirsagar AD, Panchal PV, Harle UN, Nanda RK, Shaikh HM. Anti-inflammatory and antiarthritic activity of anthraquinone derivatives in rodents. *Int J Inflamm* 2014;2014:690596.
- Chanchal SK, Mahajan UB, Siddharth S, Reddy N, Goyal SN, Patil PH, et al. *In vivo* and *in vitro* protective effects of omeprazole against neuropathic pain. *Sci Rep* 2016;6:30007.
- Patil KR, Patil CR, Jadhav RB, Mahajan VK, Patil PR, Gaikwad PS, et al. Anti-arthritis activity of bartogenic acid isolated from fruits of *Barringtonia racemosa* Roxb. (*Lecythidaceae*). *Evid Based Complement Alternat Med* 2011;2011:785245.
- Yang J, Cai HD, Zeng YL, Chen ZH, Fang MH, Su YP, et al. Effects of koumine on adjuvant- and collagen-induced arthritis in rats. *J Nat Prod* 2016;79:2635-43.
- Yoon WJ, Ham YM, Kim SS, Sam BS, Moon JY, Baik JS, et al. Suppression of pro-inflammatory cytokines, iNOS, and COX-2 expression by brown algae *Sargassum micracanthum* in RAW 264.7 macrophages. *Eur Asian J Bio Sci* 2009;3:130-43.
- Weichman BM, Chau TT, Rona G. Histopathologic evaluation of the effects of etodolac in established adjuvant arthritis in rats: Evidence for reversal of joint damage. *Arthritis Rheum* 1987;30:466-70.
- Janadri S, Gowda H. Evaluation of analgesic and anti-inflammatory activity of leaves in *Thuja occidentalis* chemically induced animal models. *Adv Pharm J* 2016;1:26-30.
- Bellavite P, Conforti A, Pontarollo F, Ortolani R. Immunology and homeopathy 2. Cells of the immune system and inflammation. *Evid Based Complement Alternat Med* 2006;3:13-24.
- Tsiri D, Graikou K, Poblócka-Olech L, Krauze-Baranowska M, Spyropoulos C, Chinou I, et al. Chemosystematic value of the essential oil composition of *Thuja* species cultivated in Poland-antimicrobial activity. *Molecules* 2009;14:4707-15.

विस्तर चूहों में होम्योपैथिक औषध विलयन थूजा ऑक्सीडेंटलिस द्वारा कम्प्लिट फ्रायड-इंडयूस्ड आर्थराइटिस का कम होना।**सार:**

पृष्ठभूमि: होम्योपैथी में आर्थराइटिस के उपचार में थूजा ऑक्सीडेंटलिस दी जाती है। हमने चूहों में कम्प्लिट फ्रायड एडजुवेंट (सीएफए)-इंडयूस्ड आर्थराइटिस के विरुद्ध थूजा के होम्योपैथिक विलयन की गठिया विरोधी तंत्र का अनुमान लगाया।

सामग्री और विधि: चूहों के दाहिने पिछले पंजे में 0.1 एमएल सीएफए के सब-प्लांटर इंजेक्शन गठिया को प्रेरित (एन=28) किया गया। अपरिष्कृत थूजा की मौखिक खुराक 30 एमजी/कि.ग्रा./बीआईडी और होम्योपैथिक विलयन 0.1 एमएल/बीआईडी थी जो मौखिक रूप से 5 एमएल/कि.ग्रा./प्रतिदिन डिवलोफेनाक के रूप में दी गई। उपचार 24 दिनों तक जारी रहा। गठिया की गंभीरता को साप्ताहिक रूप से पंजे के माप में वृद्धि, यांत्रिक एलाडोनिया और शरीर के वनज में परिवर्तन के रूप में निर्धारित किया गया। 25वें दिन, गठिया ग्रस्त पंजे का एक्स-रे किया गया और प्रो-इन्फ्लेमेटरी साइटोकिन्स तथा हिस्टोलॉजिकल मूल्यांकन के आकलन के अंतर्गत पंजे से बायोप्सी नमूने लिए गए।

परिणाम: थूजा होम्योपैथिक विलयन और इसके अपरिष्कृत रूप ने सीएफए-प्रेरित गठिया घावों के विरुद्ध चूहों की रक्षा की। थूजा के मदर टिंचर, 6 सीएच, 30 सीएच और 200 सीएच विलयनों ने सीएफए-प्रेरित पंजे के माप में वृद्धि को काफी कम कर दिया, यांत्रिक एलाडोनिया को कम किया और पंजे के ऊतक में टीएनएफ-अल्फा और आईएल-1, आईएल-6 के स्तर को भी कम कर दिया। थूजा विलयनों ने सीएफए-प्रेरित जोड़ों संबंधी परिवर्तन, सूजन, कोशीय घुसपैठ और उपास्थि क्षति को कम किया। रेडियोलॉजिकल चित्रों ने संकेत दिया कि थूजा द्वारा उपचार ने सीएफए-प्रेरित जोड़ों का सूजन, अस्थि अपक्षरण और जोड़ों में स्थान सिकुड़ने को कम कर दिया।

निष्कर्ष: हमारे निष्कर्ष सीएफए-प्रेरित गठिया के विरुद्ध थूजा होम्योपैथिक विलयन के गठिया विरुद्ध प्रभावों को प्रमाणित करते हैं और पुष्टि करते हैं कि थूजा के होम्योपैथिक विलयन, विशेष रूप से 6 सीएच ने इसके अपरिष्कृत रूप से अधिक गठिया विरोधी प्रभाव डाला।

Des dilutions homéopathiques de *Thuja occidentalis* atténuent l'arthrite à adjuvant de Freund chez le rat de laboratoire de la lignée wistar

Résumé

Contexte: *Thuja occidentalis* (*Thuja*) est prescrit en homéopathie dans le traitement de la polyarthrite rhumatoïde. Nous avons spéculé sur le mécanisme anti-arthritique des dilutions homéopathiques de *Thuja* contre l'arthrite à adjuvant de Freund (CFA) chez le rat.

Matériels et méthodes: L'arthrite a été provoquée (n=28) par injection sous-plantaire de 0,1 ml de CFA dans la patte postérieure droite des rats. La dose orale de *Thuja* brut était de 30 mg/kg/b.i.d et celle des dilutions homéopathiques de 0,1 ml/b.i.d. Le diclofénac administré par voie orale à raison de 5 mg/kg/jour a servi d'étalon. Les traitements ont duré 24 jours. La sévérité de l'arthrite a été déterminée une fois par semaine par l'augmentation du volume de la patte, l'allodynie mécanique et les modifications du poids corporel. Le 25^{ème} jour, l'imagerie par rayons X des pattes arthritiques a été enregistrée et les échantillons de biopsie extraits des pattes ont été soumis à une estimation des cytokines pro-inflammatoires et à des évaluations histologiques.

Résultats: Les dilutions homéopathiques de *Thuja* et sa forme brute ont protégé les rats contre les lésions arthritiques induites par le CFA. La teinture mère, les dilutions de *Thuja* à 6cH, 30cH et 200cH ont considérablement réduit l'augmentation du volume de la patte induite par le CFA, ont réduit l'allodynie mécanique et ont également réduit les taux d'IL-1, d'IL-6 et de TNF- α dans les tissus de la patte. Les modifications articulaires induites par le CFA, l'œdème, les infiltrations cellulaires et les endommagements des cartilages ont été réduits par les dilutions de *Thuja*. Les images radiologiques ont indiqué que le traitement au *Thuja* réduisait le gonflement des articulations, l'érosion osseuse et le rétrécissement de l'espace articulaire induits par le CFA.

Conclusion: Nos résultats corroborent les effets anti-arthritiques des dilutions homéopathiques de *Thuja* sur l'arthrite induite par le CFA et confirment que les dilutions homéopathiques de *Thuja*, notamment la dilution à 6cH, ont des effets antiarthritiques plus puissants que sa forme brute.

Diluciones del medicamento homeopático *Thuja occidentalis* atenuó la artritis inducida por adyuvante completo de Freund en ratas Wistar

Resumen

Contexto: En homeopatía, *Thuja occidentalis* (*Thuja*) se prescribe en el tratamiento de la artritis reumatoide. Nos hemos planteado el mecanismo antiartrítico de las diluciones homeopáticas de *Thuja* frente a la artritis inducida por adyuvante completo de Freund (ACF) en ratas.

Material y métodos: La artritis se indujo (n=28) por inyección subplantar de 0,1 ml de ACF en la pata trasera derecha de ratas. La dosis oral de *Thuja* cruda fue de 30 mg/kg/ dos veces al día. Las dosis de las diluciones homeopáticas fueron de 0,1 ml/dos veces al día. Una dosis de 5 mg/kg/dos veces al día de diclofenaco por vía oral sirvieron como estándar. Los tratamientos continuaron durante 24 días. La gravedad de la artritis se determinó semanalmente a partir del volumen de la pata, la alodinia mecánica y los cambios en el peso corporal. En el día 25, se tomaron imágenes radiográficas de las patas artríticas y se obtuvieron muestras de biopsias que se sometieron a la valoración de las citoquinas proinflamatorias y evaluaciones histológicas.

Resultados: Las diluciones homeopáticas de *Thuja* u forma cruda protegen las ratas frente a las lesiones artríticas CFA. La tintura madre, así como las diluciones 6CH, 30CH y 200CH de *Thuja* redujeron significativamente el aumento inducido por CFA en el volumen de la pata, redujeron la alodinia mecánica y también redujeron los niveles de IL-1, IL-6 y TNF- α en el tejido. Las diluciones de *Thuja* disminuyeron los cambios articulares inducidos por ACF, los edemas, las infiltraciones celulares y las lesiones cartilaginosas. Las imágenes radiológicas indicaron que el tratamiento con *Thuja* redujo la hinchazón articular inducida por ACF, la erosión ósea y el estrechamiento del espacio articular.

Conclusiones: Nuestros hallazgos sustentan los efectos antiartríticos de las diluciones homeopáticas de *Thuja* frente a la artritis inducida por ACF y confirma que las diluciones homeopáticas de *Thuja*, en particular la dilución 6CH, ejercen un efecto antiartrítico más potente que la forma cruda.

Homöopathische Arzneimittelverdünnungen von *Thuja occidentalis* mildern die durch “Complete Freund’s Adjuvant” (CFA) induzierte Arthritis in Wistar-Ratten

Abstrakt

Hintergrund: *Thuja occidentalis* (Thuja) wird in der Homöopathie bei der Behandlung von rheumatoider Arthritis verschrieben. Wir spekulierten über den antiarthritischen Mechanismus homöopathischer Verdünnungen von Thuja bei der durch “Complete Freund’s Adjuvant” (CFA) in Ratten induzierten Arthritis.

Material und Methoden: Arthritis wurde durch subplantare Injektion von 0,1 ml CFA in die rechte Hinterpfote von Ratten induziert (n = 28). Die orale Dosis von unverdünnter Thuja betrug 30 mg / kg / Tag und die der homöopathischen Verdünnungen 0,1 ml / Tag. Als Standard diente oral verabreichtes Diclofenac mit 5 mg / kg / Tag. Die Behandlungen dauerten 24 Tage. Der Schweregrad der Arthritis wurde wöchentlich mittels Anstieg des Pfotenvolumens, mechanische Allodynie und Änderungen des Körpergewichts bestimmt. Am 25. Tag wurde das Röntgenbild der arthritischen Pfoten gemacht, und die aus den Pfoten entnommenen Biopsieproben wurden auf proinflammatorische Zytokine geschätzt und histologische Bewertungen vorgenommen.

Ergebnisse: Homöopathische Verdünnungen von *Thuja* und ihrer unverdünnten Form schützten Ratten gegen die CFA-induzierten arthritischen Läsionen. Die Urtinktur, die Verdünnungen in C 6, C 30 und C 200 reduzierten den CFA-induzierten Anstieg des Pfotenvolumens signifikant, reduzierten die mechanische Allodynie und verringerten auch die IL-1, IL-6 und TNF- α -Spiegel im Pfotengewebe. CFA-induzierte Gelenksveränderungen, Ödeme, Zellinfiltrationen und Knorpelschäden wurden durch Thuja-Verdünnungen reduziert. Die Röntgenbilder zeigten, dass die Behandlung mit *Thuja* die CFA-induzierte Gelenkschwellung, Knochenerosion und Gelenkraumverengung reduzierte.

Schlussfolgerung: Unsere Ergebnisse belegen die antiarthritischen Wirkungen von *Thuja* in homöopathischen Verdünnungen gegen CFA-induzierte Arthritis und bestätigen, dass die homöopathische Verdünnungen von *Thuja*, insbesondere in C 6 eine stärkere antiarthritische Wirkungen haben als ihre unverdünnte Form.

順勢療法稀釋劑側柏減少完全弗氏佐劑在威斯塔大鼠中誘發的關節炎

摘要

背景: 順勢療法會處方側柏 (*Thuja*) 去治療類風濕性關節炎。我們推測，對於完全弗氏佐劑 (CFA) 在實驗老鼠中誘發的關節炎，順勢療法稀釋劑側柏 (*Thuja*) 有抗關節炎的機制。

材料和方法: 在老鼠的右後爪，透過足底注射0.1毫升的CFA，誘發關節炎 (n=28)。口服側柏 (*Thuja*) 原物質的劑量為30毫克每公斤 (mg/kg)，一日兩次；口服順勢療法稀釋劑側柏 (*Thuja*) 的劑量為0.1毫升，一日兩次；每天口服5毫克每公斤 (mg/kg) 雙氯芬酸 (diclofenac) 則作為標準。治療持續24天。每週透過爪體積的提升、機械性異常疼痛和體重的變化，去決定關節炎的嚴重程度。在第25天，使用X光造影記錄患關節炎的爪，並從爪中抽取活組織，用作估算促進炎症的細胞因子和組織學評估。

結果: 側柏 (*Thuja*) 的順勢療法稀釋劑及其原物質都保護實驗室老鼠免受CFA誘發的關節炎損傷。側柏 (*Thuja*) 的母酊、6cH、30cH和200cH順勢療法稀釋劑均能顯著降低CFA所致的爪體積提升、減低機械性異常疼痛，以及減少爪組織的IL-1、IL-6和TNF- α 的水平。側柏 (*Thuja*) 的順勢療法稀釋劑都減少了CFA誘發的關節改變、水腫、細胞浸潤和軟骨損傷。放射學影像顯示，側柏 (*Thuja*) 治療減少了CFA誘發的關節腫脹、骨侵蝕和關節間隙狹窄。

結論: 我們的研究結果證實了順勢療法稀釋劑側柏 (*Thuja*) 對CFA誘發的關節炎有抗關節炎作用，並且證實了側柏 (*Thuja*) 的順勢療法稀釋劑，尤其是6cH層級，比其原物質具有更強的抗關節炎作用。