

A case report of fibroadenosis alleviated with Homoeopathy

Bharti Wadhwa*

Dr. D. P. Rastogi Central Research Institute of Homoeopathy, Noida, Uttar Pradesh, India

Abstract

Fibroadenosis also known as fibrocystic breast disease constitutes the most frequent benign disorder of the breast causing constant breast pain. The only known treatment in conventional medicine is anti-inflammatory medicines which give temporary relief or surgical excision which results in scarring of breast tissue. The homoeopathic literature shows that cases related to breast lump, mastitis, etc. have been treated successfully; however, no case study/research trial has been documented till date in any peer-reviewed journal. The case reported here is of fibroadenosis in 31-year-old female who was treated successfully with individualised homoeopathic medicine within 6 months with no recurrence. *Phytolacca* was prescribed as a constitutional remedy on the basis of totality of symptoms and after repertorisation. Investigatory procedures such as mammography and ultrasonography were done before and after to record resolution of cysts. The patient has been observed for more than 1 year without recurrence which can be considered as near permanent cure through individualised homoeopathic treatment. Resolution of cysts in this case of fibroadenosis with Homoeopathy can be considered a lead to explore the utility of alternative modes of treatment such as Homoeopathy to give a better therapeutic option for such surgical conditions.

Keywords: Cyst, Fibroadenosis, Fibrocystic disease, Homoeopathy, Lump in breast

INTRODUCTION

Fibroadenosis also known as fibrocystic breast disease is a common benign breast disease characterised by varying degree of fibrocystic changes in the breast tissue. The fibrocystic breast has a dense irregular and lumpy consistency. The most common presenting symptoms are breast pain, tender nodularities which are round and moveable in breasts and sensitive nipples. These symptoms may change throughout the menstrual cycle that is increase in size of the cyst and tenderness before menstrual cycle and usually stop after menopause.^[1,2] Such changes generally affect women of reproductive age group between 20 and 50 years of age. It may be multifocal and bilateral.^[3]

Types of fibrocystic breast disease are:^[2]

- Fibrosis - this is fibrous tissue similar to scar tissue. It feels rubbery, firm or hard to touch
- Cysts - These are fluid-filled sacs. Microscopic cysts are too small to feel. These may get bigger and form macrocysts, which may be 2.5–5 cm (1–2 inch) across.

As per records, fibroadenosis is known to be affecting an estimated 30%–60% of women. Although the exact

pathogenesis of the entity is not clear, hormonal imbalance, particularly estrogen predominance over progesterone, seems to play an important role in its development. Fibrocystic changes comprise both cysts (macro and micro) and solid lesions, including adenosis, epithelial hyperplasia with or without atypia, apocrine metaplasia, radial scar and papilloma.^[3]

Treatment

There is no definite treatment available for fibroadenosis. Removing fluid through fine-needle aspiration may help relieve symptoms of pain or pressure. However, the fluid may return later. In most of the cases, over-the-counter pain relievers such as non-steroidal anti-inflammatory medicines are given to temporarily relieve the pain.^[2] Alternatively, surgery is advised in cases of constant recurrence of pain in spite of pain relievers. However, scarring of breast tissue and recurrence of disease after surgery are the prime cause due to which patients opt for alternative treatments.

***Address for correspondence:** Dr. Bharti Wadhwa,
Dr. D. P. Rastogi Central Research Institute of Homoeopathy, A-1/1,
Sector - 24, Noida, Uttar Pradesh, India.
E-mail: bhartiwadhwa@gmail.com

Access this article online

Quick Response Code:



Website:
www.ijrh.org

DOI:
10.4103/ijrh.ijrh_2_17

This is an open access article distributed under the terms of the Creative Commons Attribution-NonCommercial-ShareAlike 3.0 License, which allows others to remix, tweak, and build upon the work non-commercially, as long as the author is credited and the new creations are licensed under the identical terms.

For reprints contact: reprints@medknow.com

How to cite this article: Wadhwa B. A case report of fibroadenosis alleviated with Homoeopathy. *Indian J Res Homoeopathy* 2017;11:196-202.

Diagnosis

Mammography and ultrasonography (USG) are done to evaluate a mass in a patient with fibrocystic condition. Mammography is usually the first imaging test to be done in women above 35 years of age when unusual breast changes are detected during a physical examination. USG alone may be used in women under 30 years of age.^[4] Ultrasound breasts are commonly performed in conjunction with mammography for confirmation as they produce clear images of the breast and helps distinguish between fluid-filled breast cysts and solid masses.

Prognosis

As per conventional treatment, pain, tenderness and cyst formation may occur at any time until the menopause, when symptoms usually subside, except in patients receiving hormonal replacement therapy.^[4]

CASE REPORT

A 31-year-old married female presented in outpatient department (OPD) of Dr. D.P. Rastogi Central Research Institute of Homoeopathy, Noida, with complaint of burning pain in the breasts for 4–5 months which aggravated on touch, pressure and before menses. Pain was occasionally

burning in character. Ultrasound breasts [Figure 1] and mammography [Figure 2] revealed fibroadenosis in both breasts. She had been advised anti-inflammatory and pain killer medicines in case of acute pain, which gave her temporary relief and was asked to opt for surgery. However, the patient did not want to go for surgery with fear of scarring and recurrence in the future. Thus, she opted for homoeopathic treatment. Fine-needle aspiration cytology was also advised; however, the patient was not willing to go for any invasive test.

On examination, cystic swellings were felt in periareolar region of both breasts.

Apart from the main presenting complaints, she also reported about pain in both knee joints for 1 month which was aggravated on continuous walking. Thermal reaction was chilly and there was aversion to sour/acidic food. Thirst for small quantities of water at shorter intervals was present.

Following symptoms were considered for repertorisation:

- Fibrocystic tumours
- Pain in breasts on touch
- Pain in breasts before menses

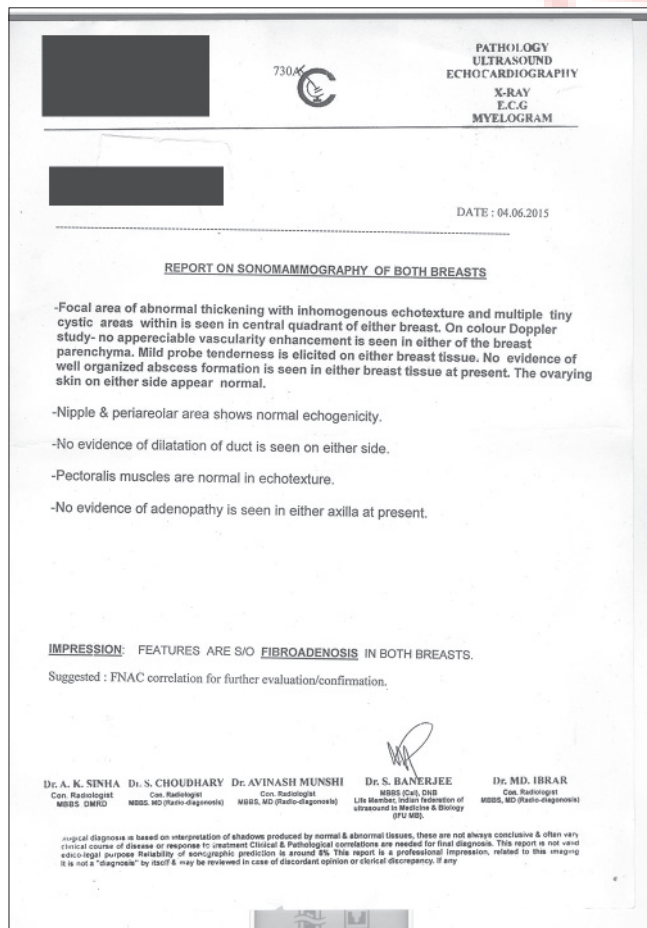


Figure 1: Ultrasound breasts report at the beginning of treatment

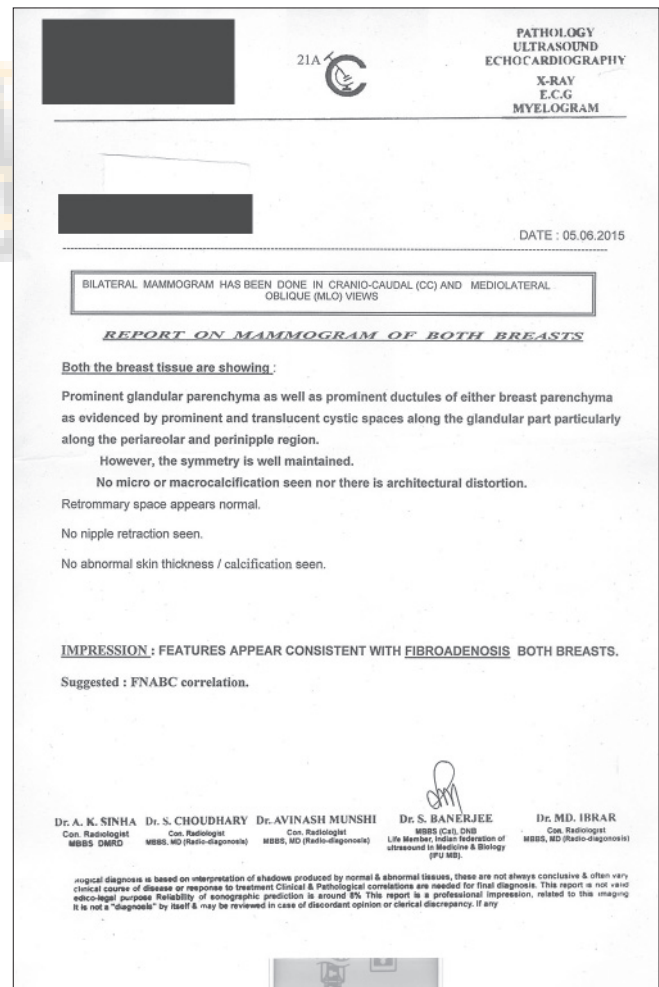


Figure 2: Mammography report at the beginning of treatment

- Burning pain in breasts
- Aversion to sour food
- Pain in knees, agg. walking
- Thirst for small quantities of water at frequent intervals
- Thermal reaction - chilly.

Repertorisation was done using RADAR 10 software^[5] (Synthesis repertory 9.0 version), Archibel Homoeopathic software. Repertorial result is shown in Table 1.

Intervention

First prescription (2 September 2015)

Phytolacca 30/tds/1 week followed by Placebo 30/tds/1 week.

Basis of prescription

Medicine selected as per repertorisation and in consultation with Homoeopathic Materia Medica was *Phytolacca*. Furthermore, fibrocystic disease, pain aggravation on touch and burning pains which were predominant symptoms were covered by *Phytolacca*; therefore, *Phytolacca* was prescribed. In this case, as there was acute pain and tenderness. Therefore, medicine was prescribed in 30C thrice a day for a week. In subsequent follow-ups, potency was changed based on assessment of symptom/sign improvement as mentioned in Table 2.

Follow-up

Follow-up of patient was assessed fortnightly or earlier as per the requirement. The patient adhered to the medical intervention even after initial aggravation of symptoms after raising the potency from 30C to 200C.

On examination on 7 November 2015, the cystic swellings in subareolar region were found with mild tenderness. Thus, the potency was changed from centesimal to 50 Millesimal (LM) which brought overall improvement. USG was repeated after 6 months of treatment which showed complete resolution of fibroadenosis [Figure 3]. Patient was prescribed SL 30 three times a day for 6 months as there was complete disappearance of symptoms.

Details of follow-ups are given in Table 2.

RESULTS

Patient improved symptomatically gradually after prescription of *Phytolacca* in 50 Millesimal (LM) potencies. There was a significant reduction in pain along with cystic swellings which resolved completely over 6 months duration. Ultrasound breasts done after 6 months at Dr. D.P. Rastogi

Table 1: Repertorisation chart

	Phyt	con	clm	bell	lvc	phos	bry	lach	pull	thul	infr	ars	calc	lecl	chin	coloc	sulph	me	nat	all	kali	symp	kali	aur	calc	caust	cham	thust	con
1. GENERALS - COLD - agg.	2	2	1	2	3	3	2	1	2	2	1	3	3	2	3	2	2	2	3	2	1	3	2	3	3	1	3	2	
2. GENERALS - FOOD and DRINKS - sour food, acids - aversion	-	2	1	2	1	-	-	-	-	-	-	-	-	1	2	-	1	-	1	-	-	-	-	-	-	-	-	2	
3. STOMACH - THIRST - small quantities, for - often, and	-	-	-	2	1	-	1	1	-	3	-	2	2	2	-	-	-	-	-	-	-	-	-	-	-	-	1	-	
4. CHEST - TUMORS - Mammae - fibrocystic	1	-	-	-	1	-	1	-	-	-	-	-	-	-	-	-	-	-	1	-	-	-	-	-	-	-	-	-	
5. CHEST - INDURATION - Mammae - painful on touch	2	1	1	-	-	-	-	1	1	-	-	-	-	-	-	-	-	-	-	-	-	-	-	-	-	-	-	-	
6. CHEST - PAIN - burning - Mammae	2	1	-	1	2	2	1	1	-	2	2	1	-	-	2	-	2	-	-	-	1	-	-	1	-	-	-	-	
7. CHEST - INDURATION - Mammae - menses - before	-	2	-	-	-	1	-	-	-	-	-	-	-	-	-	-	-	-	-	-	-	-	-	-	-	-	-	-	
8. EXTREMITIES - PAIN - Knee	2	2	1	2	2	1	2	2	1	2	2	3	2	2	2	2	2	2	1	1	1	3	3	3	3	3	3	2	
9. EXTREMITIES - PAIN - Knee - walking	-	1	-	-	2	2	-	1	1	-	2	3	-	2	-	1	1	-	1	1	2	2	-	1	3	-			

Table 2: Follow-up

Date of visit	Symptoms	Medicine with doses, repetition	Justification
19/09/2015	Burning pain in breasts decreased but was present on pressure, knee pain-same	<i>Phytolacca</i> 30C/tds/1 week, followed by SL 30C/tds/1 week	There was mild relief in pain, so same medicine was repeated again
31/10/2015	Pain in breasts and knee did not improve further	<i>Phytolacca</i> 200C/3 dose SL 30/tds/1 weeks	There was no further improvement in symptoms
07/11/2015	Pain in breast increased. There was constant pain and heaviness in breast even without touch and pressure knee pain-same	<i>Phytolacca</i> 0/1/bd/2 week	There was aggravation of symptoms after 200 potency, so frequent repetition in minimum potency was required. Thus, LM potency was selected
01/12/2015	Pain in breast was much better. There was also improvement in knee pain	<i>Phytolacca</i> 0/2/bd/2 week	There was improvement in symptoms; so next higher LM potency was prescribed
19/01/2016	Pain in breast was much better but not completely relieved. Pain was absent on touch but was present on pressure and before menses (in decreased intensity) knee pain-much better	<i>Phytolacca</i> 0/3/bd/2 week	There was marked improvement in symptoms but not complete relief. Therefore potency was further raised
02/02/2016	Patient was much better. No pain in breast for 2 weeks Mild knee pain due to over exertion Advice: USG breast was advised to assess the status of disease	SL 30/tds/1 week	There was complete disappearance of symptoms. So placebo was prescribed
20/02/2016	There was no pain in breast for the last 1 month. Pain in knee was also much better	SL 30/tds/1 month	USG breasts [Figure 3] showed normal study with complete resolution of fibroadenosis
10/03/2016	There was no pain in breast and knee joints for the last 2 months	SL 30/tds/1 month	Relief in symptoms and no signs present, so SL was prescribed USG breasts [Figure 4] done outside reconfirmed normal scan with complete disappearance of fibrocystic changes
15/04/2016	There was no recurrence of symptoms; so patient was advised to report in OPD at 1-3 months interval	SL 30/tds/2 months	There was no recurrence of symptoms; so SL was prescribed
20/06/2016	There was no recurrence of symptoms	SL 30/tds/2 months	There was no recurrence of symptoms; so SL was prescribed
25/08/2016	No recurrence has been reported in the last 5-6 months interval. Patient was advised to report in case of any recurrence of symptoms	SL 30/tds/2 months	There was no recurrence of symptoms; so SL was prescribed

USG: Ultrasonography; OPD: Outpatient department; LM: 50 Millisemal; SL: Sac lac- blank pills

Central Research Institute of Homoeopathy, Noida, revealed normal study with complete resolution of cysts. Ultrasound was repeated after 1 month again from another laboratory to confirm the findings which also revealed normal scan [Figure 4].

DISCUSSION

It has been well known that conventional treatment can help relieve the complaints associated with fibroadenosis and there are chances of recurrence, scarring, etc. whereas in this case treated with individualised homoeopathic medicine has not only brought relief in the signs and symptoms but also no recurrence has been reported in 1-year duration of follow-up.

Phytolacca is frequently used and supposed to be a specific remedy for glands, especially mammary glands.^[6] As seen clinically, *Phytolacca* is useful in majority of cases presenting with mastitis, breast tumours, abscesses and even cancer of breast. However, in this case, after case history recording, repertorisation and consultation with Materia Medica, *Phytolacca* was prescribed on the basis of individualisation and totality of the symptoms and not just as a specific remedy. As

a result, there was complete recovery in breast pain along with resolution of cysts. Apart from the presenting complaints of pain in breasts, associated symptoms such as pain in both knee joints also improved as medicine was given on constitutional basis. Thus, this case record reflects that any constitutional remedy having specific organ affinity will surely bring complete recovery and at a faster pace.

The patient showed improvement in beginning which proved correct selection of medicine, but there was aggravation of symptoms after raising the potency. The acuteness of pain in breasts required repetition of medicine but in much milder dosage. Thus, LM potency was chosen in accordance to the directions of Dr. Hahnemann in the 6th edition of Organon. 'Thus, in chronic diseases, every correctly chosen homoeopathic medicine, even those whose action is of long duration, may be repeated daily for months with ever increasing success'.^[7]

The patient showed marked improvement in symptoms when medicine was repeated frequently in LM potency. After 3 months of treatment with LM potency, there was complete amelioration in symptoms. This shows the importance of dose and repetition in achieving complete cure. USG was done after 6 months

Wadhwa: Fibroadenosis case

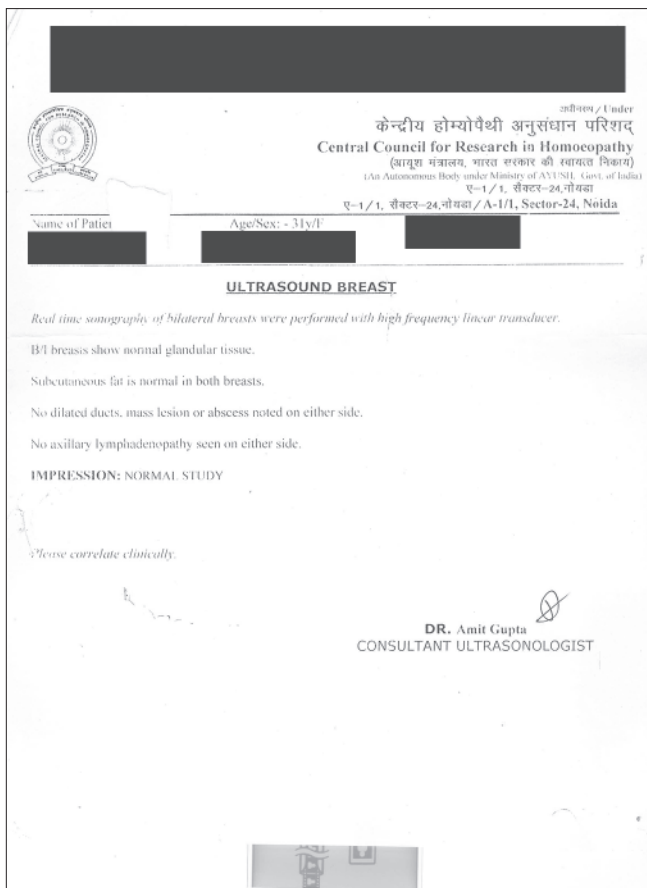


Figure 3: Ultrasound breasts report after six months of treatment

showed normal scan with complete resolution of cysts. This clearly shows homoeopathic approach with proper selection of medicine, potency and repetition of dosage is more scientific with promising results as compared to conventional medicine.

CONCLUSION

Homoeopathy is a specialised system of medicine which treats the patient as a whole and not just the disease. Non-recurrence of complaints for 1 year and disappearance of fibroadenosis on USG within 6 months are a documentary evidence of complete resolution with Homoeopathy in the light of modern medicine.

Acknowledgement

The author expresses profound gratitude to Dr. B. S. Arya, Officer In-Charge and Dr. Pritha Mehra, Scientist-2, Dr. D. P. Rastogi Central Research Institute of Homoeopathy, Noida, for their constant support and guidance in drafting this article. Cooperation of the patient is also gratefully acknowledged who came for regular follow-ups during the treatment and expressed her willingness to share this case for academic purpose.

Financial support and sponsorship

Nil.

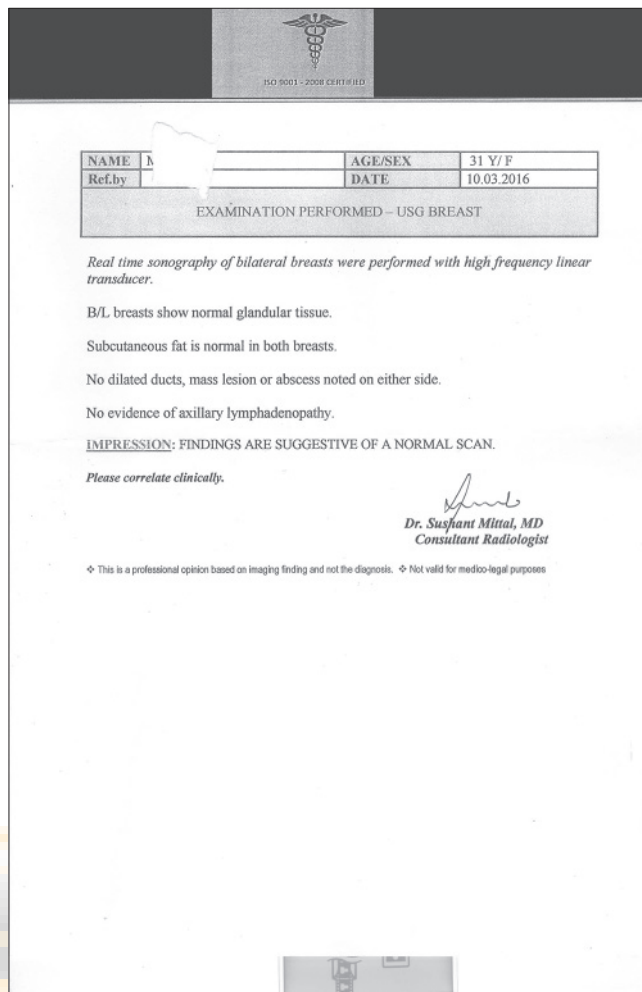


Figure 4: Ultrasound breasts report after seven months of treatment

Conflicts of interest

None declared.

REFERENCES

1. World Health Organization. International Classification of diseases 2010. Available from: <http://www.icd10data.com/ICD10CM/Codes/N00-N99/N60-N65/N60->. [Last accessed on 2016 Dec 26].
2. American Congress of Obstetricians and Gynecologists: "Fibrocystic Breast Changes." WebMD, LLC 2016. Available from: <http://www.webmd.boots.com/women/guide/fibrocystic-breast-disease>. [Last accessed on 2016 Dec 26].
3. Guray M, Sahin AA. Benign breast diseases: Classification, diagnosis, and management. *Oncologist* 2006;11:435-49.
4. Papadakis MA, McPhee SJ, Rabow MW. *Current Medical Diagnosis & Treatment*. 46th Edition; The McGraw-Hill Companies, Inc; 2007.
5. Schroyens F. RADAR 10, Synthesis 9.0(SE90), Archibel Homoeopathic Software.
6. Kaveh AA, Kabirian A, Mashayekhi M, Danandeh R, Bahraminia F, Kochakzade H. Evaluation of clinical remission and serum globulin level in clinical and subclinical mastitis of Holstein cows before and after using of homeopathic medicine *Phytolacca decandra* Pelagia Research Library *European Journal of Experimental Biology*, 2012; 2:1957-61.
7. Hahnemann S. *Organon of Medicine*. 6th ed. India: B. Jain Publishers (P) Ltd.; 2006. p. 205.

होम्योपैथी द्वारा फाइब्रोएडीनोसिस उपचार पर एक केस रिपोर्ट

सार

फाइब्रोएडीनोसिस को फाइब्रोसाइटिस्टिक स्तन रोग के रूप में भी जाना जाता है जो लगातार स्तन दर्द के साथ, स्तन के सबसे अधिक सौम्य विकार का कारण बना हुआ है। परंपरागत चिकित्सा में इसका एक मात्र ज्ञात उपचार सुजन विरोधी औषधियाँ हैं जो अस्थायी राहत देती हैं या शल्य चिकित्सा है जिसके परिणामस्वरूप स्तन ऊतकों में घाव का निशान पड़ जाता है। होम्योपैथिक साहित्य में यह पता चलता है कि स्तन गांठ, स्तन की सूजन, आदि से संबंधित मामलों का होम्योपैथी द्वारा सफलतापूर्वक उपचार किया गया है हालांकि, इस प्रकार के अध्ययन / अनुसंधान परीक्षण का कोई मामला किसी भी पियर रिव्यूड जर्नल में अब तक दर्ज नहीं किया गया है। संबंधित मामला फाइब्रोएडीनोसिस से ग्रस्त 31 वर्षीय महिला का है जहा बिना पुनरावृत्ति के 6 महीने के भीतर व्यक्तिगत होम्योपैथिक औषधि के साथ सफलतापूर्वक इलाज किया गया। पुनर्संरचना के बाद तथा लक्षणों की संपूर्णता के आधार पर फाइटोलेका को एक संवैधानिक उपचार के रूप में निर्धारित किया गया। रसोली के उपचार को रिकॉर्ड करने से पहले और बाद में मैथोग्राफी और अल्ट्रासोनोग्राफी जैसी अन्वेषक प्रक्रियाएं की गईं। मरीज की, बिना पुनरावृत्ति के 1 साल से अधिक समय के लिए जांच की गई, जिसे व्यक्तिगत होम्योपैथिक उपचार के माध्यम से लगभग स्थायी उपचार माना जा सकता है। होम्योपैथी के साथ फाइब्रोएडीनोसिस के इस मामले में रसोली के उपचार की ऐसी शल्य परिस्थितियों के लिए बेहतर चिकित्सीय विकल्प देने के लिए होम्योपैथी उपचार के वैकल्पिक माध्यम की उपयोगिता का पता लगाया जा सकता है।

Linderung einer Fibroadenose durch Homöopathie: ein Fallbericht

Abstrakt

Fibroadenose auch als zystische Mastopathie bekannt, stellt die häufigste gutartige Mamaerkrankung mit permanenten Mamaschmerzen dar. Die einzig bekannte Behandlungsmöglichkeit in der traditionellen Medizin besteht in der Verabreichung entzündungshemmender Medikamente, die vorübergehende Linderung bringen oder die chirurgische Exzision, die zur Narbenbildung des Brustgewebes führt. In der homöopathischen Literatur finden sich Fälle, die im Zusammenhang mit Mamaknoten, Mastitis usw. stehen und erfolgreich behandelt wurden. Bis dato wurde allerdings dazu noch keine Fallstudie/klinische Studie in einem Peer-Review-Journal publiziert. Hier wird der Fall einer zystischen Mastopathie bei einer 31-jährigen Frau, die erfolgreich mit einer individuellen, homöopathischen Arznei innerhalb von sechs Monaten ohne eine Gabenwiederholung behandelt wurde, vorgestellt. *Phytolacca* wurde als Konstitutionsmittel auf der Grundlage der Symptomentotalität und nach Repertorisation verordnet. Klinische Befunderhebungen wie Mammographie und Sonographie (USG) wurden vor und nach der Behandlung durchgeführt, um die Auflösung der Zysten zu dokumentieren. Bei der Patientin wurde für mehr als ein Jahr kein Rezidiv beobachtet, was als eine annähernde dauerhafte Heilung durch eine individuelle, homöopathische Behandlung angesehen werden kann. Die Auflösung der Zysten durch die homöopathische Behandlung können als Hinweis angesehen werden, die Nützlichkeit alternativer Behandlungsmethoden, wie die Homöopathie zu erforschen, um eine bessere therapeutische Möglichkeit für üblicherweise chirurgisch behandelte Zustände zu bieten.

Informe de un caso de fibroadenosis aliviada con homeopatía

Resumen

La fibroadenosis, también conocida como Enfermedad fibroquística de la mama, constituye el trastorno benigno más frecuente de la mama que causa un dolor mamario constante. El único tratamiento conocido en medicina convencional son los antiinflamatorios que procuran un alivio transitorio, o la escisión quirúrgica que da lugar a la formación de cicatrices en el tejido mamario. En la bibliografía homeopática, se presentan casos relacionados con formaciones mamarias, mastitis, etc. que se han tratado con éxito. No obstante, hasta la fecha no se ha documentado ningún ensayo de investigación o estudio de casos en ninguna revista revisada por pares. El caso clínico referido en este artículo es una fibroadenosis en una mujer de 31 años de edad que fue tratada satisfactoriamente con un medicamento homeopático individualizado en 6 meses sin presentar recurrencias. Se prescribió *Phytolacca* como remedio constitucional a partir de la totalidad de los síntomas y de la repertorización. Se efectuaron mamografías y ecografías antes y después del tratamiento para registrar la resolución de los quistes. El seguimiento de la paciente abarca más de un año sin recurrencias, lo que puede considerarse como curación casi permanente gracias al tratamiento homeopático individualizado. Este caso ilustra que la homeopatía puede ser una mejor opción terapéutica para tales condiciones quirúrgicas.

Un rapport de cas de fibroadénose atténué avec l'homéopathie

Résumé

La fibroadénose également connue sous le nom de maladie fibrokystique du sein constitue le trouble bénin le plus fréquent du sein provoquant une douleur constante au sein. Le seul traitement connu dans la médecine conventionnelle consiste à prescrire les médicaments anti-inflammatoires qui donnent un soulagement temporaire ou une excision chirurgicale qui entraîne la cicatrisation du tissu mammaire. La littérature homéopathique montre que les cas liés aux masses dans le sein, la mastite, etc. ont été traités avec succès ; cependant, aucune étude de cas/essai de recherche n'a été documenté jusqu'à ce jour dans une publication approuvée par des collègues. Le cas signalé ici concerne la fibroadénose chez une femme âgée de 31 ans qui a été traitée avec succès par des médicaments homéopathiques personnalisés dans les 6 mois suivant la manifestation de la maladie sans récurrence de celle-ci. La *Phytolacca* a été prescrite comme remède constitutionnel sur la base de l'ensemble des symptômes et après la répertorisation. Les procédures d'investigation telles que la mammographie et l'échographie ont été effectuées avant et après la prise de médicaments pour constater la résolution des kystes. La patiente a été observée pendant plus d'un an sans que la maladie ne se remanifeste, ce qui peut être considéré comme un traitement quasi-permanent par le biais d'un traitement homéopathique personnalisé. Ce cas illustre que l'homéopathie peut être une meilleure option thérapeutique pour de telles conditions chirurgicales.

順勢療法緩解的纖維腺病變之病例報告

摘要

纖維腺病變又稱乳房纖維囊腫，是引起持續性乳房疼痛最常見的乳房良性疾病。常規藥物中唯一已知的治療方法是抗炎藥物，這種藥物只可臨時緩解，或以手術切除，但會使乳房組織結疤。順勢療法文獻顯示，有成功治療乳房腫塊、乳腺炎……等等的個案，但直至現在均沒有案例分析／研究試驗於同行評審中被記錄。這裡有一個成功個案，一名31歲患有纖維腺病變的女性被成功治癒，她在接受個人化順勢療法藥物治療後的6個月內也沒有復發。根據她的整體症狀和療劑彙集分析對照後，處方了體質療劑商陸 (*Phytolacca*)。在研究過程的前後，會進行乳房攝影術&超音波檢查 (USG)，以記錄囊腫的消失。已經觀察病人超過1年以上都沒有復發，因此可被認為這是被順勢療法個人化治療至接近永久性治癒。這個個案可顯示，對於這種外科疾病順勢療法可能是更好的治療選擇。