

## CASE REPORT

# A case of Deep Vein Thrombosis with Postthrombotic syndrome cured by Homoeopathic therapy

Gyandas G. Wadhvani\*

### ABSTRACT

A 46-year-old woman consulted for right-sided deep vein thrombosis in external iliac, common femoral, superficial femoral and popliteal veins with extension along with postthrombotic syndrome. After homoeopathic consultation, she was prescribed *Argentum nitricum* in ascending LM potencies. Symptomatic relief was reported within 2 weeks of treatment, and gradually the quality of life improved after simultaneous reduction in pain due to other complaints of sciatica and osteoarthritis. Venous Doppler studies repeated a year later showed complete resolution of the medical condition with homoeopathic drug therapy alone. The physical examination also revealed a reduction in limb circumference.

**Keywords:** *Argentum nitricum*, Deep vein thrombosis, Homoeopathy, LM potency, Postthrombotic syndrome, Wells score

### INTRODUCTION

Deep vein thrombosis or deep venous thrombosis (DVT) is the formation of a blood clot (thrombus) in a deep vein – the calf, thigh, and pelvic veins being more commonly involved than others. The condition is often symptomless, and patients may present with nothing else but swelling and sometimes pain (more appropriately, a heavy ache) and tenderness. The most common complication associated with DVT is fragments of the clot lodging in the lungs (pulmonary embolism) or other organs, which may threaten life. Together, DVT and pulmonary embolism constitute a single disease process known as venous thromboembolism.<sup>[1-4]</sup> In some patients, long-term symptoms develop in the affected arm or leg, which include pain, swelling, warmth, redness or discoloration, and dilatation of superficial veins. This condition is known as a postthrombotic syndrome (PTS) and in severe cases it

may lead to ulceration of the affected part. The overall incidence of a venous thrombosis is 1–2/1000 persons per year and is exponentially related to increasing age as that alters the blood composition to favor clotting.<sup>[5]</sup> It is a multicausal disease, caused by the interplay of various genetic and acquired risk factors most of them being associated with immobilization and hypercoagulability. Individuals suspected of having DVT may be assessed using a clinical prediction rule such as the Wells score system.<sup>[6]</sup> Doppler ultrasonography is now the standard golden tool

This is an open access article distributed under the terms of the Creative Commons Attribution-NonCommercial-ShareAlike 3.0 License, which allows others to remix, tweak, and build upon the work non-commercially, as long as the author is credited and the new creations are licensed under the identical terms.

For reprints contact: [reprints@medknow.com](mailto:reprints@medknow.com)

**How to cite this article:** Wadhvani GG. A case of deep vein thrombosis with postthrombotic syndrome cured by homoeopathic therapy. *Indian J Res Homoeopathy* 2015;9:267-73.

#### Access this article online

**Website:**

[www.ijrh.org](http://www.ijrh.org)

**DOI:**

10.4103/0974-7168.172867

**Quick Response Code:**



Directorate of Ayush  
(Homoeopathic Wing) Government  
of National Capital Territory of  
Delhi, New Delhi, India

**\*Address for correspondence:**

Dr. Gyandas G. Wadhvani,  
101, Sidhartha Enclave,  
New Delhi - 110 014, India.  
E-mail: [homoeopathygyan@gmail.com](mailto:homoeopathygyan@gmail.com)

Received: 09-01-2015

Accepted: 11-12-2015

for diagnosis of DVT. Serologically, the D-dimer test because of its high sensitivity assists with excluding the diagnosis or signaling a need for further testing in patients suspected of having thrombotic disorders.<sup>[7]</sup>

It is generally believed that DVT is preventable to a great extent as a majority of risk factors are modifiable. Being active is of prime importance as walking, and calf exercises reduce venous stasis because leg muscle contractions compress the veins and pump blood up toward the heart. Avoiding weight gain and smoking are also important measures. In immobile individuals, physical compression method viz., bandaging the whole limb with crepe or using a graduated compression stocking improves blood flow. The treatment in DVT is aimed at minimizing the local extension of the disease, reducing the risk of recurrence after the initial episode, and preventing the complications. Patients may be treated with anticoagulants, usually low-molecular-weight heparin and a Vitamin K antagonist such as Warfarin. More severe cases may require surgical intervention or thrombolysis. Anticoagulation is used only in high-risk scenarios as it carries a risk of major hemorrhage.<sup>[1-4]</sup> The homoeopathic physicians, on the other hand, never administer a remedy for DVT, PTS or for any disease name or diagnosis. The remedy selection is solely governed by the symptoms of the patient who comes with a diseased condition, or, more appropriately, the reaction of the individual in question to any given disease entity. Thus, the homoeopathic therapeutic approach is fundamentally different from conventional medicine. A few clinical case summaries are available online showing successful homoeopathic treatment of DVT.<sup>[8,9]</sup>

We share a diagnosed case of DVT with PTS, successfully treated with a single homoeopathic drug, over a period of a year.

## CASE REPORT

A 46-year-old woman, a teacher by profession, consulted on 31-05-2013 for DVT and PTS. She was of a short stature, heavy built, with a prominent malar flush, dark eyes, colored hair, and deeply scarred right face and trunk (due to burns). While awaiting her turn, it could be seen that she was the only patient looking at her watch frequently. Her anxious (viz., sitting leaning forward, wringing of hands) and hurried temperament were evident throughout the consultation.

Her complaints had started about 10 years earlier with pain in the right thigh. The pain was relieved by hot fomentation and aggravated by movement and draught of air. There was also an accompanying sensation of heat in bilateral thighs. Swelling in right lower limb had been present for last 6 years.

She was also diagnosed with hypothyroidism and dyslipidemia during routine investigations about 6 years back for which she is taking Thyronorm 50 mcg (thyroxine sodium) and Storvas (atorvastatin).

An year later she developed swelling and pain in the left knee, soon after the demise of her mother. MRI scan revealed left lateral ligament tear and advanced osteoarthritis, and she has advised physiotherapy sessions, which provided temporary relief.

She also experienced recurring episodes of anxiety and restlessness over last few years. They mostly occur when her husband or son were away.

Four years back she also started experiencing pain in left hip radiating down back of left lower limb, which was diagnosed as sciatica. Physiotherapy sessions provided some relief in the pain.

Over last 2 years, she was also having numerous cramps in calves along with recurrent episodes of twisting of the right ankle. Her quality of life suffered as she was unable to carry out daily chores due to all these complaints.

## Past History

- While she was a teenager, fire broke out at home, and the right half of her face and trunk got burnt
- She had undergone surgery for a perforated right tympanic membrane and an anal fissure about 8–9 years back.

## Personal History

- Menses: Regular
- G1P1A0; she has a 23-year-old son who was delivered by lower segment caesarean section
- Vegetarian diet; no addictions
- Conducts tutorial classes in Hindi and Sanskrit.

## Family History

Sister: Hypothyroidism.

## Generals

- Appetite - Poor; feels nauseous when looks at food
- Desire - Sweet lassi + + + (a sweetened yoghurt); sweets + + + - especially strong sweets viz., besan barfi (an Indian traditional sweetmeat);

samosa ++ (a traditional Indian deep fried potato preparation)

- Thermal reaction - Prefers winters/cool environment; needs open air - even in winters cannot bear to have all windows/doors shut.

### Life and Accessory Circumstances

Born and brought up in a middle-class family and has two sisters. After she got burnt (teenage), she avoided socializing due to the visible scarring. Later, she had an arranged marriage. Though husband has always been domineering he was also caring toward her and attending all her needs. She has always been inclined toward teaching and has been conducting tutorial classes even after marriage, which not only keeps her happy but also gives her a sense of independence and productivity. Son is married and settled in another town since last year.

### Mind and Disposition

- Hurried, worried, and apprehensive (not just observed, but also verified from husband)
- Very particular about reaching for any appointment before scheduled time- even finishes the study course of all her students well before term is over
- Fearful of thunderstorm
- Exceedingly conscious about her physical appearance (after scarring)
- Conscientious about her profession/teaching.

### Physical Examination

- Blood pressure: 114/76 mm Hg
- Weight: 76 kg
- Tongue: Moist, flabby, deep central fissure
- O/A: Normal breath sounds
- O/E: Right lower limb warmer than left
- Homan's sign: Positive on Right side
- Edema: Positive bilateral, R>L
- Straight leg raise and Lasegue's: Positive on left side at 45°
- Limb measurement [Table 1]
- Wells score for DVT: 5 (Wells score pretreatment).

### Investigations Undergone (Pre-treatment)

28-5-13: Right lower limb venous Doppler: Features suggestive of deep vein thrombosis involving right external iliac vein, common femoral, superficial femoral and popliteal veins with extensions [Figure 1].

### Analysis

The anxious, hurried and apprehensive disposition (especially regarding time) was observable throughout the homoeopathic consultation, and, was easily verified from the spouse. Moreover, the

instant response of patient when asked about food preferences helped us to qualify her preference for sweets 3+. Another marked feature in the case was a marked "desire for open air," even in extreme winters.

The case seemed to demand a mixed miasmatic (predominantly syphilitic) remedy and *Argentum nitricum* was selected for the patient.

Considering the seriousness of pathology, the remedy had to be administered frequently. Hence, the LM potency scale was selected.

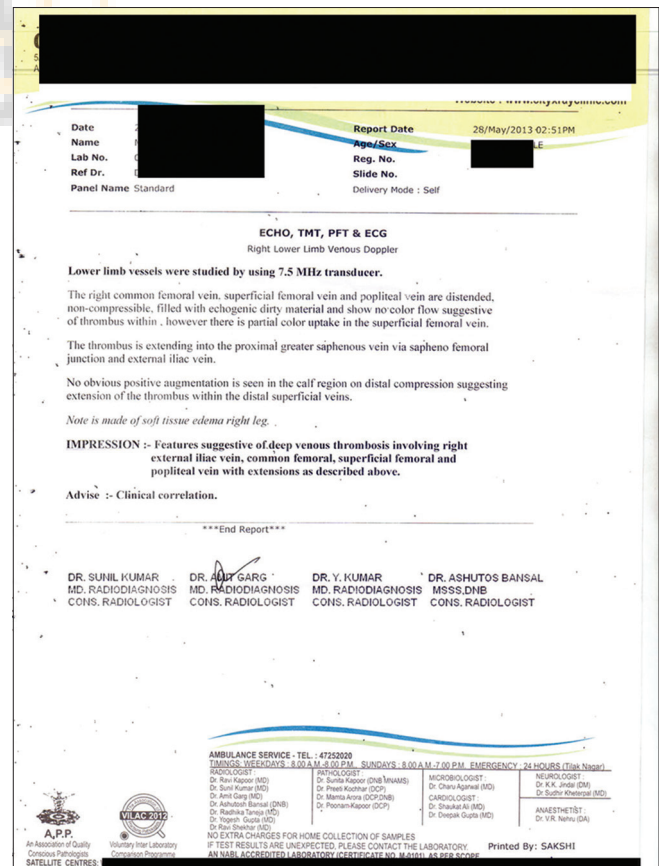
### Prescription and Follow-up

Date wise prescription and follow-up may be seen in Table 2.

Each LM potency was prepared by dissolving one globule in 100 ml of water, to which 40 drops of alcohol were later added.<sup>[10]</sup> The patient was directed to strike the bottle 10 times (holding the bottle in

**Table 1: Pretreatment limb measurement**

Measurement (in inches)	Right	Left
Mid-thigh circumference (5 inches above superior border of patella with leg extended)	24	21
Mid-calf circumference (4 inches below tibial tuberosity)	16	13½



**Figure 1: Right lower limb Doppler (Pre-treatment)**

**Table 2: Prescription and follow-up**

Date	Status	Prescription
31-5-13		<i>Argentum nitricum</i> LM1 tds; to be followed by LM2, tds
14-6-13	The pain in right thigh better Swelling in right lower limb reduced No cramps or episodes of buckling/twisting of right ankle Left knee pain status quo Left sciatica pain status quo Sensation of heat present One episode of restlessness/anxiety in between	<i>Argentum nitricum</i> LM3 tds; to be followed by LM4, tds
1-7-13	Right thigh pain better Swelling in right lower limb reduced No cramps or episodes of buckling/twisting of right ankle Left knee pain status quo Left sciatica pain status quo Sensation of heat present Two episodes of restlessness/anxiety in between	<i>Argentum nitricum</i> LM4 tds; to be followed by LM5, bd
24-7-13	Right thigh pain decreased Swelling in right lower limbless No cramps or episodes of buckling/twisting of right ankle Left knee pain slightly better Left sciatica pain if goes up and down stairs many times Sensation of heat present Single episode of restlessness/anxiety in the middle of sleep, probably due to late dinner	<i>Argentum nitricum</i> LM6 bd; to be followed by LM7, bd
24-8-13	Right thigh pain decreased No cramps or episodes of buckling/twisting of right ankle or anxiety Left knee pain better Left sciatica pain better Sensation of heat present	<i>Argentum nitricum</i> LM8 bd; to be followed by LM9, od
28-9-13	Right thigh pain markedly decreased No cramps or episodes of buckling/twisting of right ankle Left knee pain better Left sciatica pain better Movements more comfortable; able to cook food more comfortably Sensation of heat noticed on and off An episode of restlessness/anxiety when husband delayed in office and did not answer mobile	<i>Argentum nitricum</i> LM10 od; to be followed by LM11, od
23-11-13	Right thigh pain very less Left knee pain definitely better Left sciatica pain better Movements more comfortable; has started with regular evening walks and home visits for giving classes Sensation of heat markedly reduced No episode of restlessness/anxiety	<i>Argentum nitricum</i> LM12 od; to be followed by LM13, od
13-1-14	Caught a chill while traveling a week earlier and developed a fever. Paracetamol and antibiotics have controlled fever, but a cough and wheezing are persisting. Asthalin (salbutamol) inhaler provided relief for 2-3 h only. Unable to sleep or lie down at all, keeps on sitting whole night Marked sensation of heat on cheeks, palms and soles All pains have increased due to coughing Marked restlessness and anxiety	<i>Sanguinaria can</i> 200, tds for first 3 days <i>Sanguinaria can</i> 200 bd for next 3 days <i>Sanguinaria can</i> 200 od for following 3 days
22-1-14	Felt better on the 2 <sup>nd</sup> day of medicine. Did not require asthalin (salbutamol) inhaler after that day No more wheezing or coughing Slight weakness persists Pains reduced remarkably No other trouble	<i>Argentum nitricum</i> LM14 od; to be followed by LM15, od
27-2-14	Slight pain in both knees Sat on floor for a religious ceremony which increased sciatica pain for few days in between No heat, cramps or anxiety Feels better	<i>Argentum nitricum</i> LM16 od; to be followed by LM17, od

Contd...

**Table 2: Contd...**

Date	Status	Prescription
4-4-14	Slight pain in both knees Sat on floor for a religious ceremony which increased sciatica pain for few days in between and recovered with rest and not fomentation No heat, cramps or anxiety Feels better To report next after repeating venous Doppler study	<i>Argentum nitricum</i> LM18 od; to be followed by LM19, od
15-5-14	Slight pain in both knees No sciatica pain, heat, cramps or anxiety Feels better Repeated venous Doppler study on 8-5-14, which shows no evidence of DVT	<i>Argentum nitricum</i> LM20 alternate day; to be followed by LM21, alternate day

DVT: Deep venous thrombosis

dominating hand and striking it against the palm of the other hand) and dissolve 1 teaspoonful (tsp) of the medicine in ½ cup of plain water and consume it. This procedure was to be repeated every time medicine was to be taken.

Physical examination and limb measurements during follow-up are given in Tables 3 and 4, respectively.

During her last visit on 22-8-14, she informed that she was doing fine. She was advised to continue on alternate days *Argentum nitricum* LM 23, to be followed by *Argentum nitricum* LM 24.

### Investigations Undergone (Post-treatment)

On 8-5-14, Venous Doppler right lower limb: Findings reveal early superficial varicosities and incompetent perforator involving right lower limb venous system. No evidence of deep vein thrombosis in right lower limb venous system [Figure 2].

### DISCUSSION AND CONCLUSION

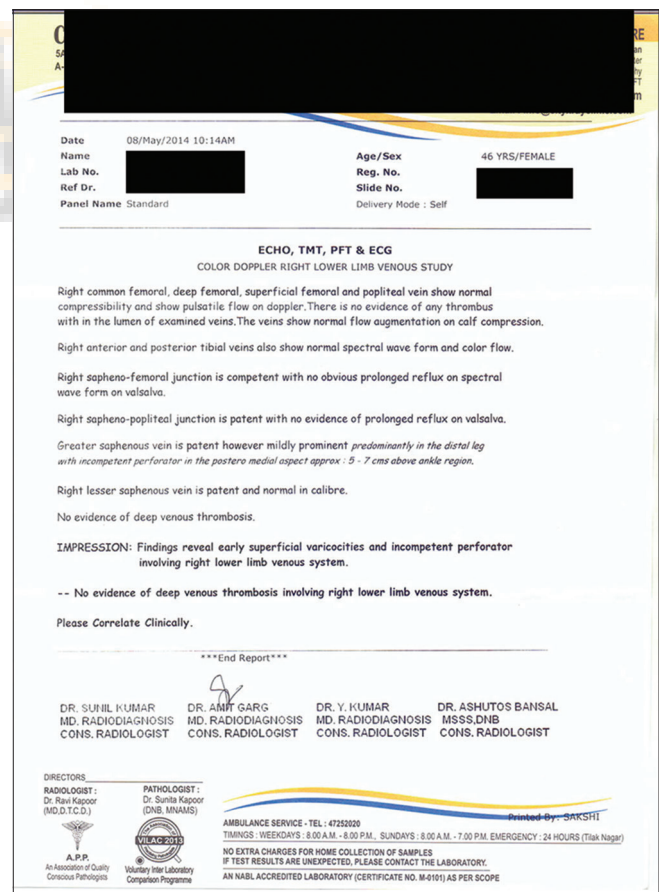
In a previously published case study, it is explained that the most characteristic mental symptoms of homoeopathic remedies are observable as their behavioral disposition.<sup>[11]</sup> In this case, also her anxious, apprehensive and hurried disposition were apparent not just during the initial consultation but also during follow-ups and could be easily verified from her spouse.

All the characteristic features in the above-mentioned case reminded me of Henry Clay Allen's keynotes on *Argentum nitricum*, "Apprehension when ready for church or opera,... wants to do things in a hurry; must walk fast; is always hurried;... anxious, irritable, nervous... Craves sugar;... Great longing for fresh air; Craves fresh air;... opens windows in the coldest weather."<sup>[12]</sup>

**Table 3: Post-treatment physical examination**

Date	Temperature variation between both limbs	Homan's sign	SLR and Lasague's sign
24-8-13	Right warmer than left	Positive	Positive on left side at 45°
23-11-13	Right warmer than left	Positive	Positive on left side at 60°
27-2-14	No discernible	Positive	Negative
15-5-14	No discernible	Negative	Negative

SLR: Straight leg raise



**Figure 2: Right lower limb venous Doppler (Post-treatment)**

**Table 4: Limb measurements during follow-up are as under**

Date	Right mid-thigh circumference (5 inches above superior border of patella with leg extended) in inches	Right mid-calf circumference (4 inches below tibial tuberosity) in inches	Left mid-thigh circumference (5 inches above superior border of patella with leg extended) in inches	Left mid-calf circumference (4 inches below tibial tuberosity) in inches
24-8-13	24	16	21	13½
23-11-13	23¾	15¾	21	13½
27-2-14	23½	15½	21	13½
15-5-14	23¾	15¾	21	13½

Referring to James Tyler Kent's lectures on homoeopathic Materia Medica we found under the chapter on *Argentum nitricum*, "...Looking forward to times he is anxious. When looking forward to something that he is about to do, or in the expectation of things, he is anxious. When about to meet an engagement he is anxious until the time comes...If he is about to take a railroad journey, he is anxious, full of fear and anxiety and tremulous nervousness ... If he is about to meet a certain person on the street corner he is anxious and breaks out often in a sweat from anxiety ... The anxiety he has from these circumstances will bring on complaints... When he is going anywhere, going to a wedding or to the opera, or any unusual event it is attended with anxiety, fear...he wants cold air,... wants the head in the cold air; ... wants the door and windows open;... The irresistible desire for sugar..."<sup>[13]</sup>

Kent further writes regarding the effectiveness of the remedy in certain kinds of cardiovascular diseases, "...The circulation seems to be greatly disturbed in addition to the palpitation. Fullness of the blood vessels and throbbing all over the body. The blood vessels become diseased. Atheromatous degeneration and dilatation of the veins, varicose veins..."<sup>[13]</sup>

Cowperthwaite has also written in his Materia Medica, under the section on General Analysis of the remedy, "...The most important action of *Argentum nitricum* is on the blood, producing an antiplastic effect, rendering it more fluid and darker; the red corpuscles lose their coloring matter; the blood stagnates in the vessels causing ecchymosis, and nutrition is interfered with..."<sup>[14]</sup>

The LM potency scale was chosen in accordance with the directions of Hahnemann in 6<sup>th</sup> edition of Organon, "...Thus in chronic diseases, every correctly chosen homoeopathic medicine, even those whose action is of long duration, may be

repeated daily for months with ever increasing success..."<sup>[10]</sup>

And the homoeopathic remedy selected on the basis of observable "mental disposition" not only helped in the resolution of DVT, as was evident from the Doppler study repeated after a year, but also helped in reduction of the thigh/leg circumference. This is the reason why Hahnemann emphasized in Organon, "...This holds good to such an extent, that the state of disposition of the patient chiefly determines the selection of the homoeopathic remedy, as being a decidedly characteristic symptom which can least of all remain concealed from the accurately observing physician."<sup>[15]</sup>

This clinical (homoeopathic) case study is also relevant as clinical pulmonary embolism occurs in a high proportion of cases of untreated proximal DVT and is associated with a mortality rate of 11–23% if not treated adequately.<sup>[16]</sup>

Further, the homoeopathic remedy also helped in simultaneous amelioration in pains of left sided sciatica and left knee osteoarthritis, which were also interfering with the quality of life. This shows the polysymptomatic polysyndromic coverage capacity of a single homoeopathic remedy, which is selected in accordance with the principles. This phenomenon needs to be explored in longitudinal case studies.

DVT and PTS are known to lower patients' quality of life, specifically with regards to physical and psychological symptoms and limitations in daily activities.<sup>[17]</sup> Further, the treatment of PTS adds significantly to the cost of treating DVT. The annual health care cost of PTS in the United States has been estimated at \$200 million, with costs over \$3800 per patient in the 1<sup>st</sup> year alone, and increasing with disease severity.<sup>[18]</sup> Further, documented cases studies may pave the way for ascertaining the role of homoeopathic drug therapy in such conditions, which is an already established cost-effective system of medicine.

## Financial Support and Sponsorship

Nil.

## Conflicts of Interest

There are no conflicts of interest.

## REFERENCES

1. Available from: <http://www.nlm.nih.gov/medlineplus/ency/article/000156.htm>. [Last accessed on 2015 Jan 09].
2. Available from: <http://www.webmd.com/dvt/>. [Last accessed on 2015 Jan 09].
3. Available from: <http://www.nhs.uk/Conditions/Deep-vein-thrombosis/Pages/Symptoms.aspx>. [Last accessed on 2015 Jan 09].
4. Available from: [http://www.en.wikipedia.org/wiki/Deep\\_vein\\_thrombosis](http://www.en.wikipedia.org/wiki/Deep_vein_thrombosis). [Last accessed on 2015 Jan 09].
5. Ocak G, Vossen CY, Lijfering WM, Verduijn M, Dekker FW, Rosendaal FR, et al. Role of hemostatic factors on the risk of venous thrombosis in people with impaired kidney function. *Circulation* 2014;129:683-91.
6. Available from: <http://www.reference.medscape.com/calculator/dvt-probability-wells-score> [Last accessed on 2015 Jan 09].
7. Available from: <http://www.webmd.com/dvt/d-dimer-test>. [Last accessed on 2015 Jan 09].
8. Available from: <http://www.drbatras.com/en/case-studies/>

- homoeopathy-cures-deep-vein-thrombosis.aspx. [Last accessed on 2015 Jan 09].
9. Available from: <http://www.drvaishnav.com/DVT.aspx>. [Last accessed on 2015 Jan 09].
10. Hahnemann S. *Organon of Medicine*. 5<sup>th</sup> and 6<sup>th</sup> ed. India: B Jain Publishers (P) Ltd.; 2009. p. 127. [§248 and its footnote].
11. Wadhvani GG. Uterine fibroma: A case cured by homoeopathy. *AJHM* 2013;106:120-4.
12. Allen HC. *Keynotes and Characteristics with Comparisons of Some of the Leading Remedies of the Materia Medica with Bowel Nosodes*. Reprint Edition. India: B Jain Publishers (P) Ltd.; 2005. p. 25, 39-41.
13. Kent JT. *Lectures on Homoeopathic Materia Medica*. Reprint Edition. India: B Jain Publishers (P) Ltd.; 2005. p. 136-42.
14. Cowperthwaite AC. *A Textbook of Materia Medica and Therapeutics – Characteristic, Analytical and Comparative*. India: B Jain Publishers (P) Ltd.; 2004. p. 79.
15. Hahnemann S. *Organon of Medicine*. 5<sup>th</sup>, 6<sup>th</sup> ed. India: B Jain Publishers (P) Ltd.; 2009. p. 112. [§211].
16. Markel A. Origin and natural history of deep vein thrombosis of the legs. *Semin Vasc Med* 2005;5:65-74.
17. Kahn SR, Shbaklo H, Lamping DL, Holcroft CA, Shrier I, Miron MJ, et al. Determinants of health-related quality of life during the 2 years following deep vein thrombosis. *J Thromb Haemost* 2008;6:1105-12.
18. Ashrani AA, Heit JA. Incidence and cost burden of post-thrombotic syndrome. *J Thromb Thrombolysis* 2009;28:465-76.

## गहन शिरा घनास्त्र सह पश्चात रक्तशयानन लक्षण समूह के प्रकरण में होम्योपैथिक चिकित्सा द्वारा रोग मुक्ति

सार:

एक 46 वर्षीय महिला जिन्हे दायी ओर बाह्य इलियक शिरा, सुलभ फिमोरल शिरा, उथली फिमोरल शिरा और पोपलिटियल शिरा में घनास्त्र था साथ ही उसका विस्तार रक्तशयानन लक्षण समूह के रूप में था, ने परामर्श हेतु सर्म्पक किया। होम्योपैथिक परामर्श प्रक्रिया के पश्चात, उन्हें बढ़ते क्रम की एलएम पोर्टेंसी में अर्जेन्टम नाइट्रिकम दवा निर्धारित की गयी। होम्योपैथिक उपचार के 2 सप्ताह के भीतर ही उन्होंने लक्षणों में आराम बताया और क्रमशः उनके जीवन की गुणवत्ता में सुधार होता गया साथ ही शियाटिका (गृघसी) और संधिशोथविचलन जैसी अन्य बिमारियों के कारण होने वाला दर्द भी कम हो गया। एक वर्ष पश्चात दोबारा किया गया वीनस डॉप्लर अध्ययन दर्शाता है कि यह चिकित्सकीय स्थिति एकल होम्योपैथिक औषधि चिकित्सा से पूर्णतः ठीक हो गई। शारीरिक परीक्षण में पाया गया की आंगिक परिसीमन में भी कमी हुई है। अनुदैर्घ्य प्रकरण अध्ययन प्रक्रिया बहु लाक्षणिक, बहुलक्षण समूहयुक्त बीमारियों में एकल होम्योपैथिक औषधि की उपचार क्षमता को प्रदर्शित करता है।

## Caso de trombosis venosa profunda con síndrome postrombótico curado con un tratamiento homeopático

### RESUMEN

Una mujer de 46 años de edad se visitó por una trombosis venosa profunda del lado derecho en la vena ilíaca externa, la femoral común, la femoral superficial y las venas poplíteas con extensión, junto con un síndrome postrombótico. Después de la consulta homeopática, se le prescribió *Argentum nitricum* en potencias LM (Q) ascendentes. Tras dos semanas de tratamiento homeopático, se habían aliviado los síntomas y su calidad de vida había ido mejorando gradualmente tras la reducción simultánea del dolor causado por otras molestias, como la ciática y la osteoartritis. Al cabo de un año, se repitieron los estudios venosos con Doppler que mostraron una remisión completa de la patología clínica gracias al tratamiento homeopático exclusivo. La exploración física también mostró una reducción de la circunferencia de la extremidad. El estudio casuístico longitudinal evidencia la capacidad de tratar alteraciones polisindrómicas y polisintomáticas con un único remedio homeopático.