

CASE REPORT

A Case of Multiple Urinary Calculi treated with Homoeopathy

P Paul Sumithran^{1*}

¹Central Research Institute for Homoeopathy, Kottayam, India

A case of multiple urinary calculi, with size varying from five to seven millimeters in the left kidney and four to six millimeters in the right kidney, a thirteen millimeter stone in the left lower part of the ureter and a 20 x 13 millimeter stone in the base of the urinary bladder presenting complaints of burning micturition and pain in the lumbar region reported at the O.P.D of the Central Research Institute for Homoeopathy at Kottayam, Kerala. Patient was having urolithiasis complaints since four years and had undergone both allopathic and ayurvedic treatment, but the response was not satisfactory. After repertorisation, Nitric acid 30C was prescribed. Two doses of this homoeopathic medicine proved to be effective.

Keywords: Homoeopathy; Nitric acid; Urinary calculi

INTRODUCTION

Urolithiasis affects 5-15% of the population worldwide.¹ One of the important phenomena that characterize urolithiasis is its high recurrence.² Recurrence rates are close to 50%³, and the cost of treatment of urolithiasis to individuals and society is high. Shock wave lithotripsy and ureteroscopy are effective instrumental treatments for ureteral stones. However, the possible morbidity, significant cost and the need for highly specialized equipment and special expertise raise the question whether these treatments are indeed the most attractive options to meet the increasing demand.⁴ Although shock wave lithotripsy is the most common treatment for urolithiasis, it can cause acute renal injury.⁵ Computed tomography and magnetic resonance imaging have demonstrated renal injury in 63-85% of patients treated with shock wave lithotripsy.⁶ A retrospective study showed that ureteroscopy is useful when lithotripsy fails; when complex or lower pole renal calculi are present.⁷ Ureteroscopy is less expensive than Extracorporeal Shock Wave Lithotripsy but is more time consuming and technically demanding.⁸

Since non-interventional treatments are the most appealing to patients, however, there is a large interest in alternative medical treatment modalities.⁴ Hence it would be worthwhile to look for an alternative, by using homoeopathic medicines for the treatment of urolithiasis. The efficacy of a single homoeopathic medicine in the treatment of multiple urinary calculi is

highlighted in the present case. This case assumes a great deal of significance especially in the context of a large interest in alternative medical treatment modalities in recent times. This case would help to sustain this interest and also contribute towards encouraging researchers to undertake similar studies to highlight the usefulness of homoeopathic medicines in urolithiasis.

CASE PRESENTATION

A thirty six year old housewife presented with burning micturition and pain in the lumbar region. She was diagnosed to have urolithiasis since four years and was under allopathic and ayurvedic treatment, (*Sodium Acid Citrate liquid for one year and Cystone tablets for three years*), but with unsatisfactory response. No known family history of urolithiasis. The dietary habit was mostly rice, tapioca and dried fish.

The totality of symptoms arrived were pain in the iliac region, pain in the kidney region, frequent urge to urinate at night, painful urination, slow urination, retarded urination, thin stream of urine, sediments in the urine with red colour, eructation eating after, desire for cold, salty food and cold drinks, aversion to indigestible food, painful mouth ulcers, tongue with cracked centre and trembling extremities which increases with anger. She was highly anxious, easily irritable, curses others and gets angry very often.

Ultrasonography – KUB (Fig.2) revealed a 20 x 13 millimeter stone in the base of the urinary bladder, a thirteen millimeter stone in the left lower part of the ureter and multiple stones in both the kidneys with sizes varying from five to seven millimeters in the left kidney and four to six millimeters in the right kidney. On thorough physical examination no abnormal findings

*Address for correspondence:

Dr. P Paul Sumithran,
Central Research Institute for Homoeopathy, Sachivothamapuram
P.O, Kottayam- 686532 (Kerala),
Email: s.sumithran@yahoo.com

were observed. The Serum Uric Acid and Serum Calcium levels were not normal viz. 11 mg/dl and 7.6 mg/dl.

Regular assessments of severity of disease

condition, which was moderate at the entry level, were also done during each of the twenty one follow up visits (Table 1) as per the Urolithiasis Symptom Score (USS) Chart¹². The patient scored a total of 14 at the time of entry.

Table 1: Follow up

Date	Main symptom	Laboratory findings	Symptom score	Medicine prescribed
29.12.07 (first visit)	Moderate pain in iliac region, Frequent urination at night and must wait for urine to start, Moderate dysuria	USG (KUB): Multiple calculi with sizes varying from 5-7mm in the left kidney and 4-6mm in the right kidney; a 13 mm calculus in the left lower part of the ureter and a 20 x 13 mm calculus in the base of the urinary bladder Urine Microscopic Examination: Pus cells and epithelial cells 0-2/HPF Blood Investigation: Serum Uric Acid 11 mg/dl Serum Calcium 7.6 mg/dl	14	Nitric acid 30/1 dose & Placeb tds for 15 days
15.01.08 (first follow up)	Moderate pain in left iliac region, mild painful micturition	–	–	Placebo
28.03.08 (sixth follow up)	Moderate pain in left iliac region which aggravated before urination and painful eruptions in the mouth	USG (KUB): Bilateral multiple renal calculi 4- 5mm in the right kidney and 5-6mm in the left kidney	10	Nitric acid 30/1dose; Placebo tds for 30 days
25.07.08 (tenth follow up)	No symptoms	USG (KUB): Normal scan; no impression of any renal calculi	0	Placebo
23.01.09 (sixteenth follow up)	No symptoms	USG (KUB): Normal scan; no impression of any renal calculi	0	Placebo
26.06.09 (twenty first follow up)	No symptoms	USG (KUB): Normal scan; no impression of any renal calculi Blood Investigation: Serum Calcium 9.1 mg/dl	0	Placebo

Repertorisation Table

Patient Name : _____ Reg. No. : U.I. N 210, R6673/07, S 100, R60, U. 60 Rep. Date : 29/12/2007

Normal Repertorisation

	Nit-ac	Lyc	Nat-m	Puls	Sulph	Sep	Bell	Phos	Merc	ThuJ	Ars	Arg-n	Kali-c	Petr	Nux-v
Totally Symptoms Covered	38	33	30	30	30	28	26	26	26	25	25	24	23	22	22
[KT] [Mind]Anxiety:	3	3	2	3	3	2	3	3	2	2	3	3	3	2	2
[KT] [Mind]Anger,irascibility(see irritability,quarrelsome):	3	3	3	1	3	3	2	1	2	3	1	3	3	3	3
[KT] [Mind]Cursing:	3	2	1	1			1			2				1	2
[KT] [Stomach]Desires:Cold drinks: /		2	1	1	1	2	2	3	3	2	3	2			1
[KT] [Stomach]Desires:Cold Food: /		2	1	3				3		2					
[KT] [Stomach]Desires:Salt things: /	2		3		1			3		1		3			
[KT] [Abdomen]Pain:Aching,dull pain (see Boring,Gnawing,etc.):Iliac re								1					2		
[KT] [Stomach]Eruptions:Eating:After:	2	2	3	3	3	2	1	2	1	1	1	3	2	1	2
[KT] [Mouth]Ulcers:Painful:	3		1						2		2			1	
[KT] [Mouth]Cracked:Tongue fissured:Centre:	2														
[KT] [Urine]Sediment:	2	3	1	3	2	3		2	3	1	2		1	2	
[KT] [Urine]Sediment:Red: ✓	2	1	3	3	1	3	2	1		1	1	2	1	2	2
[KT] [Bladder]Urging to urinate (morbid desire):Night: ✓	2	3	2	1	3	1	2	2	2	2			1	1	2
[KT] [Bladder]Urination:Dysuria:	2	3	2	3	3	2	3	1	2	2	3	3	2	1	3
[KT] [Bladder]Urination:Frequent Nights: ✓	2	3	2	2	3	3	3	1	3	2	1	1	2	1	2
[KT] [Bladder]Urination:Feeble stream (slow):	2	1	1	1	3	2	2		3	1		3	2	2	
[KT] [Bladder]Urination:Retarded:Must wait for urine to start: ✓	2	3	2	1	1	3	2			2		1	2	2	1
[KT] [Bladder]Urination:Thin stream:	2			2	2		1		2	2				2	
[C] [Kidneys]Pain:General:	2	2	2	2	1	2	2	2		2	2	2	2	1	2
[KT] [Extremities]Trembling:Anger,after:	2	2													

Symptoms 1 to 20 Total Symptoms : 20 Remedies 1 to 15 Total Remedies : 380

page 1 of 1

Figure 1: Repertorisation Chart

The repertorisation was done using Hompath Classic 8.0 (Kent Repertory). Nitric acid was the highest scoring medicine by covering maximum rubrics (17) and also scoring highest points (38) (Fig.1). Single dose of Nitric acid 30C was prescribed, with placebo for fifteen days. The patient was advised to avoid oxalate foods such as spinach, chocolates, nuts, whole cereal flours, milk, etc. She was also advised to avoid overeating and was asked to take plenty of water. During the first follow up the patient felt mentally better, but complained of moderate pain in left iliac region and mild painful micturition. Placebo was continued. In next four follow ups, no new symptoms were reported and there was consistent improvement in symptoms.

During the sixth follow up, the patient complained of moderate pain in left iliac region which aggravated before urination and also of painful eruptions in the mouth. The ultrasound report showed the presence of bilateral multiple renal calculi of 4-5mm size in the right kidney and 5-6mm size in the left kidney. The stones in the base of the urinary bladder and the left lower part of the ureter had either been eliminated or completely dissolved (Fig.3). On assessment, the patient scored a total of 10. Another dose of Nitric acid 30 was repeated. This was followed by placebo. In the subsequent follow ups, a significant improvement in symptoms was observed and hence placebo was continued.

In the tenth follow up, no stones were found in the kidney, ureter and bladder (Fig.4). The level of Serum

Uric Acid and Serum Calcium was found to be in the normal range i.e. 4.6 mg/dl (Female Normal range 2.0 – 6.0 mg/dl) and 9.1 mg/dl (Normal range 8.5 – 10.5 mg/dl). The other clinical investigations also confirmed a normal study. On assessment, the patient scored zero. In the subsequent follow ups, no new symptoms were reported. (Fig.5&6).

DISCUSSION

Patient responded positively to the homoeopathic treatment and was relieved of her urolithiasis, with the dissolution or expulsion of the stones. Before resorting to homoeopathic treatment, the patient was under allopathic and ayurvedic treatment for four years with out much improvement. With homoeopathic treatment the patient responded positively. The patient had shown marked improvement in symptom score from baseline score i.e. from 14 to 0. The time period taken for improvement was seven months. This case highlights the usefulness of homoeopathic medicines in the treatment of urolithiasis.

The selection of remedy viz. Nitric acid was based on the highest scoring on repertorisation. It was also verified with Kent's Materia Medica. Lycopodium, Natrum muriaticum, Pulsatilla, Sulphur and Sepia were the other scoring medicines. In this particular case, Nitric acid covered the symptoms such as painful mouth ulcers, cracked tongue fissured centre and anger trembling after; but these symptoms were not covered

by the medicines mentioned above.

The 30th potency of Nitric acid was found to be effective in the dissolution and expulsion of the stones and also in the marked improvement of symptoms. Only two doses were required for the effective management of the symptom. The USG (KUB) report confirmed the dissolution and expulsion of the 20 x 13 mm stone from the urinary bladder and the thirteen millimeter stone from the ureter. Interestingly, in the tenth follow up i.e. after seven months of treatment, the ultrasound report revealed no stone in the kidney, ureter or bladder.

Dr J H Allen mentioned that throughout the whole urinary tract, we find latent symptoms of all miasms. Of the true chronic miasms, psora and sycosis take an active part in the production of diseases in these organs.⁹ According to *Miasmatic Prescribing*¹⁰ and *Chronic Disease – Its Cause and Cure*,¹¹ Nitric acid covers both psoric and sycotic symptoms. This case confirms the usefulness of Nitric acid in psoric and sycotic miasms. Nitric acid belongs to the inorganic or mineral acid group. According to the Universal Mineral Materia Medica, this group has a sphere of action in the genito-urinary tract and is effective in urinary calculi.¹³

This case assumes importance since there were multiple stones in the kidneys, a thirteen millimeter stone in the ureter and a 20 x 13 millimeter stone in the urinary bladder; all of which were either eliminated or completely dissolved in seven months. This highlights the fact that the patient who had urolithiasis for the last four years had shown better response to homoeopathic medicine.

This case demonstrates the role of Homoeopathic constitutional remedy in minimum dose, selected on the concept of totality and prescribed on the principles of

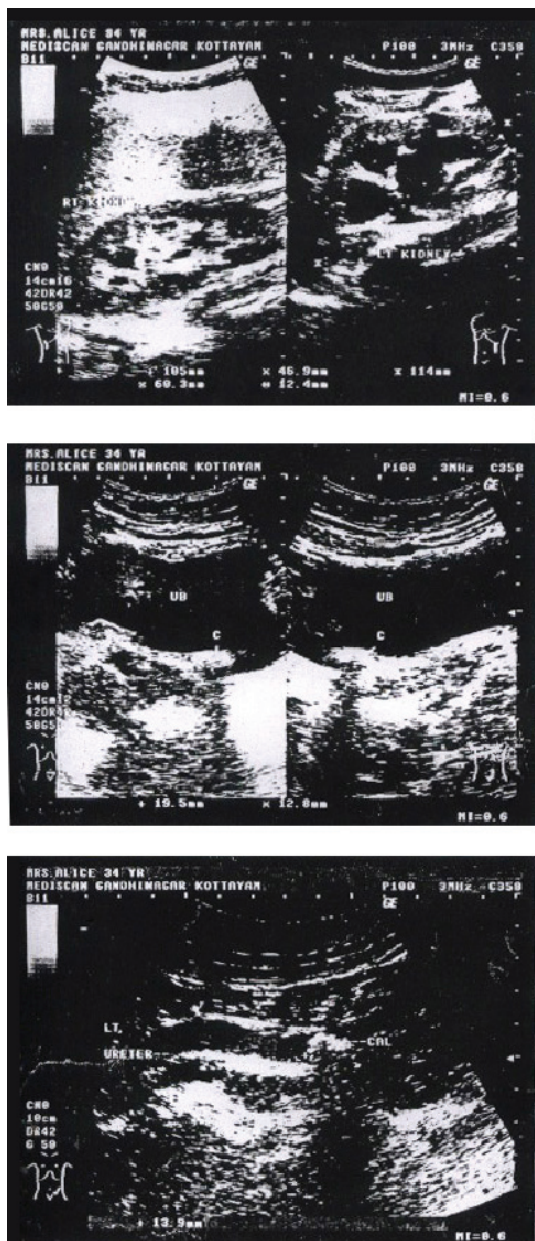


Figure 2

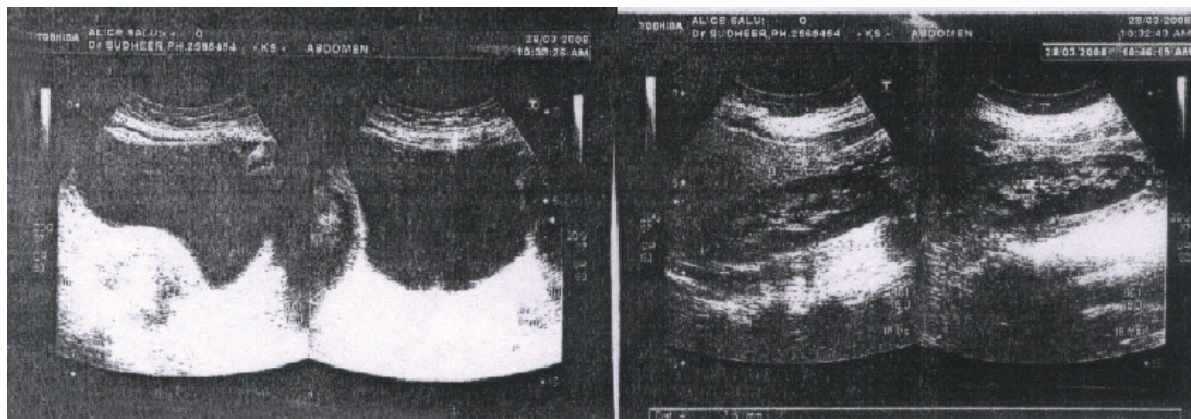


Figure 3 :

A case of multiple urinary calculi treated with homoeopathy
P Paul Sumithran

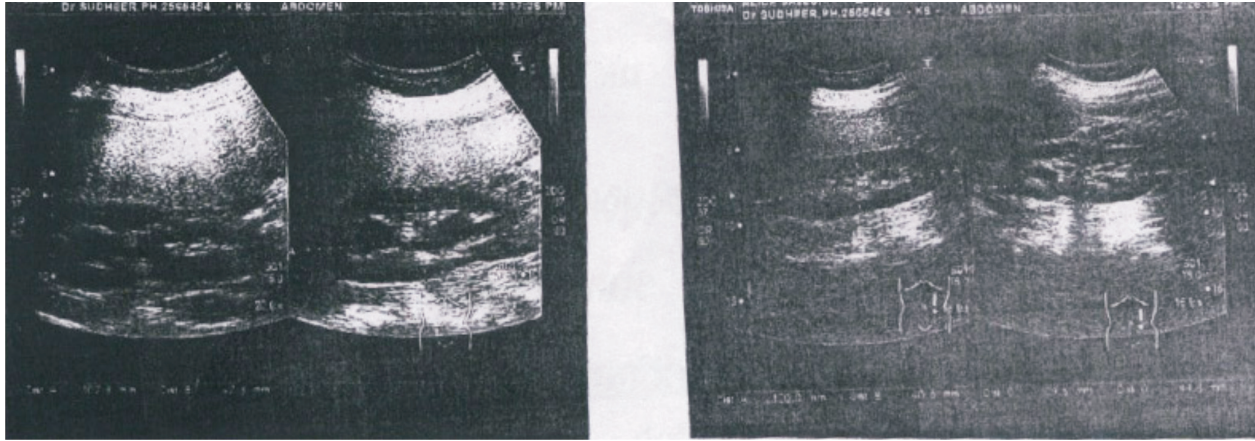


Figure 4

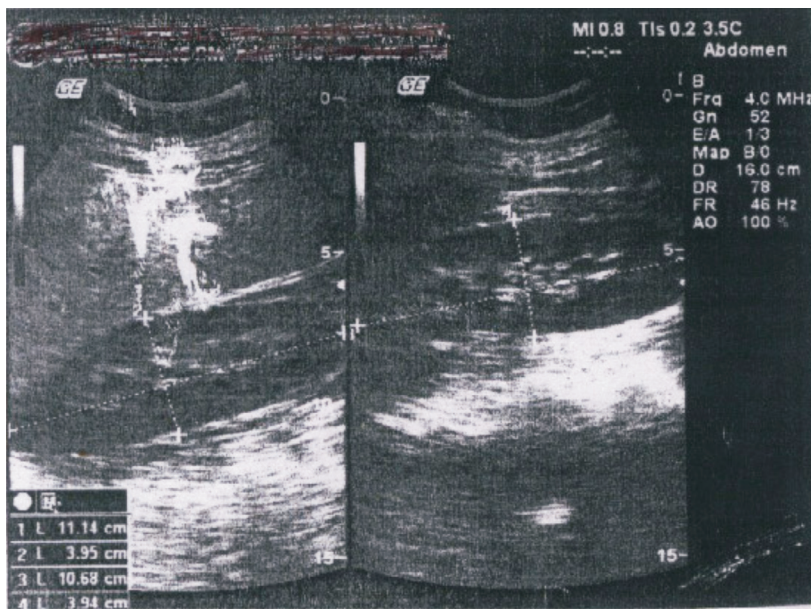


Figure 5

Fig.2 Before treatment
Fig.3, 4, 5, 6 After treatment;
Fig.4, 5, 6 Normal study

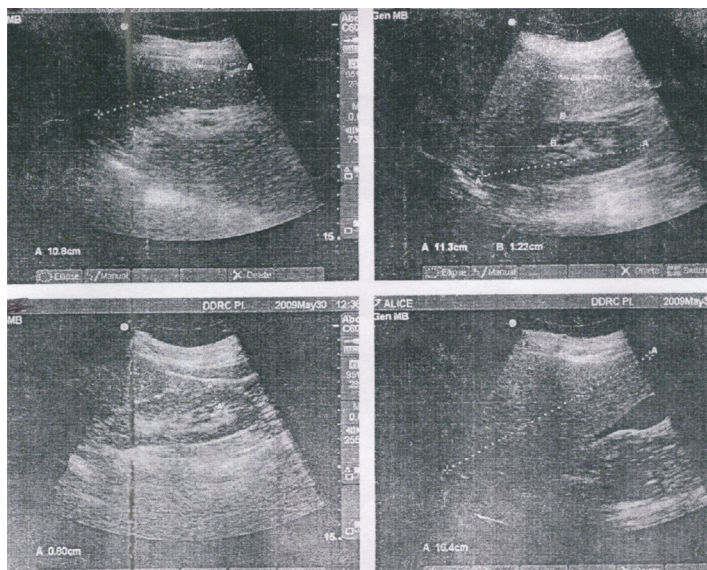


figure 6

individualization in expulsion or dissolution of multiple urinary calculi.

References

1. Moe OW. Kidney stones: Pathophysiology and Medical management. *Lancet* 2006; 367:333-44.
2. Atmani Fouad. Medical Management of Urolithiasis. *Frontiers in Bioscience* 8 2003 May; 507-514.
3. Sutherland JW, Parks JH, Coe FL. Recurrence after a single renal stone in a community practice. *Miner Electrolyte Metab* 1985; 11:267-9.
4. Michel M C, de la Rosette JJMCH α Bolcker treatment of Urolithiasis *European Urology* 2006; 50 (2): 213-14
5. Willis LR, Evan AP, Connors BA, Shao Y, Blomgren PM, Pratt JH, et al. Shockwave lithotripsy: dose-related effects on renal structure, hemodynamics, and tubular function. *J Endourology* 2005; 19:90-101
6. Rubin JI, Arger PH, Pollack HM, Banner MP, Coleman BG, Mintz MC, et al. Kidney changes after extracorporeal shock wave lithotripsy: CT evaluation. *Radiology* 1987; 162(1 Pt 1):21-4.
7. Grasso M, Loisides P, Beaghtler M, Bagley D. The case for primary endoscopic management of upper urinary tract calculi. I. A critical review of 121 extracorporeal shock-wave lithotripsy failures. *Urology* 1995; 45: 363-71.
8. Parmar Malvinder S. Kidney Stones: Clinical Review *BMJ* 2004; 328:1420-24.
9. Allen J H. *The Chronic Miasms Psora and Pseudo-Psora*. Vol.I & II. Reprinted edition. B Jain Publishers Pvt. Ltd. New Delhi; 2002; 239-41.
10. Banerjee P N *Chronic Disease – Its Cause and Cure*. Homoeopathy Prachar Karjalaya;1931; Chapter VII:271-72.
11. Siddiqui VA, et al. A Multicentre Observational Study to Ascertain the Role of Homoeopathic Therapy in Urolithiasis, *Indian Journal of Research in Homoeopathy*, Vol.5, No.2 April- June, 2011; Page 31.
12. Jain RD, Smita Trivedi. *Acids: Inorganic Acids and Organic Acids*. National Journal of Homoeopathy 2000; Jan/Feb Vol.II No.1. Abstracted from Universal Mineral Materia Medica.

