

Paediatric cholelithiasis treated with homoeopathy: A case report

Girish Gupta*

Gaurang Clinic and Centre for Homoeopathic Research, Lucknow, India

Abstract

Introduction: Gallstones are formed due to the precipitation of components of bile in the lumen of the gallbladder. The incidence of gallstones is extremely rare in children and patients are mostly asymptomatic. However, biliary colic may occur due to reflexive smooth muscle spasm by the stone obstructing the bile duct and may be the presenting symptom in 50% of cases of paediatric cholelithiasis whereas 25% may have non-specific symptoms, 20% may be asymptomatic and 5–10% may have complicated symptoms. The conventional treatment of gallstones is surgery even in children, whereas homoeopathy can provide non-surgical treatment in such cases. **Case Summary:** A 3-year-old girl child presented with multiple gallstones and recurrent right hypochondrial pain, nausea and vomiting. Surgeons had advised the parents to wait and watch. *Phosphorus 30C* and *Chelidonium majus Q* were selected after a detailed case recording and repertorisation, and this treatment gave a positive outcome in 4 months. Evidence-based treatment with individualised homoeopathic medicine thus, seem to help in the cases of paediatric cholelithiasis.

Keywords: Case report, Gallstone, Holistic, Homoeopathy, Paediatric cholelithiasis

INTRODUCTION

Gallstones form in the gallbladder when excessive cholesterol/bilirubin in the bile precipitates or contains fewer bile salts, or if the gallbladder does not empty completely.^[1] About 80% of patients with gallstones are asymptomatic.^[2] However, biliary colic may occur in 1–4% of patients due to obstruction of the bile duct with a stone.^[3] Biliary colic may be the presenting symptom in 50% of cases of paediatric cholelithiasis, 25% may have non-specific symptoms, 20% may be asymptomatic and 5–10% may have complicated symptoms.^[4-6] Cholesterol gallstones are common in adults due to the supersaturation of bile with stasis. In contrast, pigment stones are more common in children, due to the supersaturation of bile with calcium bilirubinate. Cholelithiasis and choledocholithiasis are uncommon in children thus very little is known about the epidemiology. In recent years, the detection of asymptomatic cases may be attributed to the use of ultrasonography.^[6,7] Paediatric cholelithiasis is of haemolytic type in 20–30% of cases, due to parenteral nutrition, frusemide, ileal disease, congenital biliary diseases, phototherapy in infants for various medical reasons in 40–50% and idiopathic in 30–40% cases.^[8-10] The exact prevalence of gallstones in children is not known. The overall prevalence of paediatric cholelithiasis has been reported to be 0.13–0.2% in Europe, <0.13% in Japan

and 0.3% in an Indian hospital setting.^[8-13] Another study reported the prevalence of gallstones among obese children and adolescents as 2% of 493 children.^[14,15] Usually, asymptomatic gallstones do not pose any medical emergency.^[3] Spontaneous resolution of gallstones may occur in children, and hence, cholecystectomy is deferred unless the aetiology is haemolytic or the patient has typical biliary symptoms.^[3] The treatment in the rest cases is usually surgical removal of the gallbladder.

Patients with gallbladder stones often opt for homoeopathic treatment to avoid surgery. However, the treatment outcome of such cases is available and mostly documented in non-peer-reviewed journals, online platforms and websites.^[16-18] The homoeopathic treatment of a child having multiple gallbladder calculi is being reported here, following the HOM-CASE CARE guidelines.^[19] The purpose of such documentation is to add to the evidence that homoeopathic treatment not only provides symptomatic relief in cholelithiasis but also has an effect on the pathology resulting from this. Moreover, a

***Address for correspondence:** Girish Gupta,
B-1/41, Sector-A, Near Novelty Cinema (Aliganj),
Kapoorthala, Lucknow - 226 024, Uttar Pradesh, India.
E-mail: girishguptadr@gmail.com

Received: 07 December 2022; **Accepted:** 12 March 2024

Access this article online

Quick Response Code:



Website:
www.ijrh.org

DOI:
10.53945/2320-7094.1310

This is an open access journal, and articles are distributed under the terms of the Creative Commons Attribution-NonCommercial-ShareAlike 4.0 License, which allows others to remix, tweak, and build upon the work non-commercially, as long as appropriate credit is given and the new creations are licensed under the identical terms.

How to cite this article: Gupta G. Paediatric cholelithiasis treated with homoeopathy: A case report. *Indian J Res Homoeopathy* 2024;18:29-35.

systematic single case report may contribute to the critical evaluation of homoeopathic treatment.^[20]

CASE REPORT

Patient information

A 3-year-old girl was brought to us by her parents on 27 May 2022 with complaints of recurrent episodes of pain in the right hypochondriac region, with nausea and vomiting since February 2022, especially after eating. She had been diagnosed with multiple gallbladder calculi, on 17 March 2022 at Sanjay Gandhi Postgraduate Institute of Medical Sciences, Lucknow, where the surgeons had advised the parents to wait and watch. Her parents, however, sought homoeopathic treatment because of her symptoms.

As the patient was just 3 years old, not many constitutional symptoms could be extracted. Only a few symptoms mentioned by her mother were considered for repertorisation. The child was extrovert, obstinate, restless and had a habit of nail-biting. She was afraid of being alone and used to startle during sleep. She had a tendency for perspiration on the scalp. She used to eat packaged chips often and had a desire for spicy food, ice cubes and icy cold water. She was chilly and had a tendency to catch cold.

Initial ultrasonography dated 17 March 2022 revealed multiple studded calculi in gallbladder fundus with total length of 20 mm. Spleen was mildly enlarged measuring 7.4 cm [Figure 1].

Repertorial analysis

The totality of symptoms was framed and the symptoms were converted into rubrics [Figure 2].

The case was repertorised using Hompath Classic software (Ver. 8.0) [Figure 2]. *Phosphorus* covered the maximum number of symptoms and scored the highest.

Therapeutic intervention

Phosphorus was selected in this case considering the patient's constitution, mentals and physical generals such as feeble constitution, extrovert nature, restlessness, nail-biting, startling during sleep and fear of being alone. *Phosphorus* is also known to be useful in patients with gallbladder stones, with belching and vomiting after meals and having a liking for cold drinks and ice creams. This patient had a tendency to catch cold, still wanted cold drinks, ice cream, juicy, spicy things and had a craving for ice cubes. She had constant nausea and pain in her abdomen with an increased thirst for ice-cold water which was vomited as soon as it became warm. *Chelidonium majus Q* was prescribed for acute symptoms such as pain in the right hypochondriac region with nausea and vomiting, especially after eating.^[21-24]

The homoeopathic medicine *Phosphorus* 30C, manufactured by a Good Manufacturing Practice (GMP) certified pharmaceutical company, was prescribed in 2-grain tablets. The patient was advised to take a single pill at bedtime once a week along with *Chelidonium Q* 10 drops, with ¼ cup of water, thrice daily, for 4 weeks.

Follow-up and outcomes

The details of the follow-up are shown in Table 1. The ultrasonography findings dated 27 September 2022 were normal [Figure 3].

The case was analysed and the causal attribution of the outcome was assessed by scoring in 11 domains as per Modified Naranjo Criteria for homoeopathy^[25] (minimum score: 6 and maximum score: 13). The total score in this case was 7 [Table 2].

DISCUSSION

Little is known about the epidemiology of cholelithiasis in children. Cholelithiasis and choledocholithiasis were considered to be uncommon in infants and children but have been increasingly diagnosed in recent years due to the widespread use of ultrasonography. Small stones can

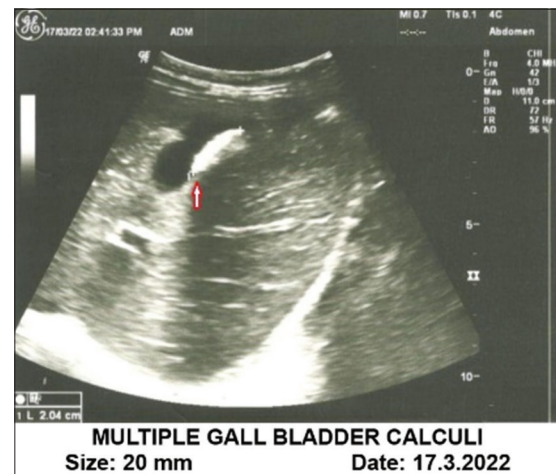

Figure 1: Ultrasonography findings before treatment

Table 1: Follow-ups

Date	Symptoms/Observations	Prescription
27 May 2022	Pain in the right hypochondriac region with nausea and vomiting. Nail-biting, fear of being alone and starting during sleep had reduced	<i>Phos</i> 30C single dose, once a week <i>Chelidonium Q</i> 10 drops TDS × 4 weeks
4 July 2022	Pain abdomen and nausea reduced. Nail-biting, fear of being alone and starting during sleep subsided	Prescription repeated
16 August 2022	Mild abdominal pain or nausea at times but much less in comparison to the past	Prescription repeated Repeat ultrasonography of the abdomen advised
27 September 2022	Clinically asymptomatic. The tendency to catch cold also subsided	Ultrasonography of abdomen dated 27 September 2022: 'Gallbladder is normal in size. Lumen is anechoic'. Treatment stopped

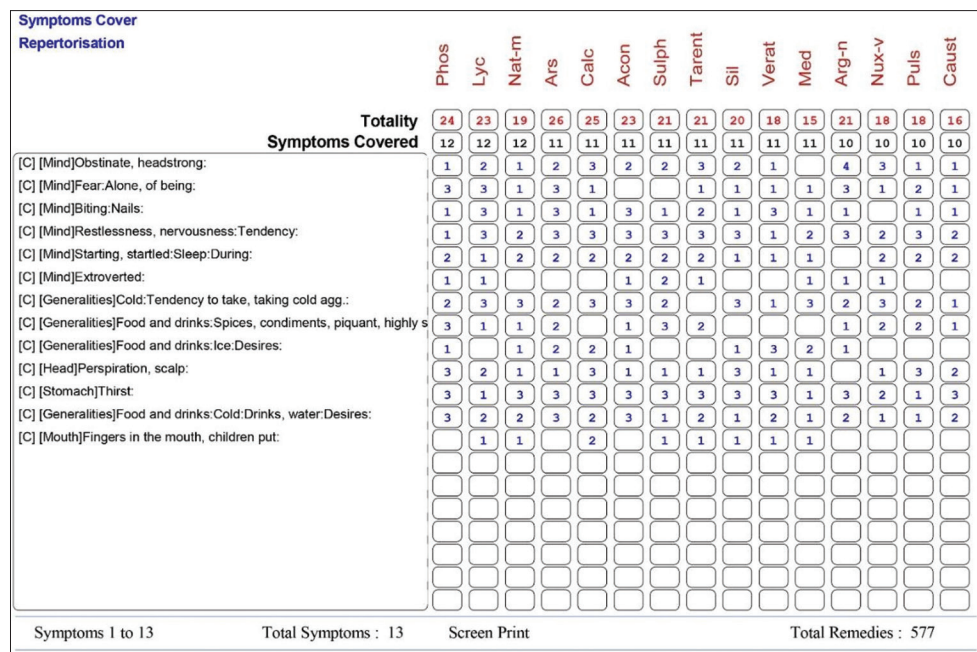


Figure 2: Repertorisation chart

S. No.	Domains	Yes	No	Not sure or N/A	Score
1	Was there an improvement in the main symptom or condition for which the homoeopathic medicine was prescribed?	+2	-1	0	+2
2	Did the clinical improvement occur within a plausible time frame relative to the drug intake?	+1	-2	0	+1
3	Was there an initial aggravation of symptoms?	+1	0	0	0
4	Did the effect encompass more than the main symptom or condition (i.e., were other symptoms ultimately improved or changed)?	+1	0	0	+1
5	Did overall well-being improve? (suggest using a validated scale)	+1	0	0	+1
6a	Direction of cure: did some symptoms improve in the opposite order of the development of symptoms of the disease?	+1	0	0	0
6b	Direction of cure: did at least one of the following aspects apply to the order of improvement of symptoms: From organs of more importance to those of less importance? From deeper to more superficial aspects of the individual? From the top downwards?	+1	0	0	0
7	Did 'old symptoms' (defined as non-seasonal and non-cyclical symptoms that were previously thought to have resolved) reappear temporarily during the course of improvement?	+1	0	0	0
8	Are there alternate causes (other than the medicine) that-with a high probability-could have caused the improvement? (Consider known course of disease, other forms of treatment and other clinically relevant interventions)	-3	+1	0	0
9	Was the health improvement confirmed by any objective evidence? (e.g., laboratory test, clinical observation, etc.)	+2	0	0	+2
10	Did repeat dosing, if conducted, create similar clinical improvement?	+1	0	0	0
	Total				7

only be detected by high-resolution sonography. However, there is not much information from India about this and no consensus among Indian paediatricians and paediatric surgeons exist regarding the management of gallstones in children. Spontaneous resolution of gallstones is frequent in infants and hence a period of observation is recommended even for choledocholithiasis. Cholecystectomy is useful in children with

typical symptoms of biliary obstruction such as icterus but is not recommended in those with non-specific symptoms.^[6]

In the modern system of medicine, the treatment of gallstones is very difficult and surgical intervention is advised even in children. In the present case, surgery was deferred due to small age till acute symptoms bother the child too much. After detailed analysis and repertorisation, homoeopathic

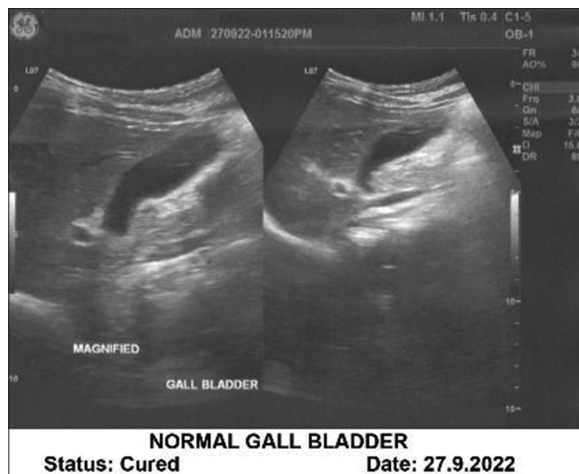

Figure 3: Ultrasonography findings post-treatment

medicine *Phosphorus* 30C was selected based on the totality of symptoms considering the constitution of the patient, mental and physical general symptoms. Besides the chief complaints, nail-biting, fear of being alone, starting during sleep and tendency to catch cold, also subsided. Spontaneous resolution of stones may occur in children but not in every patient. In this case, the stone was dissolved in a plausible timeframe by homoeopathic treatment. The treatment was complemented by *Chelidonium Q*. Since *Phosphorus* was selected based on the constitution, mental and physical general symptoms and prescribed in dynamic form (30c potency) thus *Chelidonium* was prescribed in material dose as a mother tincture. No adverse effects were observed during the homoeopathic treatment.

Chelidonium majus is a plant of the Papaveraceae family containing many alkaloids such as isoquinolone and caffeic acid derivatives as active ingredients. It is used as a mild analgesic, antispasmodic and sedative to treat biliary colic, cholelithiasis, jaundice, diffuse fatty infiltration of the liver and other complaints of gallbladder.^[26]

The obvious limitation of this case report is insufficient proof of causality on its own as the spontaneous resolution of gallstones is reported to occur in children yet the dissolution of stone by homoeopathic treatment in a timeframe of only 6 months is commendable.

CONCLUSION

This case, supported by pre- and post-ultrasonographic reports, shows the effectiveness of individualised homoeopathic medicine *Phosphorus* in the treatment of gallbladder stones prescribed on a holistic basis along with *Chelidonium majus*. Dissolution of gallbladder stones in this case of a 3-year-old girl by individualised homoeopathic medicine gives a ray of hope to paediatric cases where surgery is recommended.

Parents' perspective

The parents were reluctant to surgery due to the patient's small age. The surgeons had also advised to wait and watch

till acute symptoms subside. The parents were quite satisfied with the positive outcome of homoeopathic treatment and were thankful to the treating physician for saving the child from surgical intervention.

Declaration of patient consent

The patient's father gave written consent to publish/report anonymised patient data, case records, USG films and reports.

Financial support and sponsorship

Nil.

Conflict of interest

There is no conflict of interest.

REFERENCES

1. Internal Clinical Guidelines Team. Gallstone Disease: Diagnosis and Management of Cholelithiasis, Cholecystitis and Choledocholithiasis. Clinical Guideline 188. London: National Institute for Health and Care Excellence (NICE); 2014. Available from: <https://pubmed.ncbi.nlm.nih.gov/25473723> [Last accessed on 2024 Jan 28].
2. Lee JY, Keane MG, Pereira S. Diagnosis and treatment of gallstone disease. *Practitioner* 2015;259:15-9.
3. Ansaloni L, Pisano M, Coccolini F, Peitzmann AB, Fingerhut A, Catena F, *et al*. 2016 WSES guidelines on acute calculous cholecystitis. *World J Emerg Surg* 2016;11:25.
4. Lee YJ, Park YS, Park JH. Cholecystectomy is feasible in children with small-sized or large numbers of gallstones and in those with persistent symptoms despite medical treatment. *Pediatr Gastroenterol Hepatol Nutr* 2020;23:430-8.
5. Rief S, Sloven DG, Leberthal E. Gallstones in children. Characterization by age, etiology, and outcome. *Am J Dis Child* 1991;145:105-8.
6. Holcomb GW Jr., Holcomb GW 3rd. Cholelithiasis in infants, children and adolescents. *Pediatr Rev* 1990;11:268-74.
7. Poddar U. Gallstone disease in children. *Indian Paediatr* 2010;47:945-53.
8. Shaikh NM. Gall Stones in Paediatric Population; 2021. Available from: <https://www.intechopen.com/chapters/77803> [Last accessed on 2023 Feb 25].
9. Wesdorp I, Bosman D, De Graaff A, Aronson D, Van der Blij F, Taminiu J. Clinical presentations and predisposing factors of cholelithiasis and sludge in children. *J Pediatr Gastroenterol Nutr* 2000;31:411-7.
10. Schweizer P, Lenz MP, Kirschner HJ. Pathogenesis and symptomatology of cholelithiasis in childhood. A prospective study. *Dig Surg* 2000;17:459-67.
11. Schirmer WJ, Grisoni ER, Gauderer MW. The spectrum of cholelithiasis in the first year of life. *J Pediatr Surg* 1989;24:1064-7.
12. Palasciano G, Portincasa P, Vinciguerra V, Velardi A, Tardi S, Baldassarre G, *et al*. Gallstone prevalence and gallbladder volume in children and adolescents: An epidemiological ultrasonographic survey and relationship to body mass index. *Am J Gastroenterol* 1989;84:1378-82.
13. Nomura H, Kashiwagi S, Hayashi J, Kajiyama W, Ikematsu H, Noguchi A, *et al*. Prevalence of gallstone disease in a general population of Okinawa, Japan. *Am J Epidemiol* 1988;128:598-605.
14. Ganesh R, Muralinath S, Sankarnarayanan VS, Sathiyasekaran M. Prevalence of cholelithiasis in children--a hospital-based observation. *Indian J Gastroenterol* 2005;24:85.
15. Kaechele V, Wabitsch M, Thiery D, Kessler AL, Haenle MM, Mayer H, *et al*. Prevalence of gallbladder stone disease in obese children and adolescents: Influence of the degree of obesity, sex and pubertal development. *J Pediatr Gastroenterol Nutr* 2008;42:66-70.
16. Qureshi SA. Gall Bladder Stones Cured by Homoeopathic Treatment; 2016. Available from: <https://sabeelhomeoclinic.com/case-study-gall-bladder-stones-cured-by-homeopathic-treatment> [Last accessed 2016 Aug 13].
17. Gupta G, Singh S. Evidence based clinical study in cases of cholelithiasis

- in response to homoeopathic treatment. *Asian J Homoeopathy* 2014;8:27-37.
18. Kumar R. A Case-of-Paediatric Cholelithiasis; 2012. Available from: <https://www.scribd.com/document/162941622/a-case-of-paediatric-cholelithiasis> [Last accessed on 2024 May 02].
 19. Van Haselen RA. Homeopathic clinical case reports: Development of a supplement (HOM-CASE) to the CARE clinical case reporting guideline. *Complement Ther Med* 2016;25:78-85.
 20. Witt CM, Linde K. *Clinical Research in Complementary and Integrative Medicine: A Practical Training Book*. 1st ed. Germany: Urban and Fischer; 2011. p. 163-70.
 21. Kent JT. *Lectures on Homoeopathic Materia Medica, Phosphorus*. New Delhi: B. Jain Publishers Pvt Ltd.; 2009. p. 824-36.
 22. Murphy R. *Homoeopathic Medical Repertory*. 2nd ed. New Delhi: B. Jain Publishers Pvt Ltd.; 1996. p. 409-10.
 23. Allen HC. *Key Notes and Characteristics with Comparisons of Some of the Leading Remedies of the Materia Medica with Bowel Nosodes*. 18th ed. New Delhi: B. Jain Publishers Pvt Ltd.; 1990. p. 93-4.
 24. Boericke W. *Homoeopathic Materia Medica*. Delhi: Prakashan Kendra; 1991. p. 189-91.
 25. Lamba CD, Gupta VK, Van Haselen R, Rutten L, Mahajan N, Molla AM, *et al*. Evaluation of the modified Naranjo criteria for assessing causal attribution of clinical outcome to homeopathic intervention as presented in case reports. *Homeopathy* 2020;109:191-7.
 26. Deakin PJ, Quick RG, Reed JB, Harper SJ, Saeb Parsy K. *Essential Surgery E-Book: Problems, Diagnosis and Management: With Student Consult Online Access*. 5th ed. London: Churchill Livingstone; 2013. p. 281.

Titre : Lithiase biliaire pédiatrique traitée par homéopathie : à propos d'un cas

Introduction: Les calculs de la vésicule biliaire se forment en raison de la précipitation des composants biliaires de la bile dans la lumière de la vésicule biliaire. L'incidence des calculs biliaires est extrêmement rare chez les enfants et les patients sont pour la plupart asymptomatiques. Cependant, des coliques biliaires peuvent survenir en raison d'un spasme réflexif des muscles lisses provoqué par le calcul obstruant le canal biliaire et peuvent être le symptôme révélateur dans 50 % des cas de lithiase biliaire pédiatrique, tandis que 25 % peuvent présenter des symptômes non spécifiques, 20 % peuvent être asymptomatiques et 5 à 10 % peut avoir des symptômes compliqués. Le traitement conventionnel des calculs biliaires est la chirurgie, même chez les enfants, tandis que l'homéopathie peut fournir un traitement non chirurgical dans de tels cas. Résumé du cas: Le cas présenté ici est celui d'une fillette de 3 ans présentant de multiples calculs biliaires et des douleurs hypocondriaques hypocondriaques droites récurrentes, des nausées et des vomissements. Le traitement conventionnel consiste généralement en l'ablation chirurgicale de la vésicule biliaire, tandis que l'homéopathie peut proposer un traitement médicamenteux. Les chirurgiens avaient conseillé aux parents d'attendre et de surveiller. Phosphorus 30C et Chelidonium majus Q ont été prescrits, sélectionnés après un enregistrement et une répertorisation détaillés des antécédents, et ce traitement pendant 4 mois a eu un résultat positif. Un traitement fondé sur des preuves avec une médecine homéopathique individualisée donne une lueur d'espoir dans les cas de lithiase biliaire pédiatrique.

Titel: Mit Homöopathie behandelte Cholelithiasis bei Kindern: Ein Fallbericht

Einleitung: Gallensteine entstehen durch die Ausfällung von Gallenbestandteilen im Lumen der Gallenblase. Das Vorkommen von Gallensteinen bei Kindern ist äußerst selten und die Patienten sind meist asymptomatisch. Allerdings kann eine Gallenkolik aufgrund eines reflektorischen Krampfes der glatten Muskulatur durch den Stein, der den Gallengang verstopft, auftreten und in 50 % der Fälle von pädiatrischer Cholelithiasis das vorherrschende Symptom sein, während 25 % unspezifische Symptome aufweisen können, 20 % asymptomatisch sein können und 5–10 % kann komplizierte Symptome haben. Die konventionelle Behandlung von Gallensteinen ist auch bei Kindern eine Operation, während in solchen Fällen die Homöopathie eine nicht-chirurgische Behandlung ermöglichen kann. Fallzusammenfassung: Der hier vorgestellte Fall betrifft ein 3-jähriges Mädchen mit mehreren Gallensteinen und wiederkehrenden Schmerzen im rechten Hypochondrium, Übelkeit und Erbrechen. Die konventionelle Behandlung ist in der Regel die chirurgische Entfernung der Gallenblase, während die Homöopathie eine medikamentöse Behandlung bieten kann. Die Chirurgen hatten den Eltern geraten, abzuwarten und zuzusehen. Phosphor 30C und Chelidonium majus Q wurden nach einer detaillierten Anamneseerhebung und Repertorisierung ausgewählt und diese Behandlung über 4 Monate hinweg hatte ein positives Ergebnis. Die evidenzbasierte Behandlung mit individualisierter homöopathischer Medizin gibt einen Hoffnungsschimmer, der bei Kindern mit Cholelithiasis helfen kann.

बच्चों में कोलेलियसिस का होम्योपैथी से इलाज: एक केस रिपोर्ट

परिचय: पित्ताशय की पथरी पित्ताशय की लुमेन में पित्त घटकों के अवक्षेपण के कारण बनती है। बच्चों में पित्त पथरी होना अत्यंत दुर्लभ है और ज्यादातर रोगियों में लक्षण नहीं दिखाई देते। हालाँकि, पित्त नली में रुकावट पैदा करने वाले पत्थर द्वारा प्रतिवर्ती चिकनी मांसपेशियों की ऐंठन के कारण पित्त संबंधी शूल हो सकता है और बच्चों में कोलेलियसिस के 50% मामलों में यह मुख्य लक्षण हो सकता है, जबकि 25% में गैर-विशिष्ट लक्षण हो सकते हैं, 20% में लक्षण नहीं होते और 5-10% में जटिल लक्षण हो सकते हैं। बच्चों में भी पित्त पथरी का पारंपरिक उपचार सर्जरी है, जबकि होम्योपैथी ऐसे मामलों में गैर-सर्जिकल उपचार विकल्प प्रदान कर सकती है।

सारांश: यहां प्रस्तुत मामला एक 3 साल की बच्ची का है जिसे कई पित्त पथरी और बार-बार दाएं हाइपोकोण्ड्रियम में दर्द, मतली और उल्टी की समस्या थी। पारंपरिक उपचार में आमतौर पर पित्ताशय को शल्य चिकित्सा द्वारा हटाया जाता है, जबकि होम्योपैथी औषधीय उपचार प्रदान कर सकती है। सर्जनों ने माता-पिता को इंतजार करने और निगरानी रखने की सलाह दी थी। फॉस्फोरस 30C और चेलिडोनियम मैजस Q को विस्तृत केस हिस्ट्री रिकॉर्डिंग और रिपोर्टाइजेशन के बाद चयनित किया गया, और 4 महीने तक चलने वाले इस उपचार का सकारात्मक परिणाम आया। वैयक्तिगत होम्योपैथी चिकित्सा के साथ साक्ष्य-आधारित उपचार बच्चों में कोलेलियसिस के मामलों में आशा की किरण जगा सकती है।

Título: Colelitiasis pediátrica tratada con homeopatía: reporte de un caso

Introducción: Los cálculos de la vesícula biliar se forman debido a la precipitación de los componentes biliares de la bilis en la luz de la vesícula biliar. La incidencia de cálculos biliares es extremadamente rara en niños y los pacientes en su mayoría son asintomáticos. Sin embargo, el cólico biliar puede ocurrir debido al espasmo reflejo del músculo liso por el cálculo que obstruye el conducto biliar y puede ser el síntoma de presentación en el 50 % de los casos de colelitiasis pediátrica mientras que el 25 % puede tener síntomas inespecíficos, el 20 % puede ser asintomático y el 5-10 % puede tener síntomas complicados. El tratamiento convencional de los cálculos biliares es la cirugía incluso en niños, mientras que la homeopatía puede proporcionar un tratamiento no quirúrgico en tales casos. Resumen del caso: El caso que se presenta aquí es el de una niña de 3 años que presentó múltiples cálculos biliares y dolor recurrente en el hipocondrio derecho, náuseas y vómitos. El tratamiento convencional suele ser la extirpación quirúrgica de la vesícula biliar, mientras que la homeopatía puede proporcionar un tratamiento medicinal. Los cirujanos habían aconsejado a los padres que esperaran y observaran. Se prescribieron Phosphorus 30C y Chelidonium majus Q seleccionados después de un registro detallado de la historia clínica y una repertorización, y este tratamiento durante 4 meses tuvo un resultado positivo. El tratamiento basado en la evidencia con medicamentos homeopáticos individualizados ofrece un rayo de esperanza para ayudar en los casos de colelitiasis pediátrica.

标题：顺势疗法治疗小儿胆石症：病例报告

简介：胆囊结石是由于胆汁中的胆汁成分在胆囊腔内沉淀而形成的。胆结石的发病率在儿童中极为罕见，而且患者大多无症状。然而，由于结石阻塞胆管引起反射性平滑肌痉挛，可能会出现胆绞痛，这可能是 50% 小儿胆石症病例的症状，25% 可能有非特异性症状，20% 可能无症状，5-10% 可能有症状。可能有复杂的症状。即使是儿童，胆结石的传统治疗方法也是手术，而顺势疗法可以在这种情况下提供非手术治疗。病例摘要：本病例为一名 3 岁女童，患有多发性胆结石，并伴有反复右肋肋痛、恶心和呕吐。常规治疗通常是手术切除胆囊，而顺势疗法可以提供药物治疗。外科医生建议父母等待并观察。经过详细的病史记录和复查后，选择了磷 30C 和白屈菜 Q，治疗 4 个月取得了积极的结果。个体化顺势疗法的循证治疗为治疗小儿胆石症带来了一线希望。