

# Tinea capitis treated with homeopathic medicine *Pulsatilla nigricans*: A case report

Khushboo Garg<sup>1\*</sup>, Divya Bansal<sup>1</sup>, Aayush Mittal<sup>2</sup>

<sup>1</sup>Central Council for Research in Homoeopathy, New Delhi, India, <sup>2</sup>Homoeopathic Consultant, New Delhi, India

## Abstract

**Introduction:** Tinea infection is a common complaint encountered in day-to-day practice with increasing incidence, especially in countries such as India over the past decade. Tinea capitis is predominantly a disease of prepubertal children characterised by lesions of variable morphology on the scalp associated with itching, erythema, signs of inflammation and hair loss. Prompt recognition and treatment are necessary to prevent its spread due to its contagious nature, associated hair loss and the resultant psychological impact on social life. Individualised homeopathic treatment has a significant scope in treating and combating such conditions cost-effectively through the totality of symptoms. **Case Summary:** A 12-year-old girl presented at an outpatient clinic with erythematous and circular lesions with itching, burning pain and hair fall. *Pulsatilla nigricans* 200 was prescribed initially and later *Pulsatilla* 1M was prescribed as per the homeopathic principles. The case was followed up fortnightly for 6 months. The patient was successfully treated with marked improvement in signs and symptoms (especially during the rainy season, which is the usual time for aggravation of tinea infections) within 6 months with no aggravation and adverse events. The Modified Naranjo Criteria Score was used to establish the causal attribution to the prescribed medicine, with a total score of 9. This case report suggests that individualised homeopathic medicines are useful in the treatment of tinea capitis.

**Keywords:** Homoeopathy, Modified Naranjo Algorithm, *Pulsatilla nigricans*, repertorisation, ringworm, tinea capitis

## INTRODUCTION

Tinea represents the superficial fungal infection of skin, hair and nails caused by dermatophytes. Depending upon the location of the infection on the body, it is named variously as T. capitis (scalp), T. faciei (face), T. corporis (trunk), T. cruris (groin), T. pedis (feet), T. manuum (hand) and T. unguium (nails).<sup>[1]</sup> Tinea is also known as ringworm or dermatophytosis.<sup>[2]</sup> Tinea capitis is primarily caused by dermatophytes in the genera *Trichophyton* and *Microsporum* that invade the hair shaft.<sup>[3]</sup>

Its incidence has increased in India over the past decade, with prevalence ranging between 6.09% and 61.5%.<sup>[4-6]</sup> They are widespread in developing countries, especially in tropical and subtropical countries such as India, where the environmental temperature and relative humidity are high.<sup>[7]</sup> They generally get worse during the summer and the rainy season and tend to get better spontaneously during winter. Transmission of the infection takes place either through direct contact with organisms from humans, animals or soil

or indirectly through fomites such as hats and hairbrushes.<sup>[2,8]</sup> Lesions may appear as thickened, scaly and sometimes boggy swellings or as expanding raised red rings with severe itching of the scalp, dandruff and bald patches with variable degrees of inflammation.<sup>[4]</sup> Kerion, a variety associated with highly inflamed areas of tinea capitis, may lead to scarring alopecia.<sup>[8]</sup> It is not necessary to see the well-defined, centrifugally spreading lesions with central clearing now due to steroid-modified tinea, double-edged tinea, eczematous lesions and tinea that mimic other dermatoses.<sup>[4]</sup>

Accurate diagnosis at an early stage is the first and foremost step in control of the spread of infection. The diagnosis of dermatomycoses is primarily established by observation of clinical manifestations and by the characteristic distribution of lesions. When necessary, direct examination

**\*Address for correspondence:** Khushboo Garg,  
Central Council for Research in Homoeopathy, New Delhi, India.  
E-mail: khushboogarg.20@gmail.com

**Received:** 28 February 2023; **Accepted:** 24 November 2023

### Access this article online

#### Quick Response Code:

Available in print  
version only

**Website:**  
www.ijrh.org

**DOI:**  
10.53945/2320-7094.1833

This is an open access journal, and articles are distributed under the terms of the Creative Commons Attribution-NonCommercial-ShareAlike 4.0 License, which allows others to remix, tweak, and build upon the work non-commercially, as long as appropriate credit is given and the new creations are licensed under the identical terms.

**How to cite this article:** Garg K, Bansal D, Mittal A. Tinea capitis treated with homeopathic medicine *Pulsatilla nigricans*: A case report. Indian J Res Homoeopathy 2023;17:241-248.

is performed for diagnostic confirmation.<sup>[9]</sup> The scope of conventional treatment in these cases is limited due to the invariable use of oral antifungal and steroids which reduce the immunity, and only suppress the condition, leading to recurrence of infection with more intensified symptoms or secondary bacterial infections. This study has opted with the rising incidence of tinea infections in India to ascertain the usefulness of homoeopathic medicines. Homoeopathy treats the patients based on symptom similarity, the totality of symptoms and individualisation, much before the diagnosis is established, which increases its significance further over other conventional treatments. There are many well-evident case reports and clinical trials for the treatment of tinea in Homoeopathy, especially of tinea cruris and corporis.<sup>[10-17]</sup> However, very little scientific evidence was found in support of Homoeopathy in the treatment of tinea capitis in the form of case reports or observational studies or clinical trials.<sup>[18]</sup> There are many specific medicines for tinea capitis such as *Sepia*, *Tellurium*, *Mezereum*, *Arsenic album* and *Sulphur* but this case report aspires to show the usefulness of homoeopathic medicines in the treatment of tinea capitis through an individualised constitutional approach. This case is being reported according to the HOM-CASE-CARE guidelines.<sup>[19]</sup>

## CASE SUMMARY

### Patient information

A 12-year-old girl presented in an outpatient clinic with the complaint of reddish, circular lesions with some vesicular and pustular eruptions on her scalp in March 2021. The patient was apparently well 3 months back when the eruptions started as small circular red patches on the scalp with a lot of itching, burning and hair loss. The eruptions bled on scratching. She also complained of pain in pustular lesions occasionally. Her appetite got reduced in the past 3 months, because of which she lost weight by 5 kg. All complaints were aggravated while sleeping in the night, around 2 am and from touching. She also took allopathic treatment for the same with no relief.

There was no significant family history of any disease. The patient studied in the eighth grade in school. She had no interest in studies. She desired to play outdoor games with her friends. She was very fond of dancing.

### Physical generals

The patient's appetite was very low since the time of the eruptions. She had a good appetite earlier. When hungry, she could not tolerate hunger and needed to have food immediately. The patient had a desire for sweet things. She did not like spicy and sour food. The thirst was reduced (2–3 glasses of water in a day). She preferred cold water for drinking. She could not tolerate hot weather. She felt so hot that she could even have a bath with cold water in winter, thus suggesting her hot thermal reaction. She had no complaints related to defecation or urination. Perspiration was normal but more on the scalp. There was no significant finding in gynaecological history; her menstruation cycles had not started at the time of reporting.

### Mental generals

She was an extroverted child. She hesitated initially when meeting new people, but once others started talking, she mixed up well. Sometimes, her parents had to stop her from talking much. Her parents also complained that she often used to forget words while talking. She liked outings and travelling to new places with family. When her parents did not take her out, she would be angry. However, she did not hold anger for long and used to get fine very soon when consoled. She was very affectionate. She liked to hug and kiss the people she loved, especially her parents. She used to weep easily at the slightest things, especially when talked rudely. She was afraid of the dark, being alone, of small animals such as mice or lizards. She used to take good care of her stuff but was careless with the belongings of others. She did not like sharing her toys with other children. She did not like studying. She liked dressing up, dancing and makeup. Her parents said that initially, she used to hesitate to go outdoors due to the associated hair loss, but later, it did not affect her much.

### Clinical findings and diagnostic assessment

Based on the clinical findings and history, this case was diagnosed as a case of tinea capitis. The patient had multiple erythematous, circular lesions all over the scalp, with some vesicular and pustular eruptions that presented as firm and smooth swelling. Bleeding was also visible in some of the lesions. Lesions were slightly tender to the touch. Severe hair fall was noted. The weight of the patient was 28 kg. Other physical parameters were normal.

### Case analysis and repertorisation

After the analysis of the case, the following characteristic signs and symptoms were considered for making the totality:

1. Frivolous
2. Affectionate in nature
3. Forgetfulness for words
4. Fear of darkness
5. Decreased thirst
6. Desire for sweets
7. Excoriating eruptions
8. Burning sensation in eruptions.

Repertorisation of the case was done through the Synthesis 9.0 version of RADAR software [Figure 1].

### Therapeutic intervention

After repertorisation, and further consultation with the materia medica, the homoeopathic medicine *Pulsatilla nigricans* was prescribed in the 200<sup>th</sup> potency in a single dose.<sup>[20,21]</sup> The medicine was dispensed in globules of size 30, four globules to be taken on an empty stomach, once a day. The patient was advised to report to the outpatient department after 2 weeks.

### Follow-up and outcomes

The patient was followed every fortnightly, or as and when required. Potency and repetition varied as per the requirement of the case depending upon the homoeopathic principles.<sup>[22]</sup> Details of the follow-up are summarised in Table 1. The




Figure 1: Repertorisation chart

Table 1: Follow-ups

Visit/Follow-up	Signs and Symptoms	Prescription with dose and repetition
02 March 2021 (Baseline visit)	Reddish, circular lesions on the scalp with itching, burning, pain and hair loss. Decreased appetite and loss of weight [Figures 2 and 3]	<i>Puls</i> 200/od/1 day Placebo/tds/15 days
17 March 2021	Erythema, pain, itching and burning in the areas of lesions were slightly better. Appetite improved. Reduction in hair loss.	Placebo/tds/15 days
05 April 2021	Further improvement in the signs and symptoms. Hair fall reduced further. New hair growth noted [Figure 4]	Placebo/tds/15 days
22 April 2021	No further improvement was noted.	<i>Puls</i> 200 – 1 dose, Placebo/tds/15 days
08 May 2021	Lesions and inflammation are reduced further in size and severity. Increased new hair growth was noted [Figure 5]	Placebo/tds/15 days
24 May 2021	Further improvement noted.	Placebo/tds/15 days
07 June 2021	No further improvement was noted.	<i>Puls</i> 1M – 1 dose, Placebo/tds/15 days
23 June 2021	Further improvement in the size and severity of the eruptions was noted. The appetite of the patient was much better. Hair growth continues. Reduction in the areas of bald patches.	Placebo/tds/15 days
10 July 2021	Improvement is continuing. Areas of inflammation markedly reduced [Figure 6]	Placebo/tds/15 days
26 July 2021	Condition static – no further improvement was noted.	<i>Puls</i> 1M/1 dose, Placebo/tds/15 days
11 August 2021	Areas of inflammation disappeared. Increased density of hair growth noted. Further reduction in the areas of patches of baldness [Figure 7]	Placebo/tds/15 days
27 August 2021	Increased hair growth noted. Further reduction in the areas of baldness.	Placebo/tds/15 days
14 September 2021	Markedly dense growth of hair on the scalp. A few patches of baldness were noted. No erythema, burning, itching or any other complaints noted. Weight: 31.5 Kg [Figure 8]	Placebo/tds/15 days

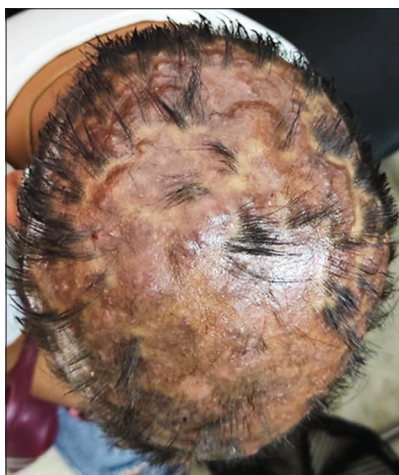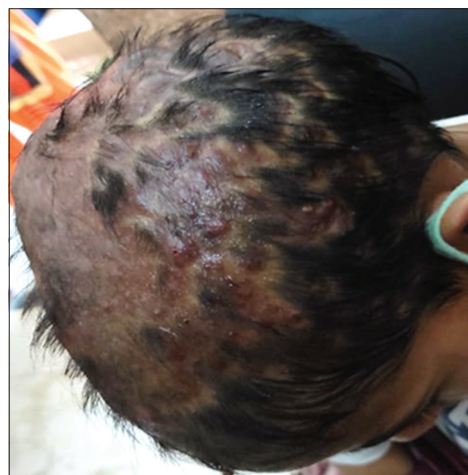tds: 3 times a day, od: once a day

adherence to the homoeopathic treatment was confirmed at every follow-up by the patient’s attendant. The patient showed marked improvement after beginning the homoeopathic treatment. Signs and symptoms kept on getting better with every follow-up. Further, after 3 months of treatment, when no further improvement was noted, *Pulsatilla nigricans* was prescribed in 1M potency and later repeated. Areas of inflammation reduced in size as well as severity. Pain, burning and itching gradually improved and reduced in intensity. Hair fall reduced, and new hair strands started appearing. Lesions reduced gradually and disappeared after 6 months. At the end of 6 months, markedly dense hair growth was noted. Patches of baldness reduced significantly. However, a few bald patches were noticeable. At every follow-up, the patient’s appetite became better with a gradual increase in weight. At the last

follow-up visit, a weight gain of 3.5 kg (31.5 Kg body weight) was reported as compared to the first visit (28 kg). During the final follow-up, the MONARCH Inventory was used to assess a causal relationship between homoeopathic intervention and the outcome of this clinical case.<sup>[23]</sup> The total score was 9, thus suggesting a ‘possible’ association between the medicine and the outcome [Table 2]. The patient showed remarkable improvement within 6 months of treatment [Figures 2-8]. The patient could not continue the regular follow-up visits further, due to her personal circumstances. However, the patient was followed up telephonically by the treating physician for another year during which the remaining bald patches disappeared gradually, and no recurrence of tinea was noted. No homoeopathic aggravation or adverse events were noticed during the entire period of treatment.

**Table 2: Monarch inventory assessment**

S. No.	Domains	Yes	No	Not sure or N/A
1.	Was there an improvement in the main symptom or condition for which the homoeopathic medicine was prescribed?	+2		
2.	Did the clinical improvement occur within a plausible timeframe relative to the drug intake?	+1		
3.	Was there a homoeopathic aggravation of symptoms?		0	
4.	Did the effect encompass more than the main symptom or condition (i.e. were other symptoms not related to the main presenting complaint improved or changed)?	+1		
5.	Did overall well-being improve? (improvement in the signs and symptoms as narrated by the patient herself and her parents, physician's own observation and clinical examination.)	+1		
6.	(A) Direction of cure: Did some symptoms improve in the opposite order of the development of symptoms of the disease?			0
	(B) Direction of cure: Did at least one of the following aspects apply to the order of improvement of symptoms: - From organs of more importance to those of less importance? - From deeper to more superficial aspects of the individual? - From the top downwards?	+1		
	Did 'old symptoms' (defined as non-seasonal and non-cyclical symptoms that were previously thought to have resolved) reappear temporarily during the course of improvement?		0	
	Are there alternative causes (i.e. other than the medicine) that – with a high probability – could have produced the improvement? (consider the known course of disease, other forms of treatment and other clinically relevant interventions)		+1	
	Was the health improvement confirmed by any objective evidence? (clinical examination and photographic evidence)	+2		
	Did repeat dosing, if conducted, create similar clinical improvement?		0	
	Total score=9			

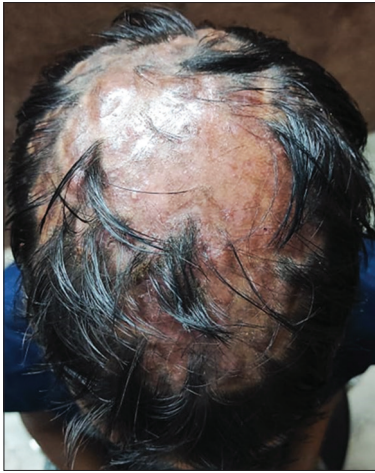**Figure 2:** Before treatment (2<sup>nd</sup> March 2021)**Figure 3:** Before treatment (2<sup>nd</sup> March 2021) (side view)

## DISCUSSION

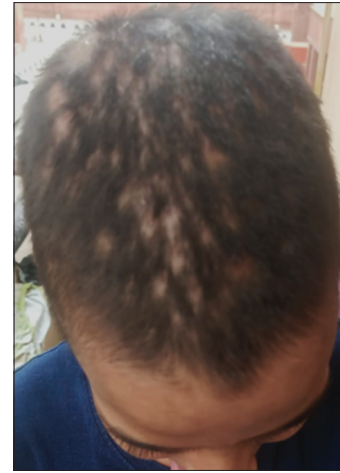This is a case of tinea capitis in a female child effectively treated with individualised homoeopathic medicine *Pulsatilla nigricans*. The case was diagnosed as that of tinea capitis based on the history of complaints and clinical examination. The treatment with the modern system of medicine (antifungal treatments, anti-inflammatory agents such as systemic steroids, antifungal shampoos and topical applications) is not only costly but also has potential side effects such as headache, gastrointestinal distress, taste disturbances, cutaneous eruptions and liver enzyme abnormalities.<sup>[24,25]</sup> The same has been described by Dr. Samuel Hahnemann in *Organon of Medicine* (aphorism 203), as ‘*this pernicious external mode of treatment,*

*hitherto so universally practised, has been the most prolific source of all the innumerable named or unnamed chronic maladies under which mankind groans*’.<sup>[22]</sup> The patient had already undergone allopathic treatment for 3 months with no significant relief.

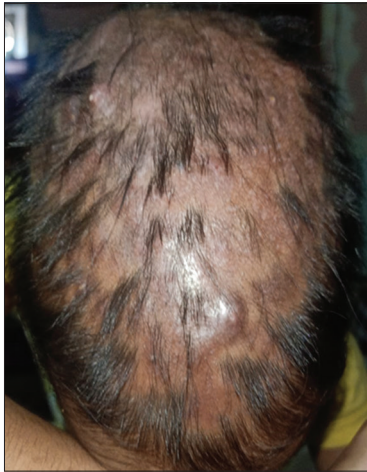Homoeopathy considers the patient as a whole, taking into account all the signs and symptoms to be part of his disease and works by improving immunity.<sup>[26]</sup> Homoeopathic medicines direct and stimulate the body's self-regulatory mechanisms to restore its natural equilibrium.<sup>[27]</sup> The treatment is customised individually with the objective of curing the patient while addressing the underlying cause of the disease. Various research articles have been published showing the positive role of Homoeopathy in the treatment of tinea.<sup>[10-18]</sup>



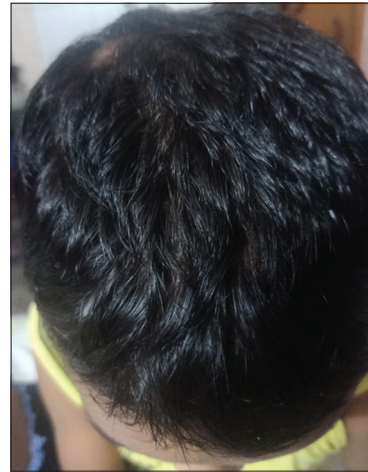**Figure 4:** Follow-up (5<sup>th</sup> April 2021)



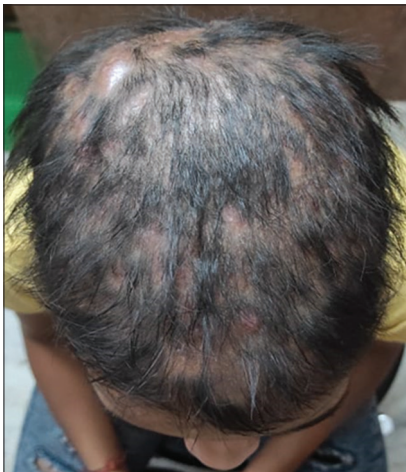**Figure 7:** Follow-up (11<sup>th</sup> August 2021)



**Figure 5:** Follow-up (8<sup>th</sup> May 2021)



**Figure 8:** Follow-up (14<sup>th</sup> September 2021)



**Figure 6:** Follow-up (10<sup>th</sup> July 2021)

As per aphorism no. 190, in *Organon of medicine*, sixth edition, 'all true medical treatment of a disease on the external parts of the body that has occurred from little or no injury from without must, therefore, be directed against the whole, must

*effect the annihilation and cure of the general malady by means of internal remedies, if it is wished that the treatment should be judicious, sure, efficacious and radical*'.<sup>[22]</sup> In this case, *Pulsatilla nigricans* was found to be the most indicated remedy homoeopathically which was prescribed in increasing potencies from 200 to 1M, as per the response from the patient, over 6 months, based on homoeopathic principles as shown in Table 1.

Hair fall started reducing within 15 days of starting the treatment. Signs and symptoms of inflammation, including redness, erythema, burning, pain and itching, kept on improving with every succeeding follow-up with new hair growth. Overall too, the patient felt better. There was marked improvement in appetite with a gain in weight of 3.5 kg at the last follow-up. During the follow-up, all her complaints decreased progressively, without any aggravation or the appearance of new or old symptoms which depicts that medicine and potency selection was correct as per homoeopathic principles.<sup>[28]</sup> At the last follow-up, the patient was free of tinea infection with adequately dense hair growth; however, a few patches of

baldness remained on the last day of follow-up at the clinic, which gradually disappeared with no recurrence or relapse of tinea as noted during telephonic follow-up till 1 year. Through the MONARCH inventory, the therapeutic power of homoeopathic medicine was evaluated through causal attribution, and the results indicated a 'possible' relationship between treatment and result [Table 2].<sup>[23]</sup> This case showed the usefulness of individualised Homoeopathy in the treatment of tinea capitis. This also shows homoeopathic treatment as a successful alternative and complementary therapy.

## CONCLUSION

This case demonstrates that individualised homoeopathic medicines are beneficial in treating cases of tinea capitis. Homoeopathy may improve the overall health condition in addition to improving the main clinical signs and symptoms with no side effects. However, this is a single case report and further well-designed, controlled trials are warranted to add to the existing evidence.

## Declaration of patient consent

The written consent of the patient's parents has been obtained for the publication of her reports and other clinical data in the journal. The parents acknowledge that her identity and name will be kept confidential.

## Financial support and sponsorship

Nil

## Conflicts of interest

None declared.

## REFERENCES

- Marks JG, Miller JJ. Lookingbill and Marks Principles of Dermatology. 4<sup>th</sup> ed. Noida: Elsevier; 2009. p. 24-6, 130.
- Khanna N. Illustrated Synopsis of Dermatology and Sexually Transmitted Diseases. 1<sup>st</sup> ed. Delhi: Pawaninder P Vij; 2007. p. 218-20.
- Hunter JA, Savin JA, Dahl MV. Clinical Dermatology. 2<sup>nd</sup> ed. Australia: Blackwell Publishing; 1995. p. 184-6.
- Hanumanthappa H, Sarojini K, Shilpashree P, Muddapur SB. Clinicomycological study of 150 cases of dermatophytosis in a tertiary care hospital in South India. *Indian J Dermatol* 2012;57:322-3.
- Kaur R, Panda PS, Sardana K, Khan S. Mycological pattern of dermatomycoses in a tertiary care hospital. *J Trop Med* 2015;2015:157828.
- Verma SB, Panda S, Nenoff P, Singal A, Rudramurthy SM, Uhrlass S, *et al.* The unprecedented epidemic-like scenario of dermatophytosis in India: I. Epidemiology, risk factors and clinical features. *Indian J Dermatol Venereol Leprol* 2021;87:154-75.
- Sahoo AK, Mahajan R. Management of tinea corporis, tinea cruris, and tinea pedis: A comprehensive review. *Indian Dermatol Online J* 2016;7:77-86.
- Schofield OM, Rees JL. Skin disease. In: Davidson's. Principles and Practice of Medicine. 20<sup>th</sup> ed. USA: Elsevier Ltd.; 2006. p. 1278.
- Pires CA, Cruz NF, Lobato AM, Sousa PO, Carneiro FR, Mendes AM. Clinical, epidemiological, and therapeutic profile of dermatophytosis. *An Brasil Dermatol* 2014;89:259-64.
- Gupta Y, Tuteja S, Acharya A, Tripathi V. Effectiveness of homoeopathy in tinea corporis and tinea cruris-a prospective, longitudinal observational study. *Int J Adv Ayurv Yoga Unani Siddha Homeopathy* 2021;10:618-27.
- Dixit AK, Giri N. Tinea corporis: An evidence-based case report treated with homoeopathic medicine Sepia. *Homoeopathic Links* 2020;33:33-40.
- Gupta Y, Sharma A, Sharma S. Tinea cruris treated with individualised homoeopathic medicine: An evidence-based case report. *Indian J Res Homoeopathy* 2023;17:181-6.
- Shukla I. Tinea faciei treated with constitutional homoeopathic medicine using vithoukka's compass: Two evidence-based case reports. *Indian J Res Homoeopathy* 2022;16:171-7.
- Laskar B, Paul S, Chattopadhyay A, Karuppusamy A, Balamurugan D, Bhakta P, *et al.* Individualized homeopathic medicines in the treatment of tinea corporis: Double-blind, randomized, placebo-controlled trial. *Homeopathy* 2023;112:74-84.
- Ram H, Singh U. Tinea faciei successfully treated with individualised homoeopathic medicine: A case report. *Homoeopathic Links* 2023;36:34-41.
- Roy PS, Tabassum SN, Das S, Fouzdar V, Hazra A, Goswami P. Efficacy of individualized homeopathic treatment in the management of dermatophytosis-a case series. *Int J Ayush Case Rep* 2021;5:321-32.
- Sharma R. Tinea corporis treated with homoeopathy. *Homoeopathic Links* 2020;33:327-8.
- Sherr J, Davy J, Saghai Z, Quirk T, Fibert P. The comparative effectiveness of the homeopathic medicine Bacillinum for ringworm (tinea): A pilot feasibility study. *Eur J Integr Med* 2022;53:102142.
- Van Haselen RA. Homeopathic clinical case reports: Development of a supplement (HOM-CASE) to the CARE clinical case reporting guideline. *Complement Ther Med* 2016;25:78-85.
- Boericke W. Boericke's New Manual of Homoeopathic Materia Medica with Repertory. 3<sup>rd</sup> ed. New Delhi: B Jain Publishers Pvt Ltd.; 2007. p. 475-8.
- Kent JT. Lectures on Homoeopathic Materia Medica. New Delhi: B. Jain Publishers Pvt Ltd.; 2006. p. 857-71.
- Hahnemann S. Organon of Medicine. 6<sup>th</sup> ed. New Delhi: B. Jain Publishers Pvt Ltd.; 2016.
- Lamba CD, Gupta VK, Van Haselen RA, Rutten L, Mahajan N, Molla AM, *et al.* Evaluation of the Naranjo criteria for assessing causal attribution of clinical outcome to homoeopathic intervention as presented in case reports. *Homeopathy* 2020;109:191-7.
- Al Aboud AM, Crane JS. Tinea capitis. In: Stat Pearls. Treasure Island, FL: Stat Pearls Publishing; 2022. Available from: <https://www.ncbi.nlm.nih.gov/books/NBK536909> [Last assessed on 2023 Jan 16].
- James RT. In: Post TW, editor. Tinea Capitis Treatment. Waltham, MA: UpToDate; 2022. Available from: <https://www.uptodate.com/contents/tinea-capitis#H949998314> [Last accessed on 2023 Jan 16].
- Gupta VK, Mathur M. Immunomodulatory effects of homoeopathic medicines: A review of pre-clinical studies. *Indian J Res Homoeopathy* 2018;12:90-4.
- Central Council for Research in Homoeopathy. Homoeopathy for Common Diseases. New Delhi: CCRH; 2016. p. 1.
- Kent JT. Lectures on Homoeopathic Philosophy. New Delhi: B. Jain Publishers Pvt Ltd.; 1999. p. 174-8, 224-34.

## Tinea Capitis traité avec un médicament homéopathique *Pulsatilla nigricans*: Un rapport de cas

**Introduction:** L'infection à Tinea est une plainte fréquente rencontrée dans la pratique quotidienne avec une incidence croissante, en particulier dans des pays comme l'Inde au cours de la dernière décennie. Tinea capitis est principalement une maladie des enfants prépubères caractérisée par des lésions de morphologie variable sur le cuir chevelu associées à des démangeaisons, des érythèmes, des signes d'inflammation et de perte de cheveux. Une reconnaissance et un traitement rapides sont nécessaires pour empêcher sa propagation en raison de sa nature contagieuse, de la perte de cheveux qui y est associée et de l'impact psychologique qui en résulte sur la vie sociale. Le traitement homéopathique individualisé a une portée significative dans le traitement et la lutte contre de telles affections de manière rentable à travers la totalité des symptômes.

**Résumé du cas:** Une fillette de 12 ans présentée à une clinique ambulatoire avec des lésions érythémateuses et circulaires avec des démangeaisons, des douleurs brûlantes et des chutes de cheveux. *Pulsatilla nigricans* 200 a été prescrit initialement et plus tard *Pulsatilla* 1M a été prescrit selon les principes homéopathiques. L'affaire a fait l'objet d'un suivi bimensuel pendant six mois. Le patient a été traité avec succès avec une amélioration marquée des signes et des symptômes (en particulier pendant la saison des pluies, qui est la période habituelle d'aggravation des infections à teigne) en 6 mois, sans aggravation ni événements indésirables. Le score modifié des critères de Naranjo a été utilisé pour établir l'attribution causale au médicament prescrit, avec un score total de 9. Ce rapport de cas suggère que les médicaments homéopathiques individualisés sont utiles dans le traitement de la teigne de la tête.

## Tinea Capitis behandelt mit dem homöopathischen Arzneimittel *Pulsatilla nigricans*: Ein Fallbericht

**Einleitung:** Die Tinea-Infektion ist eine häufige Beschwerde, die in der täglichen Praxis mit zunehmender Häufigkeit auftritt, insbesondere in Ländern wie Indien in den letzten zehn Jahren. Tinea capitis ist in erster Linie eine Erkrankung präpubertärer Kinder, die durch Läsionen unterschiedlicher Morphologie auf der Kopfhaut gekennzeichnet ist, die mit Juckreiz, Rötung, Entzündungszeichen und Haarausfall einhergehen. Eine rasche Erkennung und Behandlung ist notwendig, um eine Ausbreitung der Krankheit zu verhindern, da sie ansteckend ist, mit Haarausfall einhergeht und sich auf das soziale Leben auswirkt. Eine individualisierte homöopathische Behandlung hat einen bedeutenden Spielraum bei der kosteneffizienten Behandlung und Bekämpfung solcher Erkrankungen durch die Gesamtheit der Symptome. **Zusammenfassung des Falles:** Ein 12-jähriges Mädchen stellte sich in einer Ambulanz mit erythematösen und kreisförmigen Läsionen mit Juckreiz, brennenden Schmerzen und Haarausfall vor. Zunächst wurde *Pulsatilla nigricans* 200 und später *Pulsatilla* 1M gemäß den homöopathischen Prinzipien verordnet. Der Fall wurde sechs Monate lang alle zwei Wochen nachuntersucht. Die Patientin wurde erfolgreich behandelt. Innerhalb von 6 Monaten zeigten sich deutliche Verbesserungen der Anzeichen und Symptome (vor allem während der Regenzeit, der üblichen Zeit für eine Verschlimmerung der Tinea-Infektionen), ohne dass es zu einer Verschlimmerung oder zu unerwünschten Ereignissen kam. Der modifizierte Naranjo-Kriterien-Score wurde verwendet, um die kausale Zuordnung zur verordneten Arznei festzustellen, mit einer Gesamtpunktzahl von 9. Dieser Fallbericht legt nahe, dass individualisierte homöopathische Arzneimittel bei der Behandlung von Tinea capitis nützlich sind.

## होम्योपैथी दवा पल्सेटिला नाइग्रिकेन्स से टिनिया कैपिटिस का इलाज किया गया: एक केस रिपोर्ट

**परिचय:** टिनिया संक्रमण एक आम शिकायत है जो कि भारत जैसे देशों में, खासकर पिछले दशक में काफी बार देखा गया है। टिनिया कैपिटिस मुख्य रूप से प्रीप्युबर्टल बच्चों की एक बीमारी है जिसमें खुजली, त्वचा पर लाल दाने, सूजन और बालों के झड़ने के साथ सिर की त्वचा पर विभिन्न प्रकार के निशान और घाव होते हैं। इसकी संक्रामक प्रकृति और सामाजिक जीवन पर होने वाले मनोवैज्ञानिक प्रभाव के कारण इसके प्रसार को रोकने के लिए शीघ्र पहचान और उपचार आवश्यक है। लक्षणों के आधार पर व्यक्तिगत होम्योपैथी उपचार द्वारा ऐसी बीमारियों का प्रभावी इलाज कम लागत से हो सकता है। **केस सारांश:** एक 12 वर्षीय लड़की को खुजली, जलन दर्द और बालों के झड़ने के साथ सिर की त्वचा पर लाल दाने और गोलाकार घावों के साथ एक बाह्य रोगी क्लिनिक में लाया गया। होम्योपैथी सिद्धांतों के आधार पर पल्सेटिला नाइग्रिकेन्स 200 पेहेले दी गई और बाद में पल्सेटिला 1 एम दी गई। छह महीने तक इस केस का फोलोअप किया गया। रोगी का 6 महीने के भीतर निशानों और लक्षणों में उल्लेखनीय सुधार (विशेष रूप से बरसात के मौसम के दौरान, जो टिनिया संक्रमण के बढ़ने का सामान्य समय होता है) के साथ सफलतापूर्वक इलाज किया गया, जिसमें कोई वृद्धि या प्रतिकूल असर नहीं हुआ। संशोधित नारंजो मानदंड स्कोर का उपयोग निर्धारित दवा को कारण स्थापित करने के लिए किया गया था, कुल स्कोर 9 था। इस केस रिपोर्ट से पता चलता है कि व्यक्तिगत होम्योपैथिक दवाएं टिनिया कैपिटिस के उपचार में उपयोगी हैं।

## Tinea Capitis tratada con el medicamento homeopático *Pulsatilla nigricans*: Informe de un caso

**Introducción:** La tiña de la cabeza es una afección frecuente en la práctica diaria, con una incidencia cada vez mayor, especialmente en países como la India en la última década. La tiña de la cabeza es predominantemente una enfermedad de niños prepubéres caracterizada por lesiones de morfología variable en el cuero cabelludo asociadas a picor, eritema, signos de inflamación y pérdida de cabello. Su reconocimiento y tratamiento rápidos son necesarios para prevenir su propagación debido

a su naturaleza contagiosa, la pérdida de cabello asociada y el impacto psicológico resultante en la vida social. El tratamiento homeopático individualizado tiene un alcance significativo en el tratamiento y la lucha contra tales condiciones de manera rentable a través de la totalidad de los síntomas. **Resumen del caso:** Una niña de 12 años se presentó en una consulta externa con lesiones eritematosas y circulares con prurito, dolor urente y caída del cabello. Inicialmente se prescribió *Pulsatilla nigricans* 200 y posteriormente *Pulsatilla* 1M según los principios homeopáticos. Se realizó un seguimiento quincenal del caso durante seis meses. El paciente fue tratado con éxito, con una marcada mejoría de los signos y síntomas (especialmente durante la estación lluviosa, que es la época habitual de agravamiento de las infecciones por tiña) en 6 meses, sin agravamiento ni acontecimientos adversos. Para establecer la atribución causal al medicamento prescrito se utilizó la Puntuación de Criterios Naranjo Modificada, con una puntuación total de 9. Este informe de caso sugiere que los medicamentos homeopáticos individualizados son útiles en el tratamiento de la Tinea capitis.

## 用 势 法 物白头翁治 : 一系列病例报告

**引言:** 感染是日常生活中常 的疾病, 病率不断上升, 尤其是在过去十年中, 在印度等国家。头 主要是一种青春前儿童的疾病, 其特征是头皮上的各种形 的病 , 伴有瘙痒、 斑、炎症迹象和脱 。由于其 染性、相 脱 以及由此对社会生活 生的心理影响, 及时 别和治 对于防止其 播是必要的。个体化 势 法治 在通过整个症状 有效地治 和对抗这种情况方面具有重要的范 。**病例** : 一名12 女孩在 就 时出 斑和 形病 , 伴有瘙痒、灼痛和脱 。最初 出白头翁200, 后来根据 势 法原理 出白头翁1M。 病例每两周随 一次, 随 时 六个月。患者在6个月内得到成功治 , 体征和症状 著改善 (尤其是在雨季, 这是 感染加重的常 时 ), 没有加重和不良事件。使用改良Naranjo 准 分来确定处方 的因果归因, 分 9分。 病例报告表明, 个体化的 势 法 物可用于治 头 。