

Effectiveness of individualised homoeopathic intervention in warts – A case series

P. Dastagiri¹, S. G. S Chakravarthy¹, Renu Mittal²

¹National Homoeopathy Research Institute in Mental Health, Kottayam, Kerala, India, ²Central Council for Research in Homoeopathy, New Delhi, India

Abstract

Verruca vulgaris, also known as common warts, is benign lesions caused by the non-malignant human papillomavirus, affecting approximately 10% of the population globally. It may range from 1 mm to several cm, and are mostly seen on the extremities, followed by the face. They may be transmitted by direct or indirect contact and lead to cosmetic concerns, itching and mild to severe pain while doing activities. Conventional treatment has destructive therapies such as salicylic acid, cauterisation and cryosurgery, which induce many adverse effects from local to general. However, an individualised homoeopathic approach can be used to effectively treat these warts, without any need of applying topicals, or recurrence of the complaints. The improvement was assessed through photographic records. This case series provides an insight to individualised homoeopathic intervention in different types of warts and paves the way for pragmatic studies in the future.

Keywords: Warts, Individualisation, Homoeopathy, MONARCH

INTRODUCTION

Verruca vulgaris, also known as common warts, is categorised under the International Classification of the Disease (ICD-10) code - B07.8. These are benign lesions caused by the non-malignant human papillomavirus (HPV); as yet, 100 types have been identified. Most commonly, type 2 and 4, followed by types 1, 3, 27, 29 and 57, cause these common warts. Globally, approximately 10% of the population is affected by these complaints.^[1] The prevalence is higher in school-going children of 12 -16 years, and in males, nearly twice that of females, due to increased outdoor activities.^[2]

HPV may occur at any site. However, the primary manifestations of HPV infection include common warts (verruca vulgaris), anogenital warts, flat warts (verruca plana), plantar warts (verruca plantaris), deep palmoplantar warts (myrmecia), focal epithelial hyperplasia and Epidermodysplasia verruciformis.^[3] These warts may range from 1 mm to several cm, and are mostly seen on the extremities, or on the face.^[4] They may be transmitted by direct or indirect contact. Events that disrupt the normal epithelial barrier increase the likelihood of developing this illness.^[1] Mostly, it may lead to cosmetic concerns, itching and mild to severe pain while doing activities, especially plantar warts.^[2,3]

In most cases, conventional therapies such as the application of salicylic acid, trichloroacetic acid, silver nitrate, cauterisation, cryotherapy, retinoic acid, podophyllin, topical 5-fluorouracil, interferon, lasers, antiviral agents and anti-proliferative agents are used.^[1] This treatment leads to many adverse effects, ranging from localised to generalised ones, such as local burning sensation, erythema, blistering, pain/postoperative pain, hyperpigmentation/hypopigmentation, scarring, prolonged wound healing, petechiae, purpura and crusting, urticaria, nausea, vomiting, dizziness, headaches, rise in leukocytes, hematocrit value and aminotransferase levels, based on the procedures.^[5,6]

Homoeopathy, a personalised medicine, is based on totality of symptoms of the patient, comprising of mental and physical make up, apart from the particular (disease-related) symptoms to determine the similimum.^[7] Publishing case reports or case series requires proper documentation. Reporting cases enhance the knowledge of medicine and aids in building

***Address for correspondence:** Dr. P. Dastagiri,
National Homoeopathy Research Institute in Mental Health,
Kottayam - 686 532, Kerala, India.
E-mail: pdastagiri@ccrhindia.nic.in

Received: 13 November 2022; **Accepted:** 12 September 2023

Access this article online

Quick Response Code:



Website:
www.ijrh.org

DOI:
10.53945/2320-7094.1299

This is an open access journal, and articles are distributed under the terms of the Creative Commons Attribution-NonCommercial-ShareAlike 4.0 License, which allows others to remix, tweak, and build upon the work non-commercially, as long as appropriate credit is given and the new creations are licensed under the identical terms.

How to cite this article: Dastagiri P, Chakravarthy SG, Mittal R. Effectiveness of individualised homoeopathic intervention in warts – A case series. *Indian J Res Homoeopathy* 2023;17:187-198.

medical literature.^[8] Various publications on warts treated with homoeopathic intervention have been published.^[9-13] Dey *et al.* mentioned in their research that the efficacy of individualised homoeopathic intervention on common warts is inconclusive.^[14] However, the fourteen evidence-based cases reported here suggest the usefulness of individualised homoeopathy in warts without adverse effects or recurrence of the complaints for more than 2–5 years.

METHODOLOGY

Fourteen warts cases, which include nine cases of *verruca vulgaris*, four of *verruca plana* and one case of *verruca plantaris* reported in this case series, consulted the outpatient department of National Homoeopathy Research Institute in Mental Health, Kottayam, from May 2017 to November 2021.

A detailed case taking was done for every case, according to the homoeopathic principles and after arriving at the totality, it was analysed, thoroughly evaluated, and repertorised by Hompath Classic M.D. Version 8 software, (Mind Technologies Pvt. Ltd., 2002, Mumbai, Maharashtra, India), using Complete Repertory and Synthesis Treasure edition 2009v (Schroyens F, Radaropus 2.2.16). From the repertorial result, the top three remedies were considered and then the other remedies were excluded by the elimination method.^[15] The final remedy was selected after verifying the symptoms with the homoeopathic *Materia Medica*.^[16] In this series, we have mentioned only the prescribing totality of symptoms.

Each case was treated with a single medicine, indicated according to the principles of Homoeopathy, starting with 30C potency, administered orally and repeated based on the individual's susceptibility. All the medicines were dispensed from the institute's pharmacy, which sources medicines from a Good Manufacturing Practice (GMP)-certified firm. In all the cases, the expected outcome was either decreased size or the disappearance of warts within a plausible time frame after medical intervention. Each case was evaluated with the MONARCH^[17] inventory (Modified Naranjo Criteria for Homoeopathy), for the causal attribution between the clinical outcome and homoeopathic intervention. In addition, during the follow-ups, we observed changes in the signs and symptoms and any adverse events in each case. We prescribed a placebo if the patient was improving or repeated the indicated medicine if improvement ceased.^[18]

CASE REPORTS

Case 1

A 22-year-old female, working as a nurse, presented on 26 May 2017 with complaints of multiple warts (9 in number) since 6 months. Four warts were present on the left thumb, two on the left index finger and three on the left middle finger, the largest of which measured around 1 cm; was painful during work and had a dark discoloration.

The lady was sensitive to sad stories and got easily offended.

She was fond of dancing, desired spices, was averse to onions and could not tolerate cold weather.

On repertorisation, *Sepia* - 13/8, *Lycopodium clavatum* - 12/7, *Nitric acid* - 12/7 and *Natrum muriaticum* - 10/7 came forth in hierarchy. *Sepia* 30C, was prescribed, a dose to be taken on an empty stomach, once every 15 days, followed by similar-looking placebo globules for 1 month.

Follow-up, observations and prescription

2nd visit (23 June 2017) - The size of all warts decreased; placebo was prescribed for one month.

3rd visit (07 July 2017) - All the warts disappeared; placebo was prescribed for 1 month [Figure 1a and b: Pre- and post-treatment].

Case 2

On 15 December 2017, a 6-year-old female, presented with multiple warts (five) on her left-hand index finger, the largest measuring 1 cm; it was painful to touch and itching with a hard surface for 1 year. She had taken homoeopathic treatment 3 months before without any improvement. At the age of 3 years, she had a history of measles, took conventional treatment and had an uneventful recovery.

She loved dancing and desired sweets and spices, complained of excessive perspiration on her palms, preferred to sleep on her abdomen and were intolerant to cold weather.

Sepia - 20/10, *Sulphur*-8/9 and *Calcarea carbonica* - 15/8 came in the repertorial hierarchy. *Sepia* 30C was prescribed, a dose to be taken on an empty stomach, once every 15 days, followed by similar-looking placebo globules for 1 month.

Follow-up, observations and prescription

2nd visit (19 January 2018) – All the warts decreased in size; placebo was prescribed for 1 month.

3rd visit (02 March 2018) – All warts completely disappeared; placebo was prescribed for 1 month [Figure 2a and b: Pre- and post-treatment].

Case 3

A 14-year-old boy, on 27 April 2018, presented with six warts on his right-hand thumb, index and middle fingers close to the nails since 2 years. The largest measured 1 cm, brownish in colour, with mild itching and occasional pain. He had tried

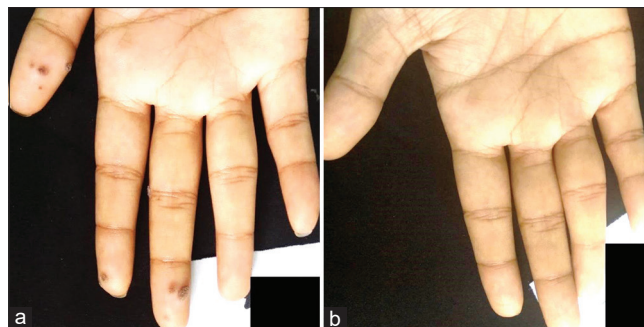


Figure 1: Case 1 - (a) Pre-treatment. (b) Post-treatment

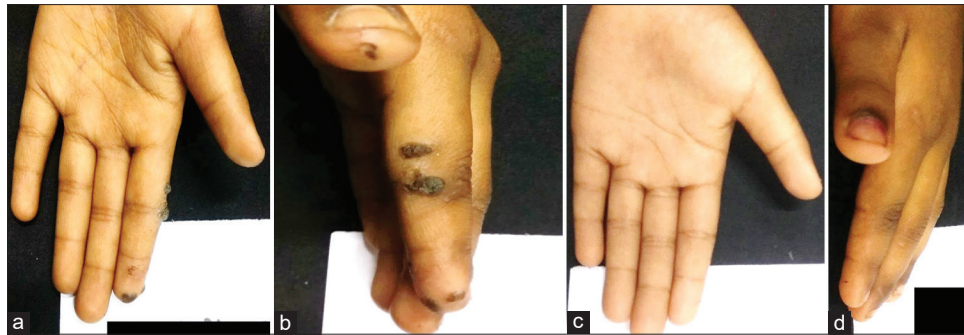


Figure 2: Case 2 - (a) pre-treatment, (b) case 2 - pre-treatment, (c) post-treatment, (d) Post-treatment

both conventional and homoeopathic treatment without relief and was under no medication at the time of reporting.

He was anxious, afraid of doing new work and sensitive to criticism. He was excessively thirsty and desired fish and chocolate. He had headaches aggravated by the sun and could not bear heat.

On repertorisation, *Natrum Muriaticum* - 13/7, *Calcarea carbonica* - 9/5 and *Causticum* - 9/4 had the maximum score. After eliminating the other chilly remedies, *Natrum Muriaticum* 30C was prescribed, to be taken once on an empty stomach and repeated every 15 days.

Follow-up, observations and prescription

2nd visit (25 May 2018) – All warts disappeared; placebo was prescribed for 1 month [Figure 3a and b: Pre- and post-treatment].

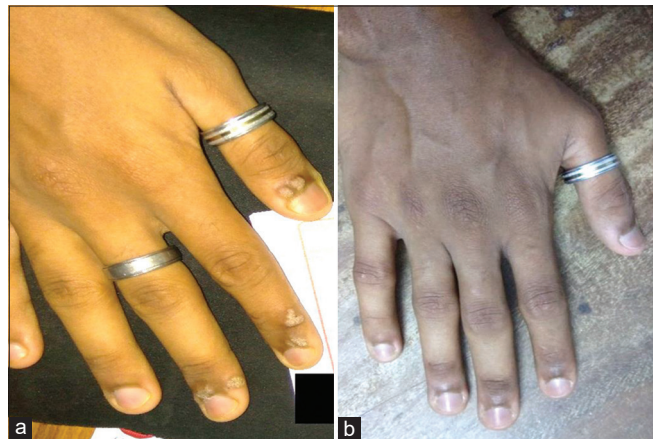

Figure 3: Case 3 - (a) Pre-treatment, (b) Post-treatment

Case 4

An 11-year-old student, on 06 July 2018, presented with warts on his left index finger and right thumb near the nail, with a black discolouration, for 1 year. He took homoeopathic treatment without relief. Both his parents had eczema.

He was afraid of dogs, was easily startled by noises, had an aversion to vegetables and was intolerant to cold.

On repertorisation, *Causticum*- 14/6, *Natrum muriaticum* 11/6 and *Calcarea carbonica* 8/4 -came on hierarchy. *Causticum* 30C was prescribed in two consecutive doses, to be repeated every 15 days.

Follow-up, observations and prescription

2nd visit (02 November 2018) - The patient’s mother informed us that after taking the medicine, all warts subsided within a month. Unfortunately, they did not attend the regular follow-ups due to personal reasons. No other complaints were reported and placebo was prescribed for 1 month [Figure 4a and b: Pre- and post-treatment].

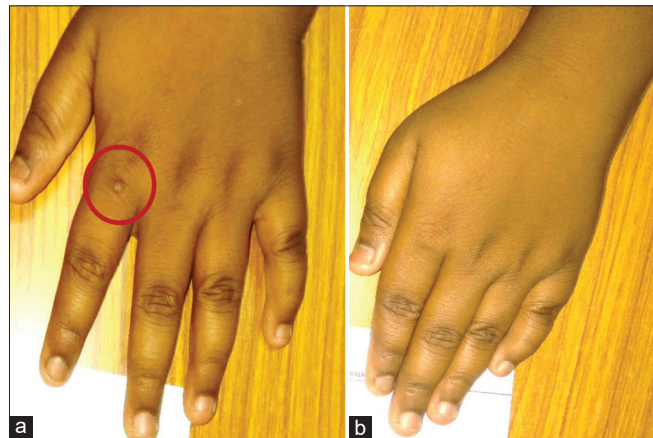


Figure 4: Case 4 - (a) Pre-treatment, (b) Post-treatment

Case 5

A 16-year-old male student presented with multiple warts (six) on her left thumb and index fingers, the largest measuring 1 cm, with severe itching and pain for 1 year, on 25 January 2019. His father had psoriasis vulgaris and

bronchial asthma.

He was timid, reported of increased perspiration on his palms and soles during mental exertion, desired sweets and fish, preferred to sleep on his abdomen and was intolerant to cold weather.

On repertorisation, *Silicea terra* - 18/8, *Calcarea carbonica* - 17/8 and *Lycopodium Clavatum* - 16/8 came up as the top-scoring medicines. *Silicea* 30C was prescribed, a dose to be taken on an empty stomach, once every 15 days, followed by similar-looking placebo globules for 1 month.

Follow-up, observations and prescription

2nd visit (08 February 2019) – All warts disappeared, and a placebo was prescribed for one month [Figure 5a and b: Pre- and post-treatment].

Case 6

A 28-years-old female, a homemaker, reported on 22 October 2020, with multiple warts (five) on hands, more on the right hand and left middle finger, the largest one measured one cm. There was severe itching and pain in the warts since 1 year. The warts started to appear on the right hand and had spread to the left. She had a history of allergic bronchial asthma and was treated by modern medicine. Her mother had Burkitt's lymphoma and bronchial asthma and her father had dyslipidemia and hypertension.

She was sensitive to noise, got easily offended and desired meat. Her menses were regular, but since 6 months, she experienced mild dysmenorrhoea or leucorrhoea, worse before menses with increased itching, offensive smell and intolerance to cold air.

On repertorisation, *Sepia* - 20/8, *Calcarea carbonica* - 19/8 and *Nitric acid* - 18/8 came as the top three medicines. *Sepia* 30C, was prescribed, a dose to be taken on an empty stomach, once every 15 days, followed by similar-looking placebo globules for 1 month.

Follow-up, observations and prescription

2nd visit (16 December 2020) – Mild decrease in the size of warts, leucorrhoea better with mild itching, less odour compared to earlier. No new complaints were reported. *Sepia* 30C, a dose every 15 days, was prescribed for 1 month.

3rd visit (21 January 2021) - All warts disappeared, leucorrhoea was better; placebo for 1 month [Figure 6a and b: Pre- and post-treatment].

Case 7

On 6 November 2020, a 14-year-old male student presented with multiple warts (12) on both his hands, more on both the index fingers and left thumb. The largest one measured one cm. The warts caused severe itching and pain since 1 year, but since 4 months, he even had bleeding from warts.

The patient had a stammering speech, which increased during presentations at school. He desired spicy things and had constipation, passed hard stools and was intolerant to cold.

On repertorisation, *Causticum* - 22/9, *Lycopodium clavatum* - 17/9 and *Sulphur* - 14/8 showed up with the maximum scores. *Causticum* 30C was prescribed based on overall symptomatology and to be taken once every 15 days.

Follow-up, observations and prescription

2nd visit (18 December 2020) – All warts subsided, constipation was better; placebo was prescribed for 1 month [Figure 7a-f: Pre- and post-treatment].

Case 8

A 15-year-old female student reported on 2 February 2021 with multiple warts (three) on her right middle finger, with

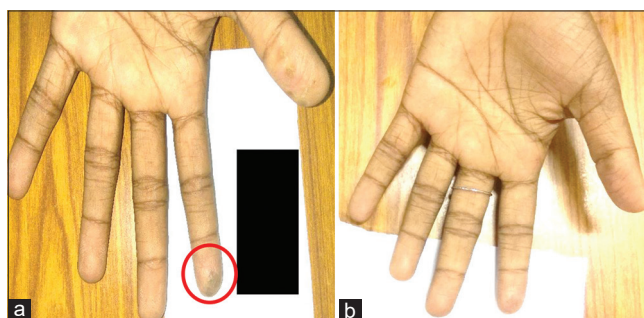


Figure 5: Case 5 - (a) Pre-treatment, (b) Post-treatment

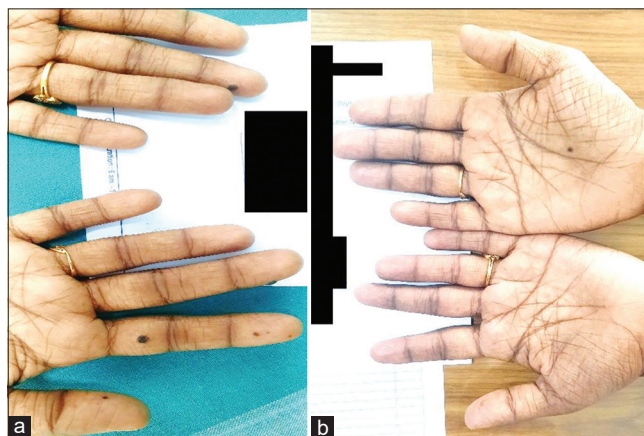


Figure 6: Case 6 - (a) Pre-treatment, (b) Post-treatment

mild itching and pain for 3 months. The most prominent wart was around one cm. She was also suffering from seizures since 5 years and was under conventional treatment for the same.

She suffered from anxiety with palpitation, but was very communicative. She found it very difficult to concentrate on her studies. She dreamed occasionally of snakes, desired pickles and felt very thirsty. She was intolerant to heat. During her convulsive episode, she was reported to lose consciousness and turned her eyes upward.

On repertorisation, *Lachesis* - 15/9, *Sepia* - 13/7 and *Sulphur* - 13/6 covered the maximum scores. *Lachesis* 30C was prescribed for 1 month, a dose to be taken once every 15 days.

Follow-up, observations and prescription

2nd visit (2 March 2021) – No change in the complaints. *Lachesis* 30C was repeated once every 15 days, for 1 month.

3rd visit (13 April 2021) - All warts on the fingers subsided: Placebo was prescribed for 1 month [Figure 8a and b: Pre- and post-treatment].

Case 9

A 12-year-old female student reported on 02 March 2021 with multiple black warts (seven) on his right thumb, with mild itching and pain for 3 months. The largest wart measured one cm. She did not take any treatment, nor was any relevant

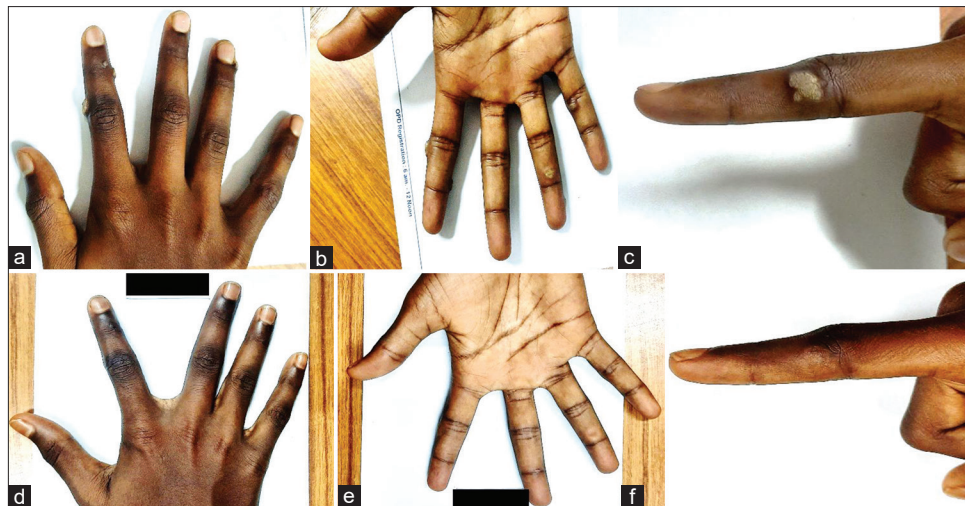


Figure 7: Case 7 - (a) Pre-treatment, (b) post-treatment, (c) pre-treatment, (d) post-treatment, (e) post-treatment, (f) post-treatment

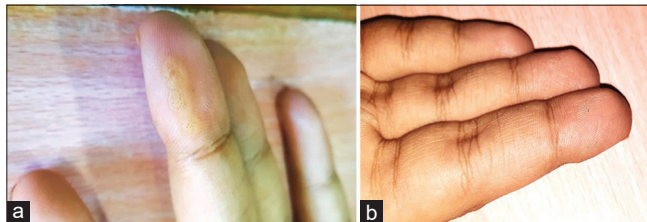


Figure 8: Case 8 - (a) Pre-treatment, (b) Post-treatment

history observed. Her sister also reportedly had warts on her fingers.

She spoke less during the consultation, liked being taciturn and reserved and always preferred dressing in male-like attire. She desired sweets, had an aversion to meat, and intolerance to sun exposure or heat.

On repertorisation, *Natrum muriaticum* - 19/11, *Calcarea carbonica* - 16/8 and *Sulphur* - 16/8 covered the maximum score on repertorial analysis. *Natrum muriaticum* 30C was prescribed, a dose to be taken on an empty stomach, once every 15 days.

Follow-up, observations and prescription

2nd visit (13 April 2021) - All warts disappeared; placebo was prescribed for 1 month. [Figure 9a-d: Pre- and post-treatment].

Case 10

A 6-and-a-half-year-old female student presented with brown-coloured warts on her scalp on 5 March 2021. The wart caused mild itching and pain while combing the hair since 5 months. She had taken homoeopathic treatment without relief. No relevant past or family history was observed, except that the mother also had warts.

She feared being alone and always desired her mother's company. She desired sweets and was intolerant to cold.

On repertorisation, *Sepia* - 9/5, *Kali carbonica* - 5/3 and *Thuja*- 4/3 scored the highest. *Sepia* 30C was prescribed, a dose to be taken once every 15 days.

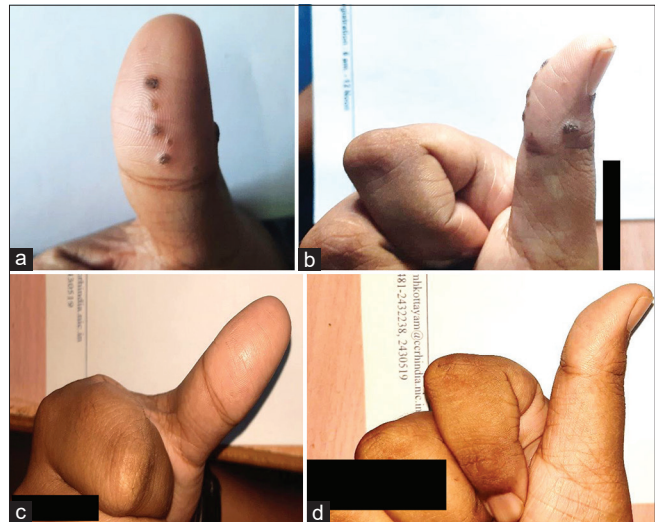


Figure 9: Case 9 - (a) Pre-treatment, (b) post-treatment, (c) pre-treatment, (d) post-treatment

Follow-up, observations and prescription

2nd visit (09 April 2021) - Warts on the scalp subsided; placebo was prescribed for 1 month [Figure 10a and b: Pre- and post-treatment].

Case 11

A 31-years-old female, a postmaster, presented at the OPD on 05 March 2021 with a wart on her forehead and multiple warts (9 in number) on her hands on the right thumb and index fingers since 2.5 years; one wart each on the left thumb, index finger, middle fingers and ring fingers (closer to the nails). Further, she had mild itching and pain. She had taken infrequent doses of the homoeopathic medicine *Thuja occidentalis* 30C and 200C internally and applied mother tincture *Thuja occidentalis* externally, without relief. No relevant past or family history could be obtained, except her daughter (Case no. 10) had warts on the scalp.

She feared ghosts and always desired company. She desired sweets and was intolerant to cold.

On repertorisation, *Sepia* - 14/9, *Sulphur* - 14/8 and *Causticum* - 17/7 scored the highest. *Sepia* 30C was prescribed, to be taken once every 15 days.

Follow-up, observations and prescription

2nd visit (09 April 2021) – Size of warts on the forehead and hands decreased. No other new complaints were observed; placebo was prescribed for 1 month.

3rd visit (07 May 2021) – All warts subsided; placebo prescribed for 1 month [Figure 11a-h: Pre- and post-treatment].

Case 12

A 17-year-old female student reported on 20 August 2021 with a yellow-coloured wart on the plantar surface of the right big toe of more than 1 cm with mild itching and pain, with the inability to walk since 4 months. She took the conventional treatment without any relief.

She had a history of infective right cervical lymphadenopathy and took conventional treatment with uneventful recovery.

She feared lizards and had an aversion to seeing people who disagreed with her. She was jealous of her siblings (as informed by the mother), desired ice creams and was excessively thirsty and sensitive to warmth.

On repertorisation, *Calcarea sulphurica* - 22/21, *Sulphur* - 8/6/ and *Calcarea carbonica* - 15/5 covered the maximum scores. *Calcarea Sulphurica* 30C was prescribed, to be taken once every 15 days for 1 month.

Follow-up, observations and prescription

2nd visit (6 November 2021) – The wart on the toe subsided; placebo was prescribed for 1 month [Figure 12a and b: Pre- and post-treatment].

Case 13

An 11-year-old boy reported to the OPD on 17 September 2021, with three black-coloured warts on his right leg since 1 year; the largest measured 1 cm, with mild itching. He was a known case of allergic bronchial asthma, for which he was under conventional treatment.

He feared insects and was very obstinate; thirstless, desired eggs and perspired more on the scalp on exertion, had intolerance to cold.

Calcarea. carbonica - 23/11, *Lycopodium clavatum* - 15/10 and *Pulsatilla* - 18/9 covered the maximum score on repertorial analysis. *Calcarea carbonica* 30C was prescribed, to be taken once every 2 weeks for 2 month.

Follow-up, observations and prescription

2nd visit (14 October 2021) – All warts subsided; placebo was prescribed for 1 month [Figure 13a and b: Pre- and post-treatment].

Case 14

A 22-year-old female, a post-graduation student reported on 05 November 2021 with a brown-coloured wart on her left nostril since 3 months, with mild itching. The wart measured nearly 1.5 cm. She took local conventional treatment without any relief and was advised cauterisation. Instead, she approached the institute to avoid the procedure. She had no relevant medical history, except that her father had bronchial asthma.

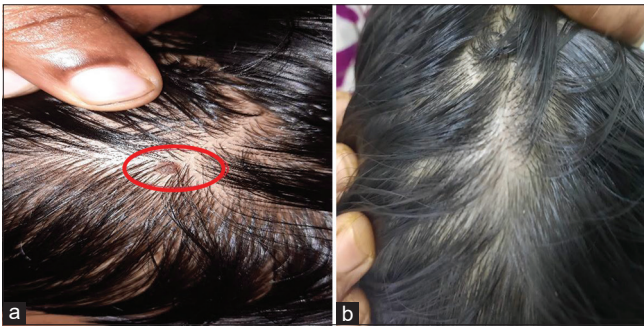

Figure 10: Case 10 - (a) Pre-treatment, (b) post-treatment

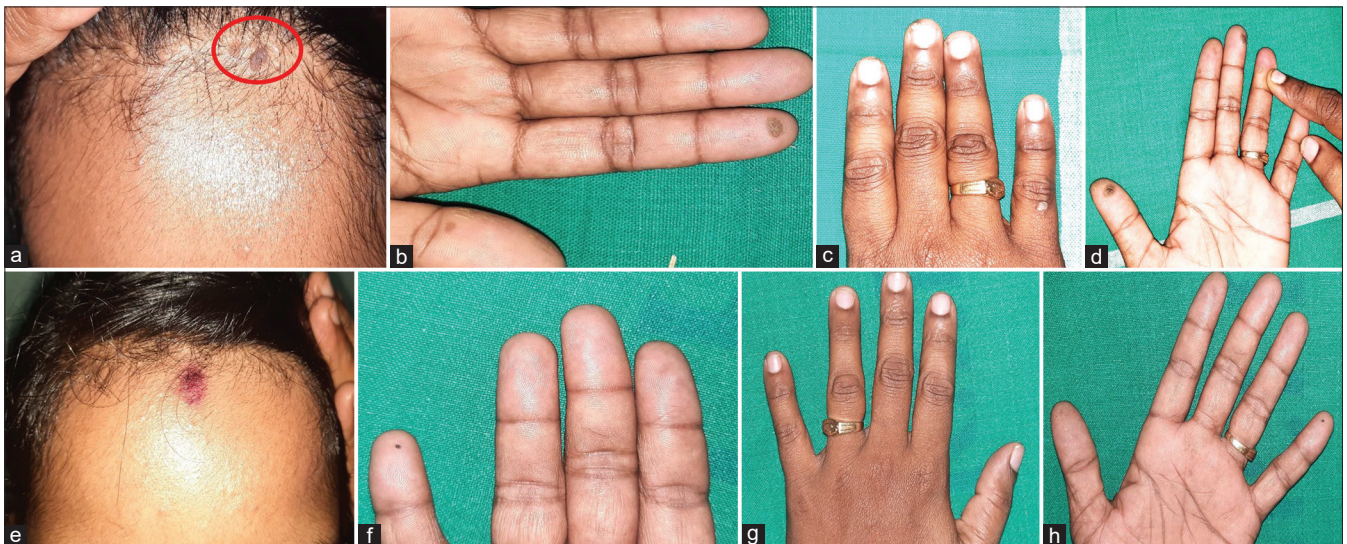


Figure 11: Case 11 - (a) Pre-treatment, (b) pre-treatment, (c) pre-treatment, (d) pre-treatment, (e) post-treatment, (f) post-treatment, (g) post-treatment, (h) post-treatment

She was very affectionate, feared snakes and desires eggs and was intolerant to cold weather.

Causticum - 11/6, *Pulsatilla* - 11/6 and *Sulphur* - 9/6 covered the maximum score on repertorial analysis. After eliminating the other remedies as they were hot in disposition, *Causticum* 30C, two doses, were prescribed once every 15 days.

Follow-up, observations and prescription

2nd visit (3 December 2021) – The mother reported that the wart appeared slightly smaller; same medicine was repeated for another month.

3rd visit (31 December 2021) – The wart completely disappeared and there were no other new complaints; placebo was prescribed for 1 month [Figure 14 and b: Pre- and post-treatment].

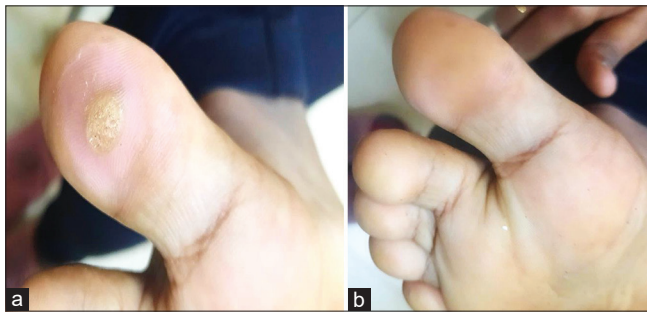

Figure 12: Case 12 - (a) Pre-treatment, (b) Post-treatment

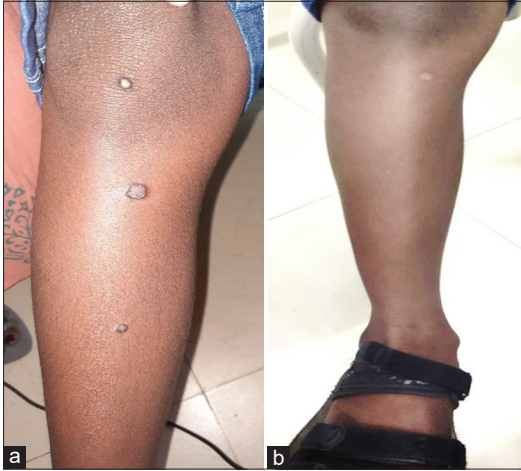

Figure 13: Case 13 - (a) Pre-treatment, (b) Post-treatment

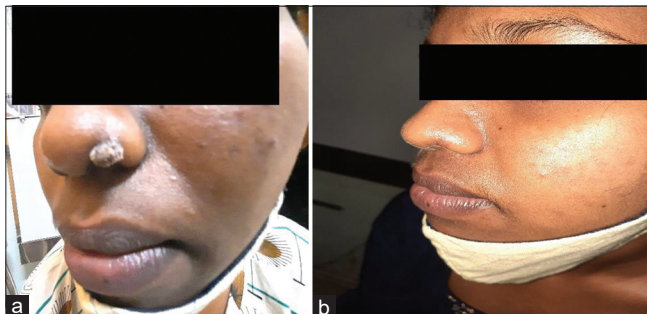


Figure 14: Case 14 - (a) Pre-treatment, (b) Post-treatment

Table 1: Socio-demographic characteristics

Variables	No of cases	Percentage
Age		
Up to 10 years	2	14.29
11–20 years	8	57.14
21–30 years	3	21.43
31–40 years	1	7.14
Sex		
Male	5	35.71
Female	9	64.29
Occupation		
Homemaker	1	7.14
Nurse	1	7.14
Postmaster	1	7.14
Student	11	78.57
Socioeconomic status		
Poor or low	2	14.3
Middle and upper	12	85.7
Duration of Illness		
Up to 6 months	5	35.71
7–12 months	7	50.00
13–18 months	0	0.00
19–24 months	1	7.14
25–30 months	1	7.14
Side		
Both	4	28.57
Left	4	28.57
Right	5	35.71
No. of warts		
1	3	21.43
2	1	7.14
3	2	14.29
5	1	7.14
6	3	21.43
7	2	14.29
9	2	14.29
Location		
Fingers	9	64.29
Head, fingers	1	7.14
Leg	1	7.14
Nose	1	7.14
Scalp	1	7.14
Toes	1	7.14
Size		
1 cm	12	85.71
1.5 cm	1	7.14
2 cm	1	7.14
Colour		
Black	7	50.00
Brown	5	35.71
Light	2	14.29
Surface		
Rough	12	85.71
Smooth	2	14.29
Duration of treatment		
<1 month	1	7.14
1 month	2	14.29
2 months	4	28.57
3 months	7	50.00

Table 2: Master chart of the 14 cases

Case No.	No. 1	No. 2	No. 3	No. 4	No. 5	No. 6	No. 7	No. 8	No. 9	No. 10	No. 11	No. 12	No. 13	No. 14
Features														
Age (years)	22	6	14	11	16	28	14	15	12	6½	31	17	11	22
Sex	Female	Female	Male	Male	Male	Female	Male	Female	Female	Female	Female	Female	Male	Female
Occupation	Nurse	Student	Student	Student	Student	Homemaker	Student	Student	Student	Student	Postmaster	Student	Student	Student
Duration of illness (months)	6	12	24	12	12	12	12	3	3	12	30	4	12	3
Side	Left	Left	Right	Both	Left	Both	Both	Right	Right	-	Both	Right	Right	Left
No of warts	9	5	6	2	6	5	7	3	7	1	9	1	3	1
Location	Fingers	Fingers	Fingers	Fingers	Fingers	Fingers	Fingers	Fingers	Fingers	Scalp	Head, fingers	Toes	Leg	Nose
Size*	1 cm	1 cm	1 cm	1 cm	1 cm	1 cm	1 cm	1 cm	1 cm	1 cm	1 cm	2 cm	1 cm	1.5 cm
Colour	Black	Black	Brown	Brown	Black	Black	Black	Light yellow	Black	Brown	Brown	Light yellow	Black	Brown
Surface	Rough	Rough	Rough	smooth	Rough	Rough	Rough	Rough	Rough	Smooth	Rough	Rough	Rough	Rough
Remedy	<i>Sepia</i>	<i>Sepia</i>	<i>Natrum muriaticum</i>	<i>Causticum</i>	<i>Silicea</i>	<i>Sepia</i>	<i>Causticum</i>	<i>Lachesis</i>	<i>Natrum muriaticum</i>	<i>Sepia</i>	<i>Sepia</i>	<i>Calcareo sulphurica</i>	<i>Calcareo carbonica</i>	<i>Causticum</i>
Potency and doses	30C - 2 doses - 15 days once	30C - 2 doses - 15 days once	30C - 2 doses - 15 days once	30C - 4 doses - 15 days once	30C 2 doses - 15 days once	30C - 2 doses - 15 days once	30C - 4 doses - 15 days once	30C - 4 doses - 15 days once	30C - 2 doses - 15 days once	30C - 2 doses - 15 days once	30C - 2 doses - 15 days once	30C - 2 doses - 15 days once	30C - 4 doses - 15 days once	30C - 4 doses - 15 days once
Duration of treatment to cure (months)	2	3	1	1	Below 1 month	3	1	2	1	1	2	1	1	2

*The most prominent wart is considered to be measured

Table 3: Symptoms and prescribed medicines

S. No.	Symptoms	Medicine (No. of cases where indicated)
1.	<ul style="list-style-type: none"> • Horrible or sad stories affect her profoundly • Offended easily • Fear of being alone • Fear of ghosts • Desires to dance • Always seeking company • Sensitive to noise • Desire spices ++, aversion to onions +++, Sweets +++, meat+++ • Intolerance of cold • Perspiration is more on palms • Sleep on the abdomen with a covering. • Mild dysmenorrhea • Leucorrhoea has worse menses before with itching and offensive. • Warts on the head, scalp, fingers, close to nails, painful, itching, hard, colour- black and brown 	<i>Sepia</i> (5)
2.	<ul style="list-style-type: none"> • Anxiety with fear of doing new work • Sensitive to criticism • Taciturn • Reserved • Always prefer male dressings • Thirsty • Desire fish +++, Chocolates +++, sweets++, • Aversion to meat ++ • Intolerance to sun exposure causes headaches • Heat intolerance • Warts on the right-hand thumb, index and middle fingers and close to the nails, colour-brownish, black and rough surface 	<i>Natrum muriaticum</i> (2)
3.	<ul style="list-style-type: none"> • Fear of dogs • Fear of snakes, • Affectionate ++ • Startled by noises • Stammering will increase when he gives presentations. • Desires spicy things, chicken +++, eggs +++) • Aversion to vegetables • Constipation- hard stool • Intolerance to cold • Warts on the right thumb, left-hand index finger, the margin of the nose, rough in surface, colour-brown, black. Warts close to nails, bleeding when trying to remove 	<i>Causticum</i> (3)
4.	<ul style="list-style-type: none"> • Mental exertion increased the perspiration on his palms, soles • Timidity • Desires sweets ++, fish+ • Perspiration is more on palms and soles • Sleep on the abdomen • Intolerance of cold • Warts on the tip of the fingers with pain 	<i>Silicea terra</i> (1)
5.	<ul style="list-style-type: none"> • Anxiety with palpitation • Communicative person • Difficulty concentrating on studies, • Dreams of snakes • Desire for pickles +++) • Thirsty person • Hot patient • Warts on fingers, the colour light yellow. • Convulsions without consciousness, turning the eyes during the episode 	<i>Lachesis</i> (1)

(Contd...)

Table 3: (Continued)

S. No.	Symptoms	Medicine (No. of cases where indicated)
6.	<ul style="list-style-type: none"> • Fear of lizards +++ • Aversion to seeing people who disagree with her +++ • Jealousy between siblings • Desire for ice creams +++ • Thirsty person • Hot patient • Warts on the right-side plantar surface of the toe, yellow 	<i>Calcarea sulphurica</i> (1)
7.	<ul style="list-style-type: none"> • Fear of insects • Obstinate • Thirstless • Desire eggs+++ • Perspiration is more on the scalp on exertion++ • Intolerance to cold • Warts on legs in the colour black 	<i>Calcarea carbonica</i> (1)

+ denotes the intensity of symptoms

RESULTS

The socio-demographic details, duration of illness and description of warts, including location, number, size, colour and consistency, followed by the duration of treatment to relieve the complaints, are summarised in Table.1.

The master chart of these 14 cases is summarised in Table 2. Of these fourteen cases, *Sepia* was prescribed in five cases, *Causticum* in three cases, *Natrum muriaticum* in two cases, *Calcarea carbonica*, *Calcarea Sulphurica*, *Lachesis* and *Silicea* in respective cases where indicated. The individualised treatment helped in complete disappearance of the warts, without any adverse events. The duration of disappearance of warts since treatment varied from <1–3 months. No recurrence of complaints was recorded during the follow-up period of 1–3 years.

DISCUSSION

Fourteen warts cases treated with individualised homoeopathic medicine are reported here without adverse events. No external applications were prescribed in these cases during the course of treatment. The findings highlight the need for personalised homoeopathic therapy for warts, thus replacing the psychological and cosmetic anguish that usually occurs with complicated processes like cryosurgery. In addition, because of its all-encompassing approach, homoeopathy comprehends the patient's psychosocial and physical generals, which aids the choice the similimum and, in turn, a holistic recovery.

Eleven of the 14 cases reported here are of school-going children, corroborating with the Ghadgepatil *et al.*^[2] results that warts are more prevalent in this age group. The study also suggests that warts mainly affected extremities, probably due to increased susceptibility of those regions during games or other physical activities. In their four-warts case series, Biswas *et al.* cured the warts within 40–45 days with *Hepar sulphuris calcareum*, *Arsenicum album* and *Natrum muriaticum*.^[9] Shaikh, in his five-wart case series, treated three cases with

Causticum and two by *Thuja occidentalis* in both centesimal and LM potencies and observed that LM potencies would give faster results when compared to the centesimal potencies.^[10] In another article, Gupta *et al.* mentioned that 90 % of warts are cleared with *Thuja occidentalis*, *Ruta*, *Antim. crudum*, *Calcarea carbonica*, *Nitric acid*, *Causticum*, *Natrum muriaticum* and *Opium*.^[11] Swami and Pradhan in their pilot study on warts in 100 patients, found that *Dulcamara* was very effective in *Verruca vulgaris* and *plana*, *Natrum muriaticum* in *Palmoplantar* and *Thuja occidentalis* in the *digitate* variety.^[12] Shradhamayananda reports a study of 200 cases of warts successfully treated with *Thuja occidentalis*, *Dulcamara* and *Natrum muriaticum* effectively.^[13] Dey *et al.*, in their double-blind, placebo-controlled pilot study with individualised homoeopathic medicines for cutaneous warts, report *Thuja occidentalis*, *Natrum muriaticum*, *Sulphur*, *Dulcamara*, *Nitric acidum*, *Antimonium crudum*, *Causticum*, *Mercurius solubilis* and *Calcarea carbonica* as the most indicated drugs.^[14]

In these 14 case series, the indicated remedies were *Sepia* (5 cases) among these four *verruca vulgaris* and one *verruca plana*, *Causticum* (3), two cases of *verruca vulgaris* and one of *verruca plana* and *Natrum Muriaticum* (2) of *verruca vulgaris*, *Calcarea carbonica* in *verruca vulgaris*, *Calcarea sulphurica* in *verruca plantaris*, *Lachesis* and *Silicea* in *verruca plana* were indicated in each case. Out of 14 cases, *Sepia* as an indicated remedy was successful in five female patients due to a strong affinity towards females, sycotic predominance with a tendency to produce warts on fingers.^[19] The causal relationship between the intervention and outcome was assessed through MONARCH criteria (Supplementary Table 1). Of these 14 cases, the score was +8 in 12 cases and +9 in two cases (Case no. 6 and 7), indicating the definite causal attribution of individualised homoeopathy in the subsided warts.

Naturally, warts are considered one-sided, external local disease with a paucity of symptoms. However, they must be seen as a local manifestation of generalised diseases.^[20,21]

Dr. Hahnemann explained § 185 about the treatment of local diseases that the administration of remedy must be homoeopathic not only to the character of those local affections but also to the totality of the symptoms that the patient presents. He condemned the practice of removing or exterminating the sycotic growths (warts) by external application or medicine excision.^[22] To a homoeopath, these local manifestations are the end result of the disease process and not the disease as such. Burnett stated, ‘*Cutting an apple does not cure an apple tree of growing apples*’ means removing the end results by local measures only leaves the same disease simmering in the system and will recur in the same or a different form.^[23]

Hahnemann and Boericke^[20] and Roberts^[24] had mentioned that warts/fig warts are of sycotic origin, but Banerjee further differentiated and described psoric warts as soft, skin-coloured, which can be compressible; the sycotic warts as hard, raised, jagged, in various colours, usually brownish, tubercular warts as plantar warts, which occur primarily under the skin, and syphilitic warts as the ones that are prone to bleeding.^[19] In our case series, we observed thirteen cases to have predominantly psoric and sycotic warts, except one as tubercular warts (Case no 12). Table 3 mentions the observed symptoms with indicated medicine of these 14 cases for further validation.

CONCLUSION

In these 14 cases, warts on different body parts were treated with individualised homoeopathy and results were obtained within a plausible time, without any adverse events or recurrence of the complaints. Moreover, *Sepia*, *Causticum* and *Natrum muriaticum* showed the maximum effectiveness in treating warts on fingers. This case series may pave the way for pragmatic, homoeopathic research on the condition in the future.

ACKNOWLEDGMENTS

The authors acknowledge K. C. Muraleedharan, Assistant Director (H)/Officer In-charge, National Homoeopathy Research Institute in Mental Health, Kottayam, for encouraging case report writing as scientific publications. Mrs. Resmy, the statistician, is also acknowledged for the statistical inputs.

Declaration of patients’ consent

The authors certify that they obtained the patients’ consent and minors’ assent forms. In the form, the patients agreed to share their clinical information and images reported in the journal. In addition, the patients understood that their names and initials will not be included in the manuscript, but complete anonymity cannot be guaranteed.

Financial support and sponsorship

Nil.

Conflicts of interest

None declared.

Supplementary Table

Supplementary Table 1: MONARCH scores.

REFERENCES

1. Al Aboud AM, Nigam PK. Wart. In: StatPearls. Treasure Island, FL: Stat Pearls Publishing; 2022. Available from: <https://www.ncbi.nlm.nih.gov/books/NBK431047> [2022 July 03].
2. Ghadgepatil SS, Gupta S, Sharma YK. Clinicoepidemiological study of different types of warts. *Dermatol Res Pract* 2016;2016:7989817.
3. Liu J, Li H, Yang F, Ren Y, Xia T, Zhao Z, *et al.* Epidemiology and clinical profile of cutaneous warts in Chinese college students: A cross-sectional and follow-up study. *Sci Rep* 2018;8:15450.
4. Rao KM, Ankad BS, Naidu SV, Vinod A. A clinical study on warts. *J Clin Diagn Res* 2011;5:1582-4.
5. Gerlero P, Hernández-Martín Á. Treatment of warts in children: An update. *Actas Dermosifiliogr* 2016;107:551-8.
6. Pope M, Kyriakides K, Hoffman C. Treatment of warts in pediatrics: A review. *J Fam Med Dis Prev* 2020;6:132.
7. Das E. Understanding the principles of homeopathy on a research perspective. *J Complement Med Alt Healthcare* 2019;9:555756.
8. Khurana A. Clinical case reports: A time-tested, traditional way to enhance evidence. *Indian J Res Homoeopathy* 2022;16:1-2.
9. Biswas B, Roy PS, Mandal S, Roy P. Four cases of warts treated by individualized homoeopathic medicine: A clinical case study. *J Intgr Stand Homoeopathy* 2022;5:9-18.
10. Shaikh MI. Case studies for treatment of warts with homoeopathy. *Indian J Res Homoeopathy* 2016;10:272-8.
11. Gupta R, Bhardwaj OP, Manchanda RK. Homoeopathy in the treatment of warts. *Br Homeopath J* 1991;80:108-11.
12. Swami S, Pradhan AK. Rapid recovery from skin warts by explicit homeopathic medicines. *Int J Clin Dermatol Res* 2015;3:71-5.
13. Shradhamayananda S. Healing of skin warts with ultradiluted homoeopathic medicines-a study in 200 cases. *Clin Res Dermatol Open Access* 2017;4:1-4.
14. Dey S, Hashmi S, Saha S, Mandal M, Shaikh AR, Agrawal E, *et al.* A randomized, double-blind, placebo-controlled, pilot trial of individualized homoeopathic medicines for cutaneous warts. *Homeopathy* 2021;110:149-59.
15. Homeobook. Methods and Techniques of Repertorisation. Available from: <https://www.homeobook.com/methods-and-techniques-of-repertorisation> [Last accessed on 2022 Dec 21].
16. Boericke W. Boericke’s New Manual of Homoeopathic Treatment with Repertory. 3rd revised and augmented edition based on 9th ed. New Delhi: B. Jain Publishers (P) Ltd.; 2010.
17. Lamba CD, Gupta VK, van Haselen R, Rutten L, Mahajan N, Molla AM, *et al.* Evaluation of the modified Naranjo criteria for assessing causal attribution of clinical outcome to homoeopathic intervention as presented in case reports. *Homeopathy* 2020;109:191-7.
18. Close S. Chapter VII-susceptibility, reaction, and immunity. In: *The Genius of Homoeopathy, Lecture, and Essays on Homoeopathic*. New Delhi: B. Jain Publishers Pvt Ltd.; 2001. p. 82, 183-212.
19. Banerjee SK. Miasmatic Diagnosis. 2nd ed. New Delhi: B. Jain Publishers; 2013. p. 175.
20. Hahnemann S, Boericke W. Organon of Medicine. 6th ed. New Delhi: B. Jain Publishers Pvt Ltd.; 1996. p. 166-7.
21. Central Council for Research in Homoeopathy. Efficacy of predefined homoeopathic medicines in the treatment of warts: Study protocol of double blind randomised placebo controlled trial. *Indian J Res Homoeopathy* 2019;13:41-7.
22. Sarkar BK. Hahnemann’s Organon of Medicine. 9th ed. Delhi: Birla Publications; 2004. p. 409-11.
23. Chand DH. Verrucae (warts). *Br Homeopathic J* 1986;75:18-26.
24. Roberts HA. XXVII disease classification; syccosis. In: *The Principles and Art of Cure by Homoeopathy*. 3rd ed., 7th Impression. New Delhi: B. Jain Publishers Pvt Ltd.; 2010. p. 240-1.

Effacité de l'intervention homéopathique individualisée contre les verrues – Une série de cas

Les verrues vulgaires, également connues sous le nom de verrues vulgaires, sont des lésions bénignes causées par le virus du papillome humain non malin, qui touchent environ 10 % de la population mondiale. Elle peut varier de 1 mm à plusieurs cm, surtout visible sur les extrémités, puis sur le visage. Ils peuvent être transmis par contact direct ou indirect et entraîner des problèmes esthétiques, des démangeaisons et des douleurs légères à intenses lors de la pratique d'activités. Le traitement conventionnel comporte des thérapies destructrices comme l'acide salicylique, la cautérisation, la cryochirurgie, etc., qui induisent de nombreux effets indésirables locaux ou généraux. Cependant, une approche homéopathique individualisée peut être utilisée pour traiter efficacement ces verrues, sans qu'il soit nécessaire d'appliquer des produits topiques ni de récidive des plaintes. L'amélioration a été évaluée à l'aide d'enregistrements photographiques. Cette série de cas donne un aperçu de l'intervention homéopathique individualisée dans différents types de verrues et ouvre la voie à des études pragmatiques à l'avenir.

Wirksamkeit einer individualisierten homöopathischen Intervention bei Warzen - eine Fallserie

Verruca vulgaris, auch bekannt als gewöhnliche Warzen, sind gutartige Läsionen, die durch das nicht bösartige humane Papillomavirus verursacht werden und weltweit etwa 10 % der Bevölkerung betreffen. Sie können zwischen 1 mm und mehreren cm groß sein und treten meist an den Extremitäten auf, gefolgt vom Gesicht. Sie können durch direkten oder indirekten Kontakt übertragen werden und führen zu kosmetischen Problemen, Juckreiz und leichten bis starken Schmerzen bei der Ausübung von Tätigkeiten. Die konventionelle Behandlung besteht aus destruktiven Therapien wie Salicylsäure, Kauterisation, Kryochirurgie usw., die viele unerwünschte Wirkungen von lokal bis allgemein haben. Mit einem individualisierten homöopathischen Ansatz können diese Warzen jedoch wirksam behandelt werden, ohne dass die Anwendung von topischen Mitteln erforderlich ist oder die Beschwerden wieder auftreten. Die Verbesserung wurde durch fotografische Aufzeichnungen bewertet. Diese Fallserie gibt einen Einblick in die individualisierte homöopathische Intervention bei verschiedenen Warzenarten und ebnet den Weg für pragmatische Studien in der Zukunft.

मस्सों में व्यक्तिगत होम्योपैथी हस्तक्षेप की प्रभावशीलता - एक केस श्रृंखला

वेरुका वल्गारिस, जिसे आम मस्से के रूप में भी जाना जाता है, नॉन मलिंगनेंट ह्युमन पैपिलोमावायरस के कारण होने वाले बिनाईन घाव हैं, जो वैश्विक स्तर पर लगभग 10% आबादी को प्रभावित करते हैं। यह 1 मिमी से लेकर कई सेमी तक हो सकता है, जो अधिकतर हाथ-पैरों पर या चेहरे पर देखा जाता है। यह संक्रमण प्रत्यक्ष या अप्रत्यक्ष संपर्क से फैल सकते हैं और इससे त्वचा की उपस्थिति की चिंता, खुजली और गतिविधियाँ करते हुए हल्के से गंभीर दर्द हो सकते हैं। पारंपरिक उपचार में कई विनाशकारी चिकित्साएँ जैसे सैलिसिलिक एसिड, कॉटिराइजेशन, क्रायोसर्जरी आदि का उपयोग किया जाता है, जो त्वचा पर स्थानीय दुष्प्रभावों से लेकर पूरे शरीर में दुष्प्रभाव पैदा कर सकते हैं। हालाँकि, इन मस्सों के प्रभावी उपचार के लिए एक व्यक्तिगत होम्योपैथी दृष्टिकोण का उपयोग किया जा सकता है, जिसमें किसी भी प्रकार की दवा लगाने की आवश्यकता नहीं होती है और ना ही शिकायतों दोबारा होती है। सुधार का आकलन मरीजों की तस्वीर के माध्यम से किया गया। यह केस श्रृंखला विभिन्न प्रकार के मस्सों में व्यक्तिगत होम्योपैथी हस्तक्षेप के बारे में जानकारी प्रदान करती है और भविष्य में व्यावहारिक अध्ययनों के लिए मार्ग प्रशस्त करती है।

Eficacia de la intervención homeopática individualizada en las verrugas - Serie de casos

La verruga vulgar, también conocida como verruga común, es una lesión benigna causada por el virus no maligno del papiloma humano, que afecta aproximadamente al 10% de la población mundial. Pueden oscilar entre 1 mm y varios cm, y se observan sobre todo en las extremidades, seguidas de la cara. Pueden transmitirse por contacto directo o indirecto y provocan problemas estéticos, picor y dolor de leve a intenso al realizar actividades. El tratamiento convencional cuenta con terapias destructivas como el ácido salicílico, la cauterización, la criocirugía, etc., que inducen numerosos efectos adversos, desde locales a generales. Sin embargo, se puede utilizar un enfoque homeopático individualizado para tratar eficazmente estas verrugas, sin necesidad de aplicar tópicos ni de que reaparezcan las dolencias. La mejoría se evaluó mediante registros fotográficos. Esta serie de casos proporciona una visión de la intervención homeopática individualizada en diferentes tipos de verrugas y allana el camino para estudios pragmáticos en el futuro.

个体化 势 法干 治 疣 的 效- 一系列病例.

常疣, 也称 普通疣, 是由非 性人类乳头瘤病毒引起的良性病, 影响全球 10%的人口。它的范 从1毫米到 几厘米, 主要出 在四肢, 其次是面部。它 可能通过直接或 接接触 播, 并 致美容 、 痒痒和活动时的 度至重度疼痛。常 治 有水 酸、 灼、 冷 等破坏性 法, 从局部到全身都会 生 多不良反 。然而, 个体 化的 势 法方法可以用来有效治 这些疣, 而不需要局部用 或复 。通过照片 录对改善情况 行了 估。这 个案例系列 不同类型疣的个性化 势 法干 提供了解, 并 未来的实用研究 平了道路。