

Polycystic ovarian syndrome with obsessive-compulsive disorder treated with homoeopathy: A case report

Geeta Arora¹, Arti Goyal^{2*}

¹Homoeopathic Consultant, New Delhi, India, ²Central Council for Research in Homoeopathy, New Delhi, India

Abstract

Introduction: Polycystic ovarian syndrome (PCOS) is a multisystem endocrine disorder which is gradually on a rise due to lifestyle changes and increased stress. **Case Summary:** A case of 29-year-old female suffering from PCOS showed improvement with homoeopathic treatment. The improvement was evident from the hormonal assays and ultrasonography reports of the patient. This case report suggests that individualised homoeopathic medicines are effective in the treatment of PCOS.

Keywords: Case report, Homoeopathy, Polycystic ovarian syndrome, Polycystic ovaries

INTRODUCTION

In polycystic ovarian syndrome (PCOS), the clinical symptom complex is characterized by the presence of multiple cysts on the ovaries, oligomenorrhea or amenorrhea, anovulation and associated with excessive amounts of body hair (hirsutism), excessive body weight, infertility and insulin resistance.^[1,2]

PCOS, earlier known as Stein-Leventhal syndrome, has a genetic and familial tendency or may have an autosomal dominant inheritance.^[3] The prevalence of PCOS in adolescents based on the Rotterdam criteria is 11.04% in the world.^[4] The prevalence of PCOS in Indian adolescents is 9.13%.^[5] Females in age group 18–44 years are affected by PCOS.^[6]

During investigations, ultrasound findings are confirmative of PCOS, which shows multiple cysts (12 or more) of 2–9 mm size located peripherally along the surface of the ovary sometimes seen as a ‘necklace’ appearance, theca cell hyperplasia and stromal hyperplasia (increasing the size of the ovary >10 cm³ in volume). Endocrinal findings in PCOS are normal or raised oestradiol level (E₂), raised (over 10 IU/mL) or normal luteinising hormone (LH) level and normal follicle stimulating hormone (FSH) level, but FSH/LH ratio falls. Furthermore, high Testosterone and epi-androstenedione levels in some cases, fasting blood glucose/fasting insulin ratio <4.5 suggests insulin resistance, triglyceride level >150 mg/dL suggest hyperlipidaemia and high-density lipoprotein <50 mg/dL.^[2,3]

There is currently no cure for PCOS.^[6] Even 10% weight loss is beneficial in the treatment of PCOS.^[7,8]

Even after menopause, women with PCOS continue to have high levels of androgens as well as insulin resistance. This means that the health risks associated with PCOS are lifelong.^[9]

There are many published studies and case reports which show that homoeopathic medicines are effective in treating the symptoms of PCOS.^[10-19] This is a case of PCOS along with pre-existing obsessive-compulsive disorder (OCD), which was treated with the help of individualised homoeopathic medicine.

CASE REPORT

Patient information

A 29-year-old female presented in the outpatient clinic with the following complaints:

- Amenorrhoea since 3 months
- Infrequent menses (menses appear after 3 or 5 months) since 1.5 years
- Increased growth of facial hair since 5–6 months
- Acne which usually appear or get aggravated,

***Address for correspondence:** Dr. Arti Goyal, I-1673, IIIrd Floor, Chittaranjan park, New Delhi - 110 019, India.
E-mail: goyalarti28@gmail.com

Received: 28 April 2021; **Accepted:** 10 June 2022

This is an open access journal, and articles are distributed under the terms of the Creative Commons Attribution-NonCommercial-ShareAlike 4.0 License, which allows others to remix, tweak, and build upon the work non-commercially, as long as appropriate credit is given and the new creations are licensed under the identical terms.

How to cite this article: Arora G, Goyal A. Polycystic ovarian syndrome with obsessive-compulsive disorder treated with homoeopathy: A case report. Indian J Res Homoeopathy 2022;16(2):163-170.

Access this article online

Quick Response Code:

Available in print version only

Website:
www.ijrh.org

DOI:
10.53945/2320-7094.1068

approximately 10 days to a week before the appearance of menses.

She also had a tendency for recurrent tonsillitis and rhinorrhoea which got triggered after taking cold drinks and was usually accompanied by a high fever. She was taking antibiotics at each such episode of the upper respiratory tract infection.

Laboratory investigations were done on day 2 or day 3 of the menstrual cycle (the patient came in February 2018 and menstrual cycle appeared after 2 months of treatment, so ultrasonography (USG) was done in April 2018), and the findings were: USG pelvis (trans abdominal sonography) report dated 7 April, 2018 (day 2 of the menstrual cycle) showed both ovaries to be slightly large. Size of the right ovary is $2.3 \times 2.6 \times 2.2$ cm, $V = 8.4$ cc. "Size of the left ovary is $2.6 \times 2.2 \times 2.9$ cm, $V = 9$ cc. 6–8 follicles are seen bilaterally measuring 3–6 mm. Follicles are seen peripherally within stroma. The central stroma echogenicity is increased. Ovaries have a polycystic appearance" [Figure 1].

Blood tests revealed FSH – 8.53 mIU/ml (in range) and LH – 28.07 mIU/ml (high) dated 8 April, 2018 which was done on day 3 of the menstrual cycle.

There was a history of recurrent allergic rhinitis and tonsillitis since childhood.

Recurrent upper respiratory tract infections (URTI) has been a major concern in history. There was no history of any other major illness.

Even though the case did not qualify for PCOS as per Rotterdam criteria,^[20] it met all the points mentioned in the criteria, except

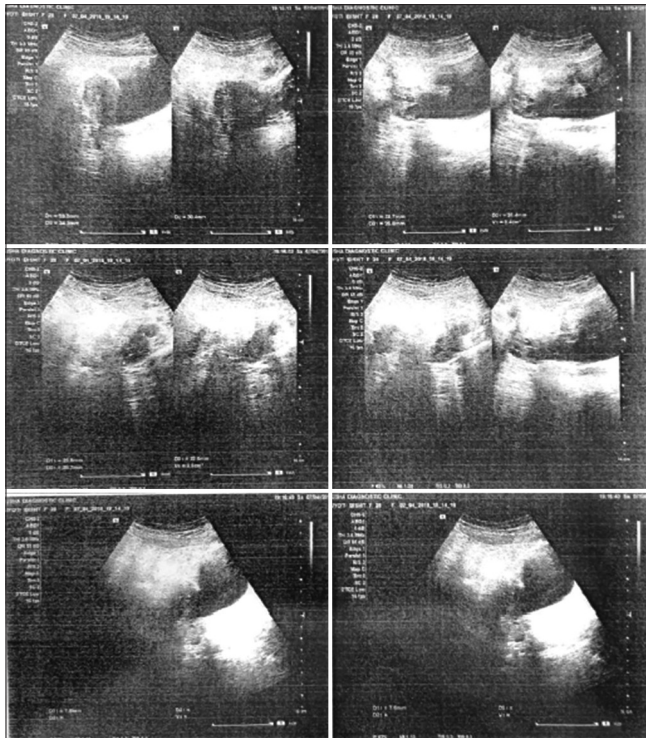


Figure 1: Ultrasonography pelvis (Trans Abdominal Sonography) report dated 7 April, 2018

for the number of cysts which are supposed to be 12 and were nine instead in this case. However, taking references from similar papers published in the past, the case was treated as PCOS.^[21-24]

Family history

Mother had a history of irregular menses in her teenage. The elder sister had depression. Her younger sister also had irregular menses.

Personal history

The patient was an Engineer by profession and had been working in an MNC for 2.5 years. She belonged to a middle-socioeconomic group.

Generals

The patient's appetite was good. She took 3 meals/day in adequate amounts. She had a desire for sweets, vegetables, chicken, eggs, milk and milk products. Her thirst was moderate. Her perspiration was offensive and staining, excessive and profuse in the axilla. She could not tolerate the smell of fish and had a white coating in centre of her tongue. The thermal reaction was chilly. Her sleep was sound and refreshing with frequent dreams of snakes. Bowel movements were regular with well-formed stool but had to strain sometimes.

Since her school days, the patient had a habit to cross-check her work again and again, which persisted later in life too. For example, if her mother would give her some work, she would cross-check the work many times, she washed her hands frequently and she checked her work repeatedly in the office too. As a child, she used to work very hard to score good marks due to pressure at home for good performance in studies. Hence, she was always anxious about studies. She worried a lot for her family members and feared losing them. She feared death of family members. She was very sensitive of opinion of others. She had anxiety about her health and about her menses being delayed.

Examination

Abdominal Examination: Flat shaped abdomen with no visible swelling or scar. Soft on palpation with no tenderness and no organomegaly.

ENT Examination: Throat and nose were clear. Normal tympanic membrane with some ear wax.

Skin Examination: Acne on cheeks and bridge of nose. Redness with no bleeding. Facial hair on chin and jaw line.

Respiratory Examination: Thoracoabdominal breathing with no added sounds on auscultation.

Mental state Examination: The patient was fully awake sitting in an erect posture. The patient was anxious with rapid speech. She had good cognitive abilities, sharp memory and clear language and was attentive.

Case analysis

After analysing the symptoms of the case, the characteristic mental, physical generals and particular symptoms were considered to constitute the totality. Anxiety about her family's health, sensitiveness to the opinion of others and persistent thoughts

that people are watching her, fear of death, lack of confidence, irresolute, dreams of snakes, desire for sweets, aversion to the smell of fish, acne on the face, history of recurrent URTI, irregular and delayed menses which were symptoms included in the totality.

Seeing the obsessive-compulsive traits evident in the case, the patient was sent for evaluation by a clinical psychologist. On evaluation with Y Bocs scale, her score came out to be 14 for obsessive traits and 16 for compulsive traits, that is, a total score of 30 [Table 1].

Considering the above symptomatology, synthesis repertory was preferred and using RADAR software, systematic repertorisation was done [Figure 2].^[25]

First prescription

Considering the totality, *Silicea terra* 30/TDS/15 days was prescribed.

Follow-up

The follow-ups were done fortnightly. The patient complied well to the homoeopathic intervention. Menses appeared on 6 April, 2018 after the first prescription of *Sil.* 30, but were very scanty. *Silicea* was continued for two subsequent follow-ups at 15 days intervals (17 April, 2018 and 5 May, 2018). However, no other symptoms except straining at stools and anxiety were posted to be better. On 17 May, 2018, the case was re-reviewed and *Calcarea Carbonica* 200 was prescribed. Menses appeared after this with normal flow. On 14 July, 2018, potency was increased from 200 to 1M, as improvement in the regularity of menses was there, but obsessive thoughts were still persistent and considering the high sensitivity of the patient, potency was raised. After *Cal. carb.* 1M, much improvement was seen in the obsessive thoughts of the patient. The patient was kept on *Cal. carb.* 1M for 6 months with infrequent dosage. USG was repeated after a few months of treatment, which showed complete resolution of cysts [Figure 3].

The patient's tendency to recurrent throat infections reduced markedly and her anxiety, obsessive thoughts of washing hands and re-checking her work also reduced remarkably. She was again evaluated for OCD on the Y BOCS scale by a psychologist again, and the score for OCD showed the obsessive traits as 3 and compulsive traits as 2, thus reducing to a total of 5 from 30 [Table 1].

Details of follow-up with indications for prescription are given in Table 2.

DISCUSSION

The patient improved gradually after *Cal. carb.* 200 and then 1M potency. 1M was prescribed when all physical symptoms were better but anxieties and compulsive behaviour remained. As soon as the potency was raised to 1M, the anxieties started coming down, along with compulsive thoughts and the overall condition gradually improved in 6 months.

The cysts in the ovary resolved completely with treatment. USG pelvis done on 5 February, 2019 revealed normal

Table 1: Y-Bocs score before and after treatment

S. No.	Y-Bocs Checklist	Before treatment	After treatment
1	Time occupied by obsessive thoughts: How much of your time was occupied by obsessive thoughts? How frequently did these thoughts occur?	3	1
2	Interference due to obsessive thoughts: How much did these thoughts interfere with your social or work functioning? Is there anything that you did not do due to them?	2	0
3	Distress associated with obsessive thoughts: How much distress did your obsessive thoughts cause you?	2	0
4	Resistance against obsessions: How much effort did you make to resist the obsessive thoughts? How often did you try to disregard or turn your attention away from those thoughts as they entered your mind?	3	1
5	Degrees of control over obsessive thoughts: How much control did you have over your obsessive thoughts? How successful were you in stopping or diverting your obsessive thinking?	4	1
Obsession subtotal (add items 1-5)		14	3
6	Time spent performing compulsive behaviours: How much time did you spend performing compulsive behaviours? How frequently did you perform compulsions?	3	1
7	Interference due to compulsive behaviours: How much did your compulsive behaviours interfere with your social or work functioning?	2	0
8	Distress associated with compulsive behaviours: How would you have felt if prevented from performing your compulsions? How anxious would you have become?	4	0
9	Resistance: How much effort did you make to resist the compulsions? Or how often did you try to stop the compulsions?	3	0
10	Degrees of control over compulsive behaviours: How much control did you have over the compulsive behaviours? How successful were you in stopping the ritual (s)?	4	1
Compulsive subtotal (add items 6-10)		16	2
Total score		30	5

study with complete resolution of cysts. USG reported: 'Both ovaries appear normal in size and echotexture'. LH and FSH were repeated on 6 February, 2019 which were back to normal range. Furthermore, as patient had a busy schedule at office, so no lifestyle modifications like exercise or diet were adopted in this case, which also indicates the sole action of homoeopathic intervention in bringing results.

Table 2: Follow-up table

Date	Indications for prescription	Remedy	Reasoning
20/2/2018	As per repertorial totality, sensitive to the opinion of others, chilly	<i>Sil.</i> 30/TDS/15 days	Totality based prescription
17/3/2018	Same condition, no change	<i>Sil.</i> 30/TDS/15 days	Improvement very less, repeat same medicine
17/4/2018	Slight spotting on 3 April, 2018, anxiety marginally better. Menses appeared on 6/4/2018 but were scanty	<i>Sil.</i> 30/TDS/15 days	Improvement very less, only spotting appeared. Repeat same medicine
5/5/2018	LMP-28/4/2018, scanty menses, mood swings before menses, acne on T- zone of the face, small itchy eruptions on chest and shoulders. Anxiety increased, fearful dreams that someone is going to harm her, she must save herself	<i>Sil.</i> 200/OD/15 days	The medicine showed some registration, but the anxiety was marked, acne before menses, increase potency as 30 potency had shown a marginal effect
17/5/2018	Acne present. She had spotting on 7 th and 8 th May 2018. Menses are scanty, spotting since last 2 cycles. Feeling very anxious with persistent thoughts. The case was re-reviewed as menses were still scanty Important symptoms came up- 1) 'I am anxious as I am always thinking what if someone notices that I am washing my hands again and again' 2) 'What if someone notices I have done the work wrong, so I keep checking my work again and again' 3) Craving for eggs (3 marks) These three rubrics were taken as qualifying rubrics in re-review of case	<i>Cal. carb.</i> 200/TDS/15 days	Skin not better, menses still scanty. Medicine not showing betterment despite repetition and potency increase. So, the case was reviewed again with the patient and a revised totality was formed. Potency started at 200 and repetition was also frequent a lot of mental symptoms were there
31/5/2018	LMP- 31 May, 2018, the flow was better. Acne present	<i>Cal. carb.</i> 200/TDS/15 days	Acne still present so repetition maintained
19/06/2018	Acne: Present, anxiety: 40% better	<i>Cal. carb.</i> 200/TDS/15 days	Acne still present so repetition maintained
14/7/2018	LMP-26/6/2018, the flow was normal. Negative thoughts are still present. She was unable to divert herself	<i>Cal. carb.</i> 1M/HS/15 days	The patient was given medicine for 15 days but comes after almost a month and giving a gap of 10 days. She is showing improvement in PCOS symptoms, but OCD symptoms are heightened
19/7/2018	Burning during urination, increased frequency, and pain in the right side of the abdomen	<i>Cantharis vesicatoria</i> 200, 3 hourly for 3 days	Acute urine infection.
11/8/2018	LMP-6 August, 2018, the flow was good, no acne. No episode of cold and cough. Burning during urination & increased frequency was better now. Still persistent thoughts and sometimes must wash hands 3-4 times but able to divert from negative thoughts	<i>Cal. carb.</i> 1M/HS/1 month	The menstrual flow was better, but persistent thoughts of OCD were prevalent so repeat the same medicine for continued action
18/9/2018	LMP-2 September, 2018, flow –normal, acne-none, anxieties –better, sleep disturbed	<i>Cal. carb.</i> 1M/HS/15 days	The menstrual flow was better, acne better, anxiety was better, sleep not sound, Sleep is a general state of being so to attain that repetition continued
4/10/2018	LMP-30 September, 2018, flow-normal, one acne on chin appeared before menses, emotionally stable, sleep disturbed	<i>Cal. carb.</i> 1M/HS/3 weeks	The menstrual flow was better, anxiety better, sleep not sound, Sleep is a general state of being so to attain that repetition continued
15/11/2018	LMP-30 October, 2018, small acne on chest, nose and chin, No cough and cold. Anxiety better. Emotionally stable	<i>Cal. carb.</i> 1M/HS/15 days	Acne recurred as medicine was discontinued. Medicine finished on 30.10.18 but the patient came on 15 November, 18, and acne appeared, so, repetition is done
27/11/2018	Hair fall, feeling that menses will appear	<i>Cal. carb.</i> 1M/HS/15 days	Hair fall – physical worsening
13/12/2018	LMP-3 December, 2018, Two acne appeared on the chin before menses	<i>Cal. carb.</i> 1M/HS/1 month	To get the sustained benefit
17/1/2019	LMP-1 January, 2019, scanty. Hair fall was not better, acne was better but reappeared and are painful	<i>Cal. carb.</i> 1M/BD/3 weeks	Physical symptoms worsening, and more medicine stimulus is needed
9/2/2019	LMP-5 February, 2019, acne better, recurrent cold not there now, obsessive thoughts- occasional episodes. USG-PCOS resolved, LH and FSH in the normal range. Facial hair growth also started decreasing now and thinning out	<i>Cal. carb.</i> 1M/BD/1 month	Sustained dose for maintaining results, hair on the face still to completely go

(Contd...)

Table 2: (Continued)

Date	Indications for prescription	Remedy	Reasoning
14/3/2019	LMP-5 February, 2019, acne present, irritability was present, one episode of URTI	<i>Cal. carb.</i> 1M/BD/3 weeks <i>Rhus. Tox.</i> 30 helped in acute complaints	Acne still there, irritability coming at the mental level, continue repetition.
06/4/2019	LMP- 21 March, 2019. Acne none, anxiety-none. Facial hair - soft hair on face now (hard hair on face gone)	<i>Cal. carb.</i> 1M/BD/1 month	All symptoms better, repeat dose before closing the case.
20/06/19	LMP-20 April, 19, acne none, anxiety none Y BOCS evaluation shows a score 3 for obsession and 2 for compulsions [Table 1]	Placebo twice a day for 1 month	OCD score showing improvement to a great extent. The patient shows betterment at the mental as well as physical levels

USG: Ultrasonography, PCOS: Polycystic ovarian syndrome, OCD: Obsessive-compulsive disorder, URTI: Upper respiratory tract infections

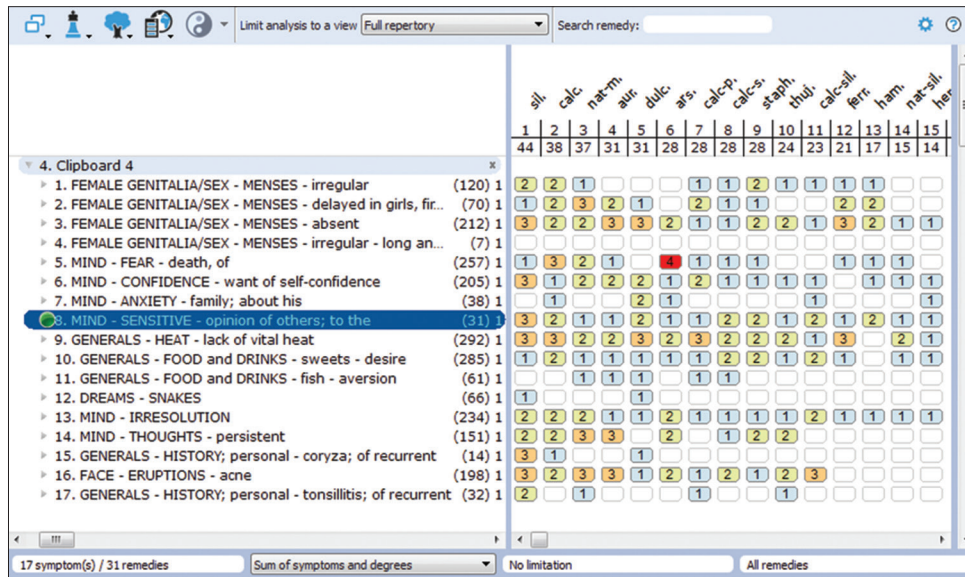


Figure 2: Repertorisation table

A constitutional homoeopathic medicine was prescribed in this case for PCOS. All mental, and physical generals and particulars were included for repertorisation. Remedies such as *Sil.*, *Cal. carb.*, *Natrium muriaticum.* and *Aurum metallicum* were competing with each other. At first, *Sil.* 30 was prescribed. It was given for two subsequent follow-ups as *Sil.* 30 and *Sil.* 200, respectively. There was not much improvement of symptoms, only spotting in the first menstrual cycle after medicine and another cycle was very scanty. The cycle did not regularize even after 2 months of medications. Furthermore, acne appeared on the shoulder and chest. This indicated that medicine was partially similar and not the similimum. The case was re-reviewed and symptoms of persistent thoughts and feelings, mentioned in repertory as ‘Delusion people will observe her confusion’ was taken as a qualifying rubric along with ‘craving for egg’, as these two symptoms came up to be very crucial in her case. Based on this, the totality was reconsidered and *Cal. carb.* 200/TDS was prescribed. The potency was kept 200 at the start itself, considering the high sensitivity of the patient. Her menses became regular, and the flow improved after *Cal. carb.* Acne lessened gradually and the tendency for recurrent URTIs also improved. After two follow-

ups, the potency of *Cal. carb.* was changed from 200 to 1M, as persistent compulsive thoughts were still appearing. After this, in addition to an improvement in physical symptoms, anxiety lessened and her compulsive thoughts also improved. She had regular menses. The patient was kept on *Cal. carb.* 1M. The reason for continuing *Calcarea carb.* was anxiety, compulsiveness persisting to some degree and acne still occurring. Her compulsive ness thoughts and obsessions were persistent for a long time and, therefore, it called for frequent repetition of medicine.

There was an improvement in PCOS (clinically as well as on investigation findings in USG), as well as, in her tendency to catch URTI, facial hair growth and her obsessive-compulsive behaviour, i.e., repeated hand washing and checking her work repeatedly. Her fear for her family members and her sister’s life also alleviated and she was much calmer. This shows homoeopathic approach with proper selection of medicine, potency and repetition of dosage, which can have promising results in cases of PCOS and other conditions such as OCD and recurrent URTI, leading to overall, holistic improvement.

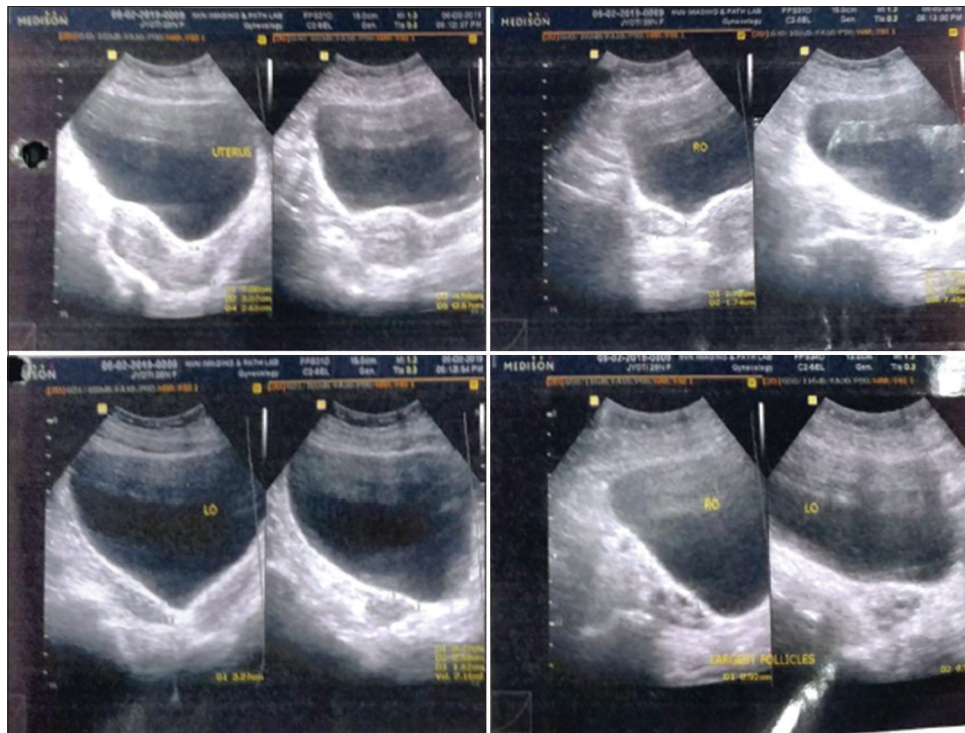


Figure 3: Ultrasonography pelvis (Trans Abdominal Sonography) report dated February 2019

CONCLUSION

The PCOS patient with OCD was overall better with treatment. More studies on treating this comorbidity with homoeopathy are warranted.

ACKNOWLEDGEMENT

The authors acknowledge Ms. Aparna Nayar, Clinical Psychologist, for valuable psychological assessment of the patient throughout the treatment of patient.

Declaration of patient consent

The patient has given consent for her reports and other clinical information to be published in the journal. The patient understands that her name and identity will be kept confidential.

Financial support and sponsorship

Nil.

Conflicts of interest

None declared.

REFERENCES

1. World Health Organization. ICD-10-CM: International Statistical Classification of Diseases and Related Health Problems-clinical Modification, 10th Revision. Geneva: World Health Organization; 2021. Available from: <https://www.Icd10data.Com/ICD10CM/Codes/E00-E89/E20-E35/E28-/E28.2> [Last accessed on 2022 May 22].
2. Curr BR, Bradshaw KD. Disorders of the ovary and female reproductive tract. In: Fauci AS, Braunwald E, Isselbacher KJ, Wilson JD, Martin JB, Kasper DL, *et al.*, editors. Harrison's Principles of Internal Medicine. 14th ed., Vol. 2. United States of America: McGraw Hill Companies Inc.; 1998. p. 2106-7.
3. Padubidri VG, Daftry SN, editors. Howkins and Bourne Shaw's Textbook of Gynecology. 14th ed. India: Elsevier; 2008. p. 331-3.
4. Naz MS, Tehrani FR, Majd HA, Ahmadi F, Ozgoli G, Fakari FR, *et al.* The prevalence of polycystic ovary syndrome in adolescents: A systematic review and meta-analysis. *Int J Reprod Biomed* 2019;17:533-42.
5. Nidhi R, Padmalatha V, Nagarathna R, Amritanshu R. Prevalence of polycystic ovarian syndrome in Indian adolescents. *J Pediatr Adolesc Gynecol* 2011;24:223-7.
6. U.S. Department of Health and Human Services, Office on Women's Health. Polycystic Ovary Syndrome (PCOS) Fact Sheet; 2014. Available from: <http://www.womenshealth.gov/publications/our-publications/fact-sheet/polycystic-ovary-syndrome.html> [Last accessed on 2022 May 15].
7. U.S. Department of Health and Human Services. Polycystic Ovary Syndrome. Available from: <https://www.nichd.nih.gov/health/topics/factsheets/pcos> [Last accessed on 2022 May 10].
8. Ndefo UA, Eaton A, Green MR. Polycystic ovary syndrome: A review of treatment options with a focus on pharmacological approaches. *P T* 2013;38:336-55.
9. Puurunen J, Piltonen T, Morin Papunen L, Perheentupa A, Jarvela I, Ruokonen A, *et al.* Unfavorable hormonal, metabolic, and inflammatory alterations persist after menopause in women with PCOS. *J Clin Endocrinol Metab* 2011;96:1827-34.
10. Rath P. Management of PCOS through homoeopathy-a case report. *Indian J Res Homoeopathy* 2018;12:95-100.
11. Malvekar PA, Nadgouda SS, Jadhav AB. A clinical study to see the effect of homoeopathic medicines in polycystic ovarian syndrome of reproductive age group between 12-45 years. *Int J Health Sci Res* 2020;10:43-7.
12. Thomas R. Theft of womanhood: Polycystic ovarian syndrome: Role of homoeopathy. *Homoeopathic Heritage* 2014;41:41-5.
13. Lamba CD, Oberai P, Manchanda RK, Rath P, Bindu PH, Padmanabham M. Evaluation of homoeopathic treatment in polycystic ovary syndrome: A single-blind, randomized, placebo-controlled pilot study. *Indian J Res Homoeopathy* 2018;12:35-45.
14. SanchezResendiz J, Guzman Gomez F. Polycystic ovary syndrome. *Boletin Mex Homeopatica* 1997;30:11-5.

15. Sharma D. Effects of homoeopathic medicines in polycystic ovarian syndrome (PCOS). In: 2nd International Conference and Exhibition Traditional and Alternative Medicine. Beijing, China: Events; 2014.
16. Sharma D. Effects of Homoeopathy in Polycystic Ovarian Syndrome (PCOS). In: Souvenir: International Convention on World Homoeopathy Day. India: Government of India AYUSH; 2016. p. 30.
17. Gupta G. Ultrasonographic follow up study on PCOD cases in response to Homoeopathic drugs. *Homoeopathic Heritage* 2009;2009:11-7.
18. Gupta G, Gupta N, Singh R. Ultrasonographic case series study in cases of polycystic ovarian syndrome in response to homoeopathic drugs. *Homoeopathic Heritage* 2015;40:39-50.
19. Gupta G. Role of homoeopathic medicines in cases of polycystic ovarian disease assessed by modern diagnostic parameters. *Adv Homoeopathic Res* 2017;2:15-25.
20. Chen Y, Li L, Chen X, Zhang Q, Wang W, Li Y, *et al.* Ovarian volume and follicle number in the diagnosis of polycystic ovary syndrome in Chinese women. *Ultrasound Obstet Gynecol* 2008;32:700-3.
21. Franks S. Controversy in clinical endocrinology: Diagnosis of polycystic ovarian syndrome: In defense of the Rotterdam criteria. *J Clin Endocrinol Metab* 2006;91:786-9.
22. Lujan ME, Jarrett BY, Brooks ED, Reines JK, Peppin AK, Muhn N, *et al.* Updated ultrasound criteria for polycystic ovary syndrome: Reliable thresholds for elevated follicle population and ovarian volume. *Hum Reprod* 2013;28:1361-8.
23. Duijkers IJ, Klipping C. Polycystic ovaries, as defined by the 2003 Rotterdam consensus criteria, are found to be very common in young healthy women. *Gynecol Endocrinol* 2010;26:152.
24. Alsamarai S, Adams JM, Murphy MK, Post MD, Hayden DL, Hall JE, *et al.* Criteria for polycystic ovarian morphology in polycystic ovary syndrome as a function of age. *J Clin Endocrinol Metab* 2009;12:4961-70.
25. Schroyens F. *Synthesis-Repertorium Homeopathicum Syntheticum, Radar Opus Pro.* New Delhi: B. Jain Exclusive; 2016.

Titre: Syndrome des ovaires polykystiques avec TOC traité par homéopathie : Un rapport de cas

Résumé: Introduction: Le syndrome des ovaires polykystiques est un trouble endocrinien multisystème qui augmente progressivement en raison des changements de mode de vie et du stress accru. **Case Summary:** Un cas de femme de 29 ans souffrant de SOPK a montré une amélioration avec un traitement homéopathique. L'amélioration était évidente d'après les dosages hormonaux et les rapports d'échographie (USG) de la patiente. Ce rapport de cas suggère que les médicaments homéopathiques individualisés sont efficaces dans le traitement du SOPK.

Titel: Polyzystisches Ovarialsyndrom mit OCD behandelt mit Homöopathie: Ein Fallbericht

Abstract: Introduction: Das polyzystische Ovarialsyndrom ist eine multisystemische endokrine Störung, die aufgrund von Lebensstiländerungen und erhöhtem Stress allmählich zunimmt. **Zusammenfassung des Falls:** Bei einer 29-jährigen Frau, die an PCOS litt, trat unter homöopathischer Behandlung eine Besserung ein. Die Verbesserung war aus den Hormonuntersuchungen und den Ultraschallberichten (USG) der Patientin ersichtlich. Dieser Fallbericht legt nahe, dass individualisierte homöopathische Arzneimittel bei der Behandlung von PCOS wirksam sind.

शीर्षक: होम्योपैथी के साथ इलाज किए गए ओसीडी के साथ पुटीमेय डिम्बग्रंथि लक्षण: विषय अध्ययन

सार: परिचय: पुटीमेय डिम्बग्रंथि लक्षण एक बहुतंत्रीय अंतःस्रावी विकार है जो धीरे-धीरे जीवनशैली में बदलाव और तनाव में वृद्धि के कारण बढ़ रहा है। **विषय सारांश:** पीसीओएस से पीड़ित -29 वर्षीय महिला के विषय में होम्योपैथिक उपचार के साथ सुधार दिखाया गया है। सुधार रोगी के हार्मोनल परख और अल्ट्रासोनोग्राफी (यूएसजी) रिपोर्ट से स्पष्ट था। इस मामले की रिपोर्ट से पता चलता है कि व्यक्तिगत होम्योपैथिक दवाएं पीसीओएस के उपचार में प्रभावी हैं।

Título: Síndrome de ovario poliquístico con TOC tratado con Homeopatía: Informe de caso Resumen: Introducción: El síndrome ovárico poliquístico es un trastorno endocrino multisistémico que está aumentando gradualmente debido a cambios en el estilo de vida y aumento del estrés. **Case Summary:** Un caso de una mujer de 29 años que padecía de SOP mostró mejoría con el tratamiento homeopático. La mejoría fue evidente en los ensayos hormonales y en los informes de ecografía (USG) del paciente. Este informe de caso sugiere que los medicamentos homeopáticos individualizados son efectivos en el tratamiento del SOP.

标题: 多囊卵巢综合征与OCD治疗顺势疗法: 一例报告

摘要: 引言: 多囊卵巢综合征是一种多系统内分泌紊乱, 由于生活方式的改变和压力的增加而逐渐上升. **个案摘要:** 一例患有PCOS的29岁女性在顺势疗法治疗下表现出改善. 从患者的激素测定和超声 (USG) 报告中可以明显看出改善. 本病例报告表明, 个体化的顺势疗法药物对PCOS的治疗是有效的