

Homoeopathic management of infertility due to blockage of fallopian tube – A case series

Sumana Kumari Panda¹, Amulya Ratna Sahoo^{2*}, Chaturbhuj Nayak³, Shyama Kanungo⁴

¹Dr. Abhin Chandra Homoeopathic Medical College and Hospital, Bhubaneswar, Odisha, India, ²Drug Proving Unit of Central Council for Research in Homoeopathy, Bhubaneswar, Odisha, India, ³Homoeopathy University, Jaipur, Rajasthan, India, ⁴S. C. B. Medical College and Hospital, Cuttack, Odisha, India

Abstract

Introduction: Infertility is characterised by the failure to establish a clinical pregnancy after 12 months of regular and unprotected sexual intercourse. The prevalence of infertility in the general population is about 9–18%. Out of several causes of infertility, the tubal factor plays a role in 15.4% of cases. Homoeopathy is a gentle and effective mode of treatment. A few previous studies indicate that homoeopathy is a useful method of treatment for the treatment of infertility cases. **Cases Summary:** Four cases of female infertility due to blockage of fallopian tubes treated at Dhableswar Homeo Clinic, Cuttack, are presented herewith. The cases were treated successfully with individualised homoeopathic medicines. After the treatment, all patients conceived normally and delivered healthy babies. The medicines used were *Sepia*, *Sulphur* and *Medorrhinum* in centesimal potencies. Difficult cases of infertility with fallopian tube blockage are thus treatable and women can attain pregnancy with the help of homoeopathic treatment.

Keywords: Fallopian tube blockage, Female infertility, Homoeopathy, Hysterosalpingography

INTRODUCTION

Infertility is a common reproductive disease, with a prevalence of 9–18% of the general population.^[1] The average prevalence of infertility in developed countries is 3.5–16.7% and 6.9–9.3% in the developing countries.^[2] The risk of infertility increases with the advanced age of the female partner (>35 years).^[3] Infertility is a disease characterised by the failure to establish a clinical pregnancy after 12 months of regular and unprotected sexual intercourse or the inability to conceive children after 1 year of unprotected intercourse.^[3] Secondary infertility is the same state developing after an initial phase of sterility.^[4] Secondary infertility is the most common form of female infertility around the globe, often due to reproductive tract infections^[5] whereas genetic abnormalities, hormonal imbalances and congenital/infectious malformations of the reproductive tract are some of the common causes of male and female infertility.^[3]

Causes of infertility in women are menstrual disorders (disorders of cycle length and flow) 62.6%, diseases (obesity, thyroid diseases and diabetes) 58.7%, impaired ovulation (hormonal disorders, oligo-ovulation and anovulation)

50.3%, uterine causes 16.7%, tubal factor 15.4% and cervical causes 7.9%.^[2] Abnormalities in uterine factors, hormonal dysfunctions in ovulation disorders, tubal obstruction in disorders of the fallopian tubes, cervical stenosis in cervical factor, dysfunction of cycle length in menstrual disorders and obesity in diseases had the highest prevalence.^[2]

One study revealed the effectiveness of homoeopathic treatment in the management of female infertility by highly significant positive outcome results of conception in infertile females. This is evident in the positive results obtained in the cases of female infertility due to PCOD, chronic pelvic inflammatory disease (PID) and endometriosis. Out of 40 cases of female infertility, 27 female patients (67.5%) conceived after individualised homoeopathic treatment.^[6]

***Address for correspondence:** Dr. Amulya Ratna Sahoo, Regional Research Institute for Homoeopathy, CARI campus, Bhetapara, Guwahati-781028, Assam, India.
E-mail: drarsahoo@gmail.com

Received: 29 April 2021; **Accepted:** 10 June 2022

Access this article online

Quick Response Code:

Available in print
version only

Website:
www.ijrh.org

DOI:
10.53945/2320-7094.1073

This is an open access journal, and articles are distributed under the terms of the Creative Commons Attribution-NonCommercial-ShareAlike 4.0 License, which allows others to remix, tweak, and build upon the work non-commercially, as long as appropriate credit is given and the new creations are licensed under the identical terms.

How to cite this article: Panda SK, Sahoo AR, Nayak C, Kanungo S. Homoeopathic management of infertility due to blockage of fallopian tube – A case series. *Indian J Res Homoeopathy* 2022;16(2):178-186.

In a case report, a 37-year-old infertile woman with hydrosalpinx and the one-sided tubal block was treated successfully with constitutional homoeopathic medicines *Silicea* and *Syphilinum*. She conceived normally after 6 months of homoeopathic treatment and subsequently delivered a healthy baby at full term. This case shows the positive role of classical homoeopathic treatment of subfertility.^[7] In another study, a case series presenting five cases were treated successfully in large obstetrics and gynaecology hospital in Athens. All patients were treated with individualised homoeopathy.^[8]

In this case series, four cases of infertility due to fallopian tube blockage treated with individualised homoeopathy are presented.

STUDY SETTING

This study included four female patients suffering from primary and secondary infertility due to fallopian tube blockage, who were treated at Dhabaleswar Homeo Clinic, Cuttack, Odisha, India between the period 2006-11, however the compilation of these cases was done retrospectively in 2021. They came for homoeopathic treatment after not getting results from the treatment of other systems of medicine.

HOMOEOPATHIC THERAPEUTIC INTERVENTION

The cases were thoroughly taken and repertorisation was done by a complete repertory of HOMPAT software.^[9] The final selection of the remedy and prescriptions for each of the cases was based on the totality of symptoms of the patients and the repertorial results. Homoeopathic medicines used in the study were procured from GMP certified homoeopathic pharmaceutical companies. In each case, medicine was prescribed in pills of size 30, 4–6 globules being administered orally on a clean tongue, on empty stomach. The 1M potency was given once in 15 days and the 10 M potency was given once a month. The medicines used were *Sepia*, *Sulphur* and *Medorrhinum*. Further, through miasmatic analysis, *Medorrhinum* was given as an intercurrent remedy.

BRIEF PROCEDURE

On the first visit of each patient, case taking along with ultrasonography (USG) of the abdomen and hysterosalpingography (HSG) was performed. After analysis and evaluation of symptoms, the characteristic symptoms were considered for framing the totality. Further, based on repertorial analysis and consulting homoeopathic Materia Medica, the best suitable medicine was prescribed. The patients were advised to report at specific intervals to assess the effects of the medicine. Furthermore, the patients were advised to have a USG at the end of the treatment to assess any changes that took place over the period. The clinical progress of the patients, as well as treatment outcomes, was assessed with a focus on their symptomatology and USG findings. The assessment of the outcome and causal attribution of clinical changes were done using the Modified Naranjo Criteria.^[10]

SUMMARY OF THE CASES

The main complaints of the patients, including their age, sex, pre-/post-treatment USG/HSG/diagnostic hysterolaparoscopy (DHL) reports, prescribed medicines and duration of their treatment, are summarised in Table 1.

Case 1

A lady aged 35 years presented with secondary infertility for the past 4 years. She had normal vaginal delivery 9 years ago. She had been trying for a second child for the past 4 years. In between this period, there was no history of conception or abortions. Along with infertility, she was also suffering from repeated left-sided headache aggravated by head bath, cold weather and working in cold. She had a solitary, soft wart on her chest. Her menses were regular with normal flow. HSG reflected bilateral fallopian tube block [Figure 1]. The cause of tubal blockage could not be ascertained. She had undergone hormone replacement therapy followed by intrauterine insemination twice. A detailed case was taken and the totality of symptoms was formed based on the symptoms: Chilly patient with susceptibility to cold, desire for salty food, sleeplessness due to some unknown fear, forgetfulness, commits mistakes while writing, also omits letters, discontented with everything, very commanding and dictatorial by nature and cannot tolerate contradiction.

The case was repertorised by the complete repertory of HOMPAT software [Figure 2], and after consulting Materia Medica, *Sepia* 1M was prescribed at 15 days interval for 2 months. HSG was repeated along with USG abdomen and pelvis which revealed no blockage in the left fallopian tube and no change in the right cornual block [Figure 3].

The patient was followed up with *Sepia* 10 M, once a month for 3 months followed by *Sepia* 50M once a month for 6 months. In between, one dose of *Medorrhinum* 1M was given as an intercurrent medicine. The lady conceived after 1 year of treatment. USG of foetal well-being showed an intrauterine single live active foetus of about 29 weeks with breech presentation.

The Modified Naranjo Criteria total score was +6/13 for this patient [Table 2].

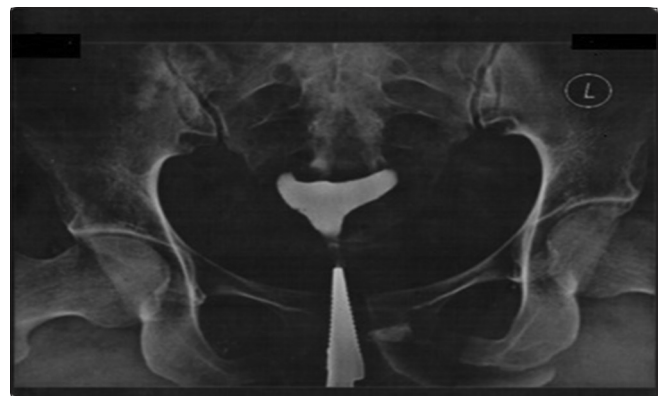

Figure 1: Hysterosalpingography of Case-1 reflecting bilateral fallopian tube block

Table 1: Cases summary

Case no.	Age/sex	Main symptoms	Pre-treatment USG/HSG/DHL report	Medicine/potency	Dose/repetition	Post-treatment USG/HSG/urine report
1.	35 y/F	Secondary Infertility of 4 years. Left-sided headache	Hysterosalpingogram (HSG) before the treatment reflected both sided fallopian tube blockage	<i>Sepia</i> 1M, 10M and 50M <i>Medorrhinum</i> 1M/1Dose as intercurrent was prescribed	Treatment period: 22 July 2011–21 May 2012 <i>Sepia</i> 1M/1 dose was prescribed at 15 days interval for 2 months <i>Sepia</i> 10M/1 dose once a month for 3 months <i>Sepia</i> 50M/1 dose once in a month for 6 months	The left fallopian tube opened Right cornual block is shown in the HSG (22 July 2011). USG done afterward confirmed a single live active foetus (21 May 2012)
2.	28 y/F	Primary infertility of 5 years. Dysmenorrhoea Thin leucorrhoea before menses Her husband had oligospermia	Left fallopian tube block on HSG Seminal fluid analysis showed low semen count (35 million/cc)	<i>Sulphur</i> 1M, 10M <i>Tuberculinum</i> 10M	Treatment period: 10 March 2010–11 June 2010 <i>Sulphur</i> 1M/1 dose, once in 15 days continued for 2 months <i>Sulphur</i> 10M/1 dose, once in a month <i>Tuberculinum</i> 10M/1 dose, once in a month for 3 months	HSG after the treatment confirmed that both the tubes are patent and single live active foetus (9 August 2010)
3.	25 y/F	Primary infertility of 5 years Delayed menses, with backache and mild dysmenorrhoea>pressure	DHL (diagnostic hysterolaparoscopy) revealed spillage from the right tube with resistance and no spillage from the left tube HSG revealed a partially blocked right fallopian tube and a completely blocked left fallopian tube	<i>Sepia</i> LM potency (0/1–0/3), <i>Medorrhinum</i> 10M/1 dose as intercurrent	Treatment period: 19 January 2006–20 May 2007 LM potency (0/1, one dose daily for 1 month followed by 0/2 and 0/3) alternating with <i>Medorrhinum</i> 10M/1 dose and this schedule repeated 3 times	Post-treatment HSG reflected bilateral tubal patency and USG done afterward showed a single live active foetus (27 June 2007)
4.	32 y/F	Primary infertility of 6 years Dysmenorrhoea < menses before, during	DHL report illustrating, ‘Endometriosis, Right tube and ovary absent, Left ovary healthy, No dye spillage seen on Left tube’	<i>Medorrhinum</i> 1M, <i>Medorrhinum</i> 10M	Treatment period: 18 December 2010–19 May 2011 <i>Medorrhinum</i> 1M, once in 15 days interval continued for 3 months followed by <i>Medorrhinum</i> 10M, once in 6 weeks interval repeated for another 3 months	A positive beta Gravindex was found in the urine report USG report confirmed a Single live active foetus (4 September 2011)

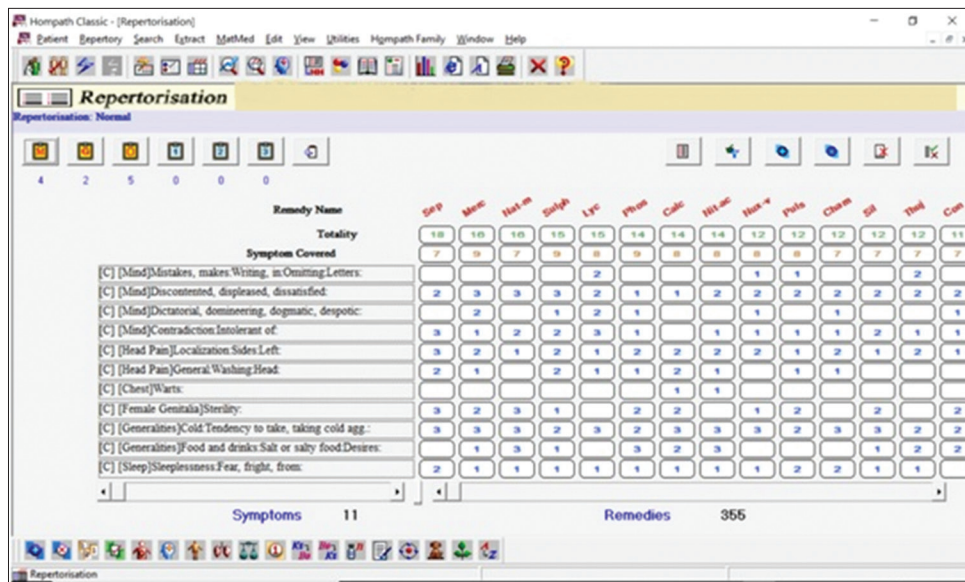
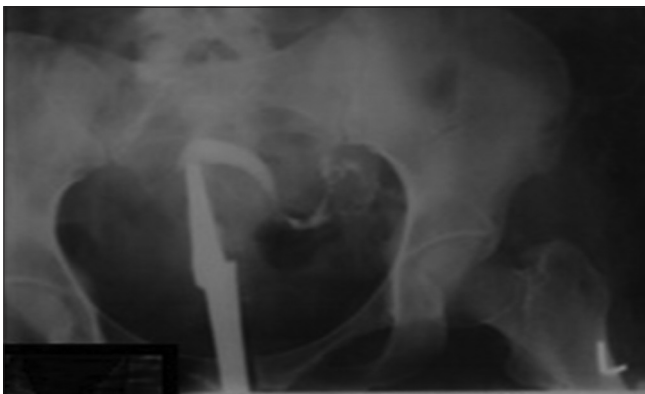

Figure 2: Repertorisation chart of Case-1 by the complete repertory of HOMPAT software

Table 2: Scores for Modified Naranjo criteria of individual patients

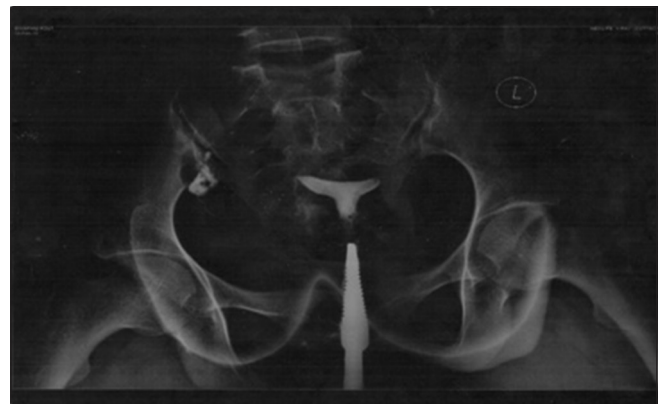Modified Naranjo Criteria	Case1	Case 2	Case 3	Case 4
1. Was there an improvement in the main symptom or condition for which the homoeopathic medicine was prescribed?	+2	+2	+2	+2
2. Did the clinical improvement occur within a plausible time frame relative to the drug intake?	+1	+1	+1	+1
3. Was there an initial aggravation of symptoms?	0	0	0	0
4. Did the effect encompass more than the main symptom or condition that is, were other symptoms ultimately improved or changed?	+1	+1	+1	+1
5. Did overall wellbeing improve?	0	+1	+1	0
6A. Direction of cure: did some symptoms improve in the opposite order of the development of symptoms of the disease?	0	0	0	0
6B. Direction of cure: Did at least two of the following aspects apply to the order of improvement in symptoms: <ul style="list-style-type: none"> • From organs of more importance to those of less importance • From deeper to more superficial aspects of the individual • From the top downwards 	0	0	0	0
7. Did 'old symptoms' (defined as non-seasonal and non-cyclical symptoms that were previously thought to have resolved) reappear temporarily during the course of improvement?	0	0	0	0
8. Are there alternate causes (other than the medicine) that – with a high probability – could have caused the improvement?	0	0	0	0
9. Was the health improvement confirmed by any objective evidence? (e.g., laboratory test, clinical observation, etc.)	+2	+2	+2	+2
10. Did repeat dosing, if conducted, create similar clinical improvement?	0	0	0	0
Total	+6	+7	+7	+6

(maximum score+13, minimum score-3)

**Figure 3:** Hysterosalpingography of Case-1 reflecting no blockage in the left fallopian tube and no change in the right cornual block

Case 2

A 28-year-old lady presented with primary infertility; the couple was planning for the baby since 5 years. She also had dysmenorrhoea before and during menses. Along with this, thin leucorrhoea before menses was one of her other main symptoms. A thorough case taking was carried out which reflected important physical generals like the desire for meat and milk; with constipated and hard stool. As regards mental symptoms, it was found that the patient was irritable, hasty, restless, quarrelsome and cannot tolerate injustice. In the past, she had suffered from chronic diarrhoea and recurrent fever. Her mother had PID and cholelithiasis. HSG report indicated a left fallopian tube block [Figure 4]. Other routine blood tests and hormonal assessments were normal. The case was repertorised

**Figure 4:** Hysterosalpingography of Case-2 reflecting left fallopian tube block

by the complete repertory of HOMPETH software [Figure 5] and *Sulphur* 1M/1 dose, once in 15 days was prescribed for 2 months followed by *Sulphur* 10M/1 dose once a month.

Her husband had oligospermia with increased pus cells count on seminal analysis but had no other physical complaints. Detailed case history of the husband was taken. Physical generals revealed susceptible to cold, aversion to milk. Mental symptoms presented as angers easily, discontented due to low socioeconomic status, desires to be alone. He had a very peculiar history that his mother suffered from tuberculosis during pregnancy. Considering this might be a causative factor and keeping in view to physical generals, mental generals, again oligospermia belonging to tubercular miasm,

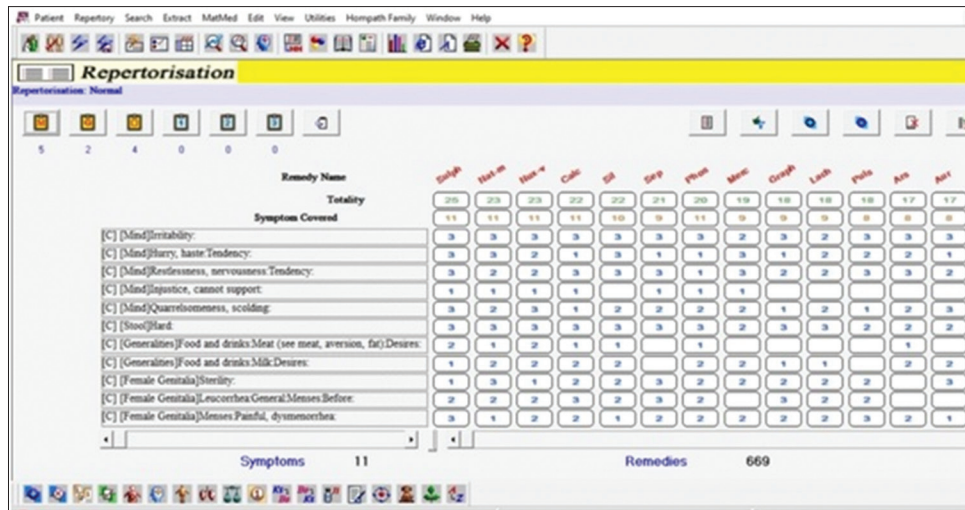


Figure 5: Repertorisation chart of cCase-2 by the complete repertory of HOMPAT software

Tuberculinum 10M, once in a month for 3 months prescribed to husband. The lady conceived after 3 months of treatment.

The lady conceived after 3 months of treatment as the urine examination pregnancy test was positive and an obstetric report showed a single live foetus of about 14 weeks. Lady gave birth to a female child of 2.5 kg by normal vaginal delivery. After 1 year of delivery, on doing HSG, it was revealed that both the tubes were patent after homoeopathic treatment. The lady delivered another male child after 3 years, with no complications.

The total Modified Naranjo Criteria score was +7/13 for this patient [Table 2].

Case 3

A 25-year-old lady suffering from primary infertility; the couple was planning for the baby for the past 5 years, presented with delayed menses; scanty, thin, pale menstruation, associated with backache and mild dysmenorrhoea, ameliorated by pressure. She was depressed, did not want to talk or listen to anything, weeping without any cause, aggravated during menses, in the evening. DHL revealed spillage from the right tube with resistance and no spillage from the left tube. HSG revealed a partially blocked right fallopian tube and a completely blocked left fallopian tube [Figure 6]. Physical generals included hot patient, with susceptibility to cold; thirstless; desire for sour, salty food, fish, spices; aversion to milk. Her mental symptoms developed after marriage when she could not adjust herself in her in-law house. She developed a fear of adjustment, committing mistakes, being criticised and impending diseases. She started avoiding people and developed a weeping tendency that aggravated at night, but consolation ameliorated her mental complaints. She was indifferent to everything; ailments from grief; irritability aggravated from the conversation, depression, gloominess, sadness aggravated during menses, evening, when alone. She was an introvert and used to brood over the past events.

The case was repertorised by the complete repertory of

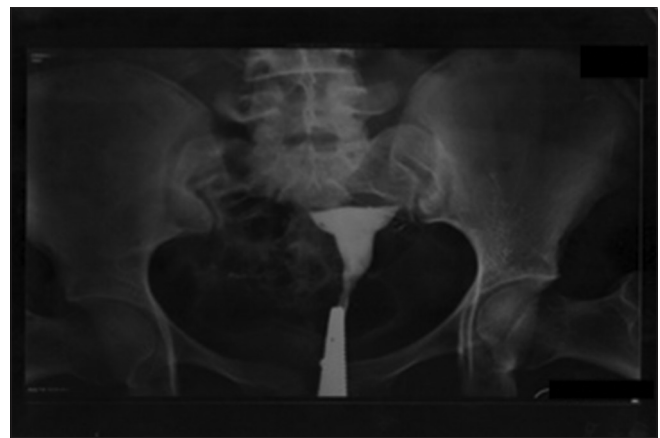

Figure 6: Hysterosalpingography of Case-3 revealed a partially blocked right fallopian tube and a completely blocked left fallopian tube

HOMPAT software [Figure 7], and *Sepia* was prescribed in LM potencies (0/1 to 0/3) for 3 months, but no conception occurred. The HSG revealed bilateral tubal patency [Figure 8]. Intercurrent anti-miasmatic medicine *Medorrhinum* 10M/1 dose was given, followed by *Sepia* in LM potencies after 1 month interval and this schedule was repeated 3 times, which finally resulted in pregnancy. USG revealed a single live foetus at about 38 weeks with cephalic presentation.

No complications during the antenatal period were seen. *Sepia* in LM potencies was continued as a constitutional remedy throughout pregnancy.

The lady delivered a girl child and subsequently a boy at a gap of 3 years.

The total Modified Naranjo Criteria score was +7/13 [Table 2].

Case 4

A lady of 32 years presented with primary infertility; the couple was planning for the baby for 6 years. Menses were regular with normal flow, red, fluid blood; dysmenorrhoea aggravated during and before menses. A thorough case taking was done

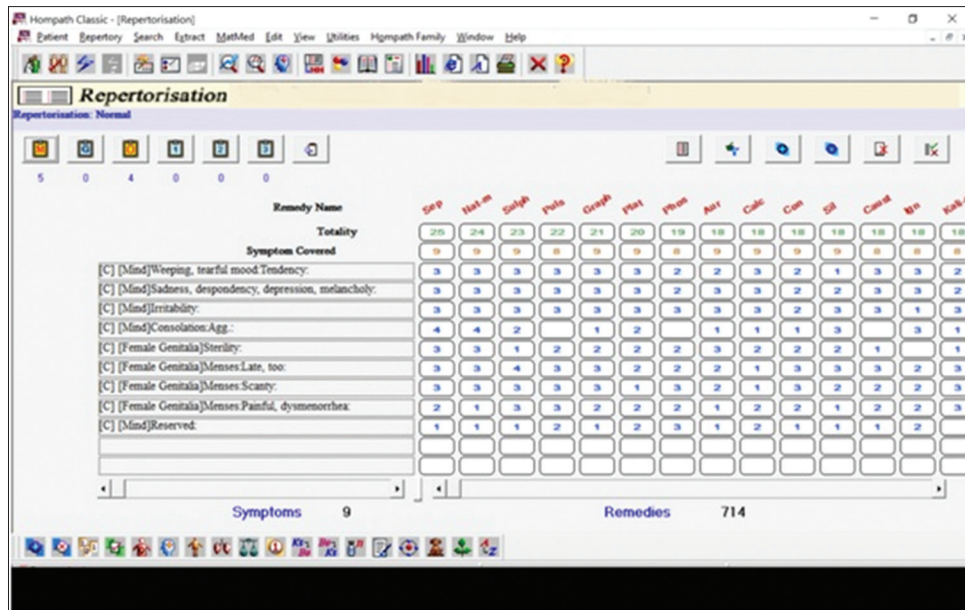


Figure 7: Repertorisation chart of Case-3 by the complete repertory of HOMPETH software

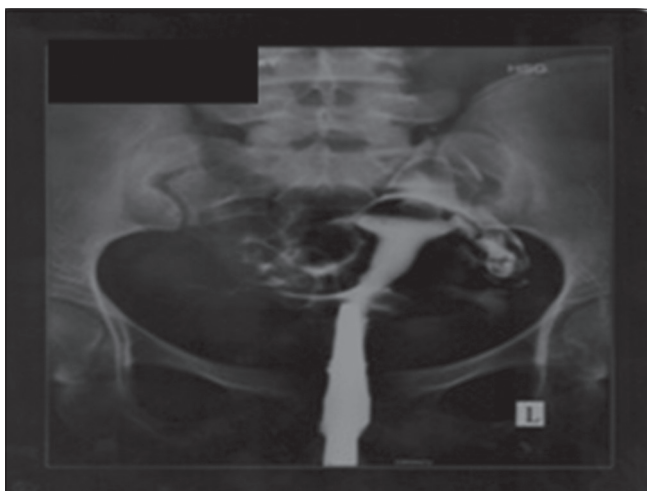


Figure 8: The hysterosalpingography of Case-3 revealing bilateral tubal patency

which revealed physical generals such as hot patient, desire for chocolate and ice cream. In the past, she had suffered from recurrent leucorrhoea with pruritus vulvae which started after marriage. Furthermore, she had undergone abdominal surgery one year earlier for a large cystic mass (11.2 cm x 10.7 cm) in the midline of the pelvis (most likely a right ovarian cyst). The DHL report showed endometriosis, absence of right tube and ovary, left ovary healthy and no dye spillage seen on the left tube. In the family, her father had a brain tumour. Her husband had gonorrhoea 5 years ago for which he took allopathic treatment. Hence, history and family history were very significant which guided the case for the selection of remedy. This case was too deficient in general symptoms but its strong, peculiar, characteristic anamnesis indicated a deep anti-sycotic miasmatic medicine. After case taking and repertorisation by the complete repertory of HOMPETH

software, *Medorrhinum* 1M/1 dose was prescribed once in 15 days for 3 months followed by *Medorrhinum* 10M/1 dose, once in 6 weeks for another 3 months [Figure 9]. After 8 months of treatment, the patient happily came with a positive beta Gravindex report. Antenatal check-ups with homoeopathic medicines continued and the obstetric report showed a single live foetus at about 21 weeks.

The total Modified Naranjo Criteria score was +6/13 [Table 2].

DISCUSSION

There are very limited studies in the medical literature signifying homoeopathic treatment in the conditions of female infertility. Only a few previous studies have indicated that individualised or constitutional homoeopathic treatment is effective in the treatment of female infertility.^[6-8] In this study, four cases of primary and secondary infertility due to fallopian tube blockage are treated with homoeopathic medication. All four patients were in their reproductive age group. Patients presented with infertility with symptoms such as delayed, scanty and irregular menses; dysmenorrhoea, leucorrhoea and peculiar, characteristic mental symptoms and physical generals. The HSG reports showed bilateral or unilateral fallopian tube blockage.

After thorough case taking, repertorisation by the complete repertory of HOMPETH software and on consulting homoeopathic Materia Medica, the best suitable remedies were selected and prescribed in 1M, 10M and 50M potencies. After completion of treatment, all the patients conceived normally and subsequently delivered healthy babies at full term.

In all these cases, medicines were selected based on the totality of the symptoms after individualisation and considering the constitution of the patient. Some previous studies have

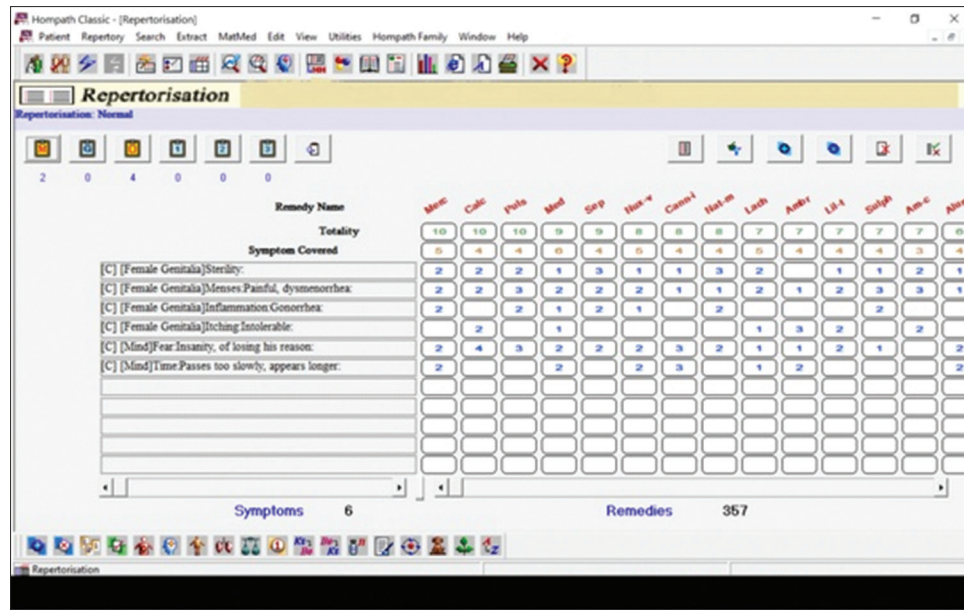


Figure 9: Repertorisation chart of Case-4 by the complete repertory of HOPATH software

also indicated the efficacy of individual or constitutional homoeopathic medicines in the treatment of secondary infertility.^[6-8] However, reported evidence on homoeopathic treatment for secondary infertility, specifically due to fallopian tube blockage, is sparse.

Further, the total Modified Naranjo Criteria scores in all four cases were 6, 7, 7 and 6, respectively [Table 2]. This explicitly shows the causal attribution of the homoeopathic treatment toward curing infertility due to tubal blockage in females. Thus, the outcomes of these cases indicate the usefulness of the homoeopathic treatment. Significant improvement at pathological levels as per HSG and USG reports, along with improvement in mental and physical symptoms after the application of individualised homoeopathic medicines, re-establish the effectiveness of homoeopathic treatment which is gentle, harmless and cost effective. Thus, well-selected homoeopathic medications can help to improve the quality of life and chances of conception, thereby also enhancing the chances to avoid the use of hormonal tablets or related surgery.

CONCLUSION

A well-indicated constitutional homoeopathic medicine, based on the totality of symptoms, could be a useful treatment for the management of female infertility with blockage of the fallopian tube. As in this case series, this approach helped the patients to conceive normally. A randomised, comparative study (homoeopathic therapy vs. conventional therapy), with a suitable sample size, is suggested for further advancement in this regard.

ACKNOWLEDGEMENT

The authors are grateful for the help and support of the radiologists and the patients.

Declaration of patient consent

Written informed consent was obtained from each patient for publication of their cases anonymously in an academic journal.

Financial support and sponsorship

Nil.

Conflicts of interest

None declared.

REFERENCES

- Green J, Kahan M, Wong S. Obstetric and gynecologic resident ultrasound education project: Is the current level of gynecologic ultrasound training in Canada meeting the needs of residents and faculty? *J Ultrasound Med* 2015;34:1583-9.
- Masoumi SZ, Parsa P, Darvish N, Mokhtari S, Yavangi M, Roshanaei G. An epidemiologic survey on the causes of infertility in patients referred to infertility center in Fatemeh hospital in hamadan. *Iran J Reprod Med* 2015;13:513-6.
- Sabarre KA, Khan Z, Whitten AN, Remes O, Phillips KP. A qualitative study of Ottawa university students' awareness, knowledge and perceptions of infertility, infertility risk factors and assisted reproductive technologies (ART). *Reprod Health* 2013;10:41.
- Pratap K, Narendra M. *Jeffcoate's Principles of Gynaecology*. 7th ed. New Delhi: Jaypee Brothers Medical Publishers (P) Ltd.; 2008.
- Vander Borgh M, Wyna C. Fertility and infertility: Definition and epidemiology. *Clin Biochem* 2018;62:2-10.
- Anita L, Prema D, Blany L. Effectiveness of homoeopathic treatment in female infertility. *Reprod Med Int* 2018;1:1-5.
- Parveen S, Bhaumik H. Effect of individualised Homoeopathy in the treatment of infertility. *Indian J Res Homoeopath* 2018;12:231-39.
- Kalampokas T, Botis S, Kedikgianni-Antoniou A, Papamethodiou D, Kivellos S, Papadimitriou V, *et al.* Homeopathy for infertility treatment: A case series. *Clin Exp Obstet Gynecol* 2014;41:158-59.
- Shah JJ. *Homopath Classic-homeopathic Software*. Mumbai: Mind Technologies Private Limited; 2005.
- Lamba CD, Gupta VK, van Haselen R, Rutten L, Mahajan N, Molla AM, *et al.* Evaluation of the modified naranjo criteria for assessing causal attribution of clinical outcome to homeopathic intervention as presented in case reports. *Homeopathy* 2020;109:191-7.

Titre: Traitement homéopathique de l'infertilité due à l'obstruction des trompes de Fallope - Une série de cas

Résumé : Introduction: L'infertilité se caractérise par l'impossibilité d'établir une grossesse clinique après 12 mois de rapports sexuels réguliers et non protégés. La prévalence de l'infertilité dans la population générale est d'environ 9 à 18 %. Parmi les nombreuses causes d'infertilité, le facteur tubaire joue un rôle dans 15,4 % des cas. L'homéopathie est un mode de traitement doux et efficace. Quelques études antérieures indiquent que l'homéopathie est une méthode de traitement utile pour le traitement des cas d'infertilité. **Case Summary:** Nous présentons ici quatre cas d'infertilité féminine due à un blocage des trompes de Fallope traités à la Dhabaleswar Homeo Clinic, Cuttack. Les cas ont été traités avec succès avec des médicaments homéopathiques individualisés. Après le traitement, toutes les patientes ont conçu normalement et ont donné naissance à des bébés en bonne santé. Les médicaments utilisés étaient Sepia, Sulphur, et Medorrhinum en puissances centésimales. Les cas difficiles d'infertilité avec blocage des trompes de Fallope peuvent être traités et les femmes peuvent tomber enceintes grâce à un traitement homéopathique. Le traitement homéopathique s'est donc avéré utile dans les cas d'infertilité avec blocage des trompes de Fallope.

Titel: Homöopathische Behandlung von Unfruchtbarkeit aufgrund von Eileiterverstopfung - eine Fallserie

Abstract: Introduction: Unfruchtbarkeit ist gekennzeichnet durch das Ausbleiben einer klinischen Schwangerschaft nach 12 Monaten regelmäßigen und ungeschützten Geschlechtsverkehrs. Die Prävalenz der Unfruchtbarkeit in der Allgemeinbevölkerung liegt zwischen 9 % und 18 %. Von den verschiedenen Ursachen der Unfruchtbarkeit spielt der Eileiterfaktor in 15,4 % der Fälle eine Rolle. Die Homöopathie ist eine sanfte und wirksame Behandlungsmethode. Einige frühere Studien weisen darauf hin, dass die Homöopathie eine nützliche Behandlungsmethode für die Behandlung von Unfruchtbarkeitsfällen ist. **Zusammenfassung des Falls:** Hier werden vier Fälle weiblicher Unfruchtbarkeit aufgrund einer Blockade der Eileiter vorgestellt, die in der Dhabaleswar Homeo Clinic in Cuttack behandelt wurden. Die Fälle wurden erfolgreich mit individualisierten homöopathischen Arzneimitteln behandelt. Nach der Behandlung wurden alle Patientinnen normal schwanger und brachten gesunde Babys zur Welt. Die verwendeten Arzneimittel waren Sepia, Sulphur und Medorrhinum in Zentesimalpotenzen. Schwierige Fälle von Unfruchtbarkeit mit Verstopfung der Eileiter sind behandelbar, und die Frauen werden mit Hilfe der homöopathischen Behandlung schwanger. Die homöopathische Behandlung erwies sich also als nützlich bei Unfruchtbarkeit mit Eileiterverstopfung.

शीर्षक: गर्भाशय नली रुकावट के कारण बांझपन के होम्योपैथिक द्वारा प्रबंधन – विषय श्रृंखला

सार: परिचय: बांझपन नियमित और असुरक्षित संभोग के 12 महीनों के बाद नैदानिक गर्भावस्था स्थापित करने में विफलता है। सामान्य आबादी में बांझपन का प्रसार लगभग 9% से 18% है। बांझपन के कई कारणों में से, नली कारक 15.4% विषयों में है। होम्योपैथी उपचार का एक सौम्य और प्रभावी तरीका है। पिछले कुछ अध्ययनों से संकेत मिलता है कि होम्योपैथी बांझपन के मामलों के उपचार के लिए एक उपयोगी तरीका है। **विषय सारांश:** ढाबलेश्वर होमियो क्लिनिक, कटक में इलाज किए गए गर्भाशय नली रुकावट के कारण महिलाओं के बांझपन के चार मामलों को इसके साथ प्रस्तुत किया गया है। व्यक्तिगत होम्योपैथिक दवाओं के साथ मामलों का सफलतापूर्वक इलाज किया गया था। उपचार के बाद, सभी रोगियों ने सामान्य रूप से गर्भधारण किया और स्वस्थ बच्चों को जन्म दिया। इस्तेमाल की जाने वाली दवाएं सेंटीसीमल शक्ति में सेपिया, सल्फर और मेडोररिनम था। गर्भाशय नली रुकावट के साथ बांझपन के कठिन मामले इलाज योग्य हैं और महिलाएं होम्योपैथिक उपचार की मदद से गर्भावस्था प्राप्त करती हैं। इस प्रकार होम्योपैथिक उपचार को गर्भाशय नली रुकावट के साथ बांझपन के मामलों में उपयोगी पाया गया था।

Título: Manejo Homeopático de la Infertilidad Debido a la Obstrucción de las Tubas de Falopio - Serie De Casos

Resumen: Introducción: La infertilidad se caracteriza por la incapacidad de establecer un embarazo clínico después de 12 meses de relaciones sexuales regulares y sin protección. La prevalencia de infertilidad en la población general es de 9 a 18%. De varias causas de infertilidad, el factor tubárico juega un papel en el 15,4% de los casos. La homeopatía es un modo de tratamiento suave y eficaz. Algunos estudios anteriores indican que la Homeopatía es un método útil de tratamiento para el tratamiento de casos de infertilidad. **Resumen del caso:** Se presentan cuatro casos de infertilidad femenina por obstrucción de la trompa de Falopio tratados en la Clínica Dhabaleswar Homeo, Cuttack. Los casos fueron tratados con éxito con medicamentos homeopáticos individualizados. Después del tratamiento, todos los pacientes concibieron normalmente y entregaron bebés sanos. Los medicamentos utilizados fueron Sepia, Sulphur y Medorrhinum en potencias centesimales. Los casos difíciles de infertilidad con obstrucción de la trompa de Falopio son tratables y las mujeres alcanzan el embarazo con la ayuda del tratamiento homeopático. El tratamiento homeopático fue así encontrado para ser útil en casos de infertilidad con obstrucción de la trompa de Falopio.

标题：输卵管堵塞不孕症的顺势疗法治疗-A例系列

摘要：引言：不孕症的特点是在12个月的定期和无保护的性交后未能建立临床妊娠。一般人群中不孕症的患病率约为9%至18%。在不孕的几个原因中，输卵管因素在15.4%的病例中起作用。顺势疗法是一种温和有效的治疗方式。以前的一些研究表明，顺势疗法是治疗不孕症病例的有用方法。个案摘要：在达巴勒斯瓦尔*霍梅奥诊所治疗的四例女性输卵管堵塞不孕症，现附上切塔克。用个体化的顺势疗法药物成功治疗了这些病例。治疗后，所有患者正常怀孕并分娩健康婴儿。使用的药物是乌贼, 乌贼, 硫磺和成百上千万效力的髓核。输卵管堵塞不孕困难病例是可以治疗的, 妇女在顺势疗法的帮助下怀孕。因此, 顺势疗法治疗在输卵管阻塞不孕症中是有用的