

# Individualized homeopathy in a case of liver abscess: A case report

Jyoti Chhikara, Rahul Singh

Homoeopathic Consultants, New Delhi, India

## Abstract

**Introduction:** Liver abscesses (LAs) are purulent collections in the liver parenchyma that result from bacterial, fungal, or parasitic infection which can spread to the liver by extension of an adjacent infection, or as a result of trauma. Homoeopathic approach of treating the disease based on symptom totality is a relevant alternative to often unsatisfactory conventional medicine in cases of LA. **Case Summary:** A 35-year-old male who presented with LA was treated with homoeopathic medicine based on the totality of symptoms and significant improvement was seen with resolution of abscess in the liver along with relief in other presenting symptoms. This enhances our belief in the potential of individualized homeopathy in treating infectious conditions.

**Keywords:** *Bryonia alba*, Homoeopathy, Individualization, Liver abscess

## INTRODUCTION

Liver abscess (LA) is a pus-filled mass in the liver that develops from injury to the liver or an intra-abdominal infection disseminated from the portal circulation. It occurs most commonly in the age group of 20–45 years and males are more frequently affected than females.<sup>[1]</sup> LA can arrive either from an ischemic episode or by bacteria entering through the portal vein.<sup>[2,3]</sup> Septic emboli cause several micro-abscesses which combine to form one large abscess. Hematogenous spread from endocarditis or pyelonephritis can happen. It can be either pyogenic or amoebic. Most amoebic infections are caused by *Entamoeba histolytica*. The pyogenic abscesses have polymicrobial origin, such as *Escherichia coli*, *Klebsiella*, *Streptococcus*, *Staphylococcus*, and anaerobes. About 50% of solitary LAs occur in the right lobe of the liver (a more significant part with more blood supply), less commonly in the left liver lobe or caudate lobe. LA may present as an acute process or as a chronic disease, based on duration of illness and severity. Most patients present with an acute illness and duration of symptoms <2 weeks with abdominal pain usually moderate and localized to the right upper quadrant, fever, and anorexia as presenting features. Diffuse abdominal pain, pleuritic chest pain, and radiation of right upper quadrant pain to the right shoulder are not uncommon. Fever is of moderate degree in most cases, while high fever with chills is suggestive of secondary bacterial infection. Tender hepatomegaly is detected in up to

80% of patients. The incidence of LA is low but the mortality risk remains high in untreated patients.<sup>[4]</sup> The initial test of choice is abdominal ultrasonography, which shows hyper or hypo-echoic lesions with occasional debris or septation.

Homoeopathic remedies can offer gentle and safe treatment for patients suffering from LA. Homeopathy is an alternative system of medicine where the selection of remedy is based upon detailed medical history of the patient, family and causative factors, underlying predisposition factor, and susceptibility. This case highlights the importance of individualization and law of single, simple homoeopathic medicine in the treatment of LA.

## CASE REPORT

### Patient information

A 35-year-old male presented with acute pain in the right hypochondriac region with aggravation of pain on any kind

**\*Address for correspondence:** Jyoti Chhikara,  
Department of Pulmonary Medicine, Critical Care and Sleep  
Disorders, All India Institute of Medical Sciences, New Delhi, India.  
E-mail: drjyotichhikara93@gmail.com

**Received:** 19 September 2020; **Accepted:** 18 February 2022

This is an open access journal, and articles are distributed under the terms of the Creative Commons Attribution-NonCommercial-ShareAlike 4.0 License, which allows others to remix, tweak, and build upon the work non-commercially, as long as appropriate credit is given and the new creations are licensed under the identical terms.

**How to cite this article:** Chhikara J, Singh R. Individualized homeopathy in a case of liver abscess: A case report. Indian J Res Homoeopathy 2022;16(1):55-60.

### Access this article online

#### Quick Response Code:

Available in print  
version only

**Website:**  
www.ijrh.org

**DOI:**  
10.53945/2320-7094.1059

of movement, even breathing, with a history of fever 3 days ago. These complaints were there in the past 2 days but had worsened on the day of reporting.

Patient had not received any treatment before reporting. He also had an episode of watery stools with slight nausea. There was a constant urge to urinate frequently, with pain in right lower abdomen with fever and chills one week ago. Patient wanted to stay still, and kept his hand over the liver region and mentioned that his pain ameliorated on application of slight pressure.

There was no history of recent consumption of food from outside. Appetite was poor since the pain developed, but he was constantly thirsty and desired cold water.

### Personal history

Family history of hepatic disease or any other comorbidity was negative. He had a habit of taking highly spiced and fried food, and drinking less quantity of liquids. There was no history of consumption of alcoholic drinks or tobacco in any form.

### Clinical and laboratory findings

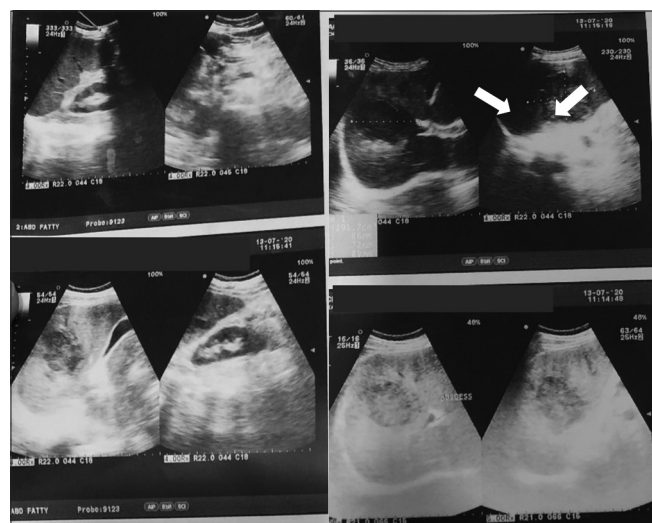On abdominal examination, tenderness was observed in right hypochondrium which ameliorated on applying gentle pressure over the region. There was continuous moderate pain of stitching character. No sign of guarding could be elicited.

Investigations such as complete blood count, liver function tests, inflammatory markers, coagulation profile were advised but not done as the patient had financial constraints, due to which only ultrasonography could be performed.

Ultrasonography of abdomen revealed hepatomegaly with liver span of 18–19 cm, with a hypo-echoic lesion of 88 × 78 × 68 mm with volume of 230 cc in right lobe. Spleen was enlarged to a span of 15.8 cm. There was hepatomegaly with evolving LA and splenomegaly as seen in Figure 1.

### Provisional diagnosis

Amoebic LA.



**Figure 1:** Ultrasonography- whole abdomen (13 June, 2020) showing a hypo-echoic lesion in the right lobe of liver

### Totality of symptoms

The patient was timid, and anxious about how he developed the disease, worried about his work (as he would have to take leave), answered briefly (most answers had to be confirmed from attendant); did not want to talk, wanted to be quiet, and take rest, desired cold food and drinks, had unquenchable thirst for cold water, sensation of fullness of bladder, frequent desire to urinate, loose stools since morning, pain in the right side of the abdomen (right hypochondrium), desire for complete rest, pain better by pressure.

### Analysis of the case

After analyzing the symptoms of the case, the characteristic mentals, physical generals and particular symptoms were considered for framing the totality. Timidity, desire to be quiet, and worried about business, desired cold food and drinks, had unquenchable thirst for cold water were the important general symptoms while frequent desire to urinate, loose stools since morning, pain in the right side of abdomen better by pressure were the particulars included in totality. Repertorisation was done using RADAR (Synthesis 8.1),<sup>[5]</sup> and the symptoms considered for repertorisation are shown in Figure 2. *Bryonia alba* was the highest scoring medicine and covered maximum rubrics in higher grade.

### Intervention

Homoeopathic medicines *Bryonia alba*, *Sulphur*, *Arsenic album*, and *Belladonna* were the top four medicines in the repertorisation sheet. *Bryonia alba* covered the totality of the patient in the highest grade. The characteristic burning of *Sulphur* was not present as a chief complaint and desire to be quiet and rest, was also not covered by it, hence not selected as similimum for the case. The characteristic restlessness and amelioration by warmth of *Arsenic album* was not present in this case, also the characteristic modality of amelioration of pain by pressure was not covered under *Arsenic* after repertorisation. *Belladonna* is an excellent remedy for pyogenic conditions of skin and glands, but the characteristic modalities of *Belladonna*, that is, aggravation from touch, lying down were contradictory in this case, as the patient reported pain better by pressure and had desire to rest. *Bryonia* was selected as the similimum of the case on the basis of totality, individualization, and after consideration of Materia Medica and Repertory.

### Prescription

Three doses of *Bryonia alba* 200C were prescribed on 13 July 2020, to be taken at 6 h intervals followed by placebo for 5 days. On subsequent follow-ups, repetition of medicine was done upon assessment of symptoms and investigations. The patient was taking only homoeopathic medicines during the course of treatment.

Patient was advised to avoid all kinds of oily and fried food, take plenty of water and avoid overeating. He was also asked to take adequate rest and refrain from any kind of strenuous activity. During the course of treatment, patient did not have to take antibiotics or any other conventional treatment.

### Follow-up

During the follow-ups, the patient's status was assessed and subsequent ultrasonography was done at 15-day intervals for 1 month. Follow-ups details are summarized in Table 1.

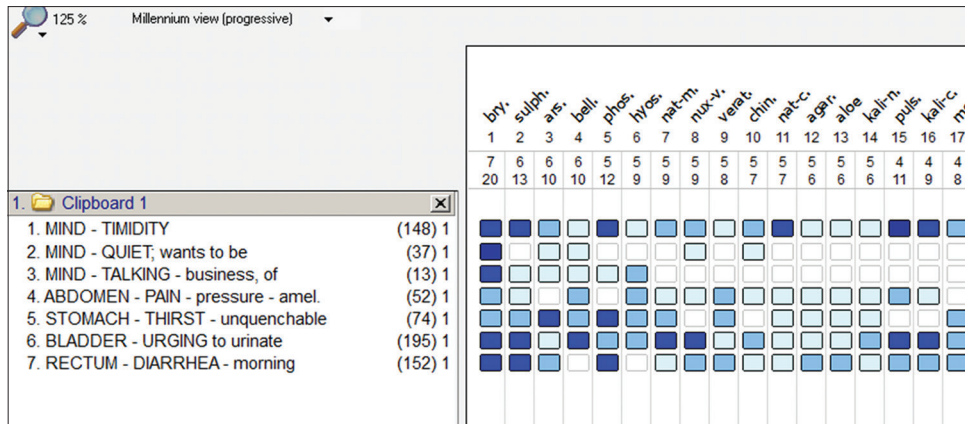


Figure 2: Repertorisation: RADAR (Synthesis 8.1)

Table 1: Timeline of the follow-up

S. No	Date	Symptoms/findings	Prescription
1.	13 June, 2020	USG Abdomen [Figure 1] -Hepatomegaly with liver span of 18–19 cm with a hypo-echoic lesion 88×78×68 mms with volume of 230 cc in right lobe. Spleen enlarged to a span of 15.8 cm. “Hepatomegaly with evolving liver abscess in right lobe with Splenomegaly”	<i>Bryonia alba</i> 200 C/3 doses/6 hourly Followed by Placebo 200 C/ TDS/5 days
2.	18 June, 2020	Patient reported that pain had subsided to about 80% by the next day after reporting. The pain was better but there was mild irritation in the right hypochondriac region<exhalation, sneezing, coughing. There was no episode of loose stools, fever after the first prescription	Placebo 200 C/TDS/10 days
3.	27 June, 2020	Appetite much improved and thirst for cold water, after which he felt better. Frequency of urination decreased USG – Abdomen report revealed mild hepatomegaly with a hypo-echoic lesion 69×68×66 mms with volume of 150 cc in right lobe (resolving). Spleen enlarged to a span of 14.8 cm. A small hypo-echoic lesion measuring 34×21 mms posterior to this lesion has appeared	<i>Bryonia alba</i> 200 C/1 dose/OM Followed by Placebo 200 C/ TDS/15 days
4.	11 August, 2020	Patient was feeling better with no pain. Appetite was much improved. Desire for spicy, fried food. Stools were satisfactory with no alterations. Patient has resumed going to work USG – Abdomen revealed a liver of normal size with resolving abscess and cystic lesion of about 50 cc volume in right lobe. No pus is seen to be present. Another tiny lesion measuring 34×21 mms which appeared in right lobe in previous scan has reduced in size, now measuring 10×11 mms	Placebo 200 C/TDS/15 days
5.	11 September, 2020	No complain of pain even on exertion; appetite restored to normal and no mental anxiety Patient had reported that the improvement of his complaints with homoeopathic treatment strengthened his belief in homoeopathy	Placebo 200 C/TDS/15 days

The presented case of LA showed marked improvement with single homeopathic medicine *Bryonia alba*. There was significant clinical as well as radiographic progress, in over a period of 1 month of treatment, inferred on the basis of improvement of generals and particular symptoms of the case as well as resolution of abscess and regression of liver to its pre-infection size as evident via series of ultrasonography [Figures 3 and 4].

### DISCUSSION

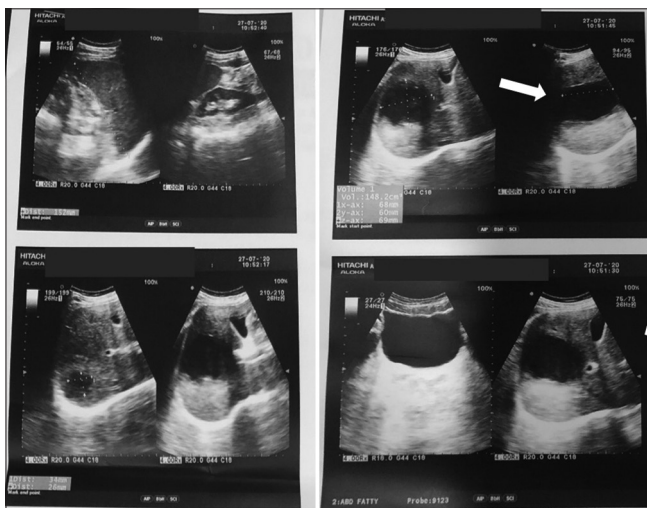This case highlights the usefulness of homoeopathic medicines in the management of LA. In this case, after careful history recording, repertorisation, and consultation with Materia Medica, *Bryonia alba* was prescribed. The patient had not undergone any treatment before for this complaint. The patient responded

positively to the homoeopathic treatment and was relieved of his pain, with an effective resolution and reduction of pus, as evident from the ultrasound reports. On subsequent follow-up, liver biopsy and FNAC to rule out whether pyogenic or amoebic LA was advised but was not performed as patient showed symptomatic relief and had already discussed his financial limitations. It was treated as probable case of amoebic LA based on sudden history of onset of abdominal pain, fever with chills, and involvement of the right lobe of the liver mainly.<sup>[6]</sup> The case was assessed for the likelihood of causality between the homoeopathic intervention and outcome as per Modified Naranjo criteria for Homoeopathy.<sup>[7]</sup> Under MoNarCh<sup>[7]</sup> domains 3, 7, 6, and 10 were not established in this report but other domains were largely established. The total score of outcome was 8 [Table 2]

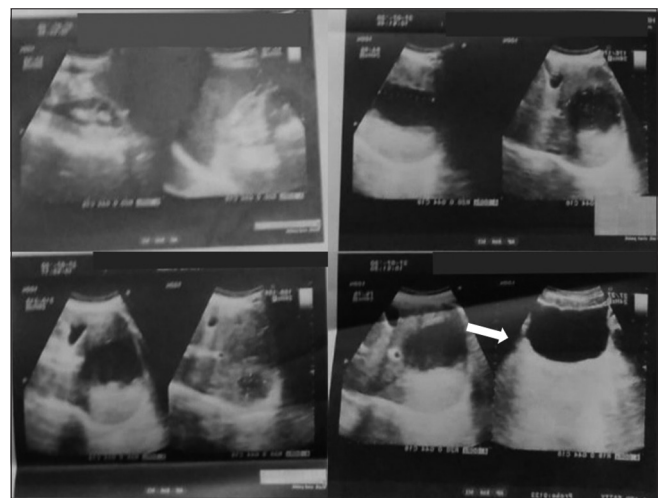
**Table 2: Monarch inventory (improved version of the modified Naranjo criteria for Homoeopathy)<sup>[7]</sup>**

Domains	Yes	No	Not sure or N/A	Score for successfully treated cases	Justification
Was there an improvement in the main symptom or condition for which the homoeopathic medicine was prescribed?	+2	-1	0	2	Right hypochondrium pain (due to underlying LA) was the chief complain which disappeared after treatment
Did the clinical improvement occur within a plausible time frame relative to the drug intake?	+1	-2	0	1	Improvement of symptoms occurred within initial 5 days while complete resolution occurred within a period of 2 months after medicine
Was there an initial aggravation of symptoms?	+1	0	0	0	Not observed
Did the effect encompass more than the main symptom or condition (i.e., were other symptoms ultimately improved or changed)?	+1	0	0	1	There was improvement in mental generals and physical generals as well
Did overall well-being improve? (suggest using validated scale)	+1	0	0	1	Overall well-being as there was no other illness during and after treatment
Direction of cure: did some symptoms improve in the opposite order of the development of symptoms of the disease?	+1	0	0	0	Not observed
Direction of cure: did at least two of the following aspects apply to the order of improvement of symptoms: • From organs of more importance to those of less importance? • From deeper to more superficial aspects of the individual? • From the top downwards?	+1	0	0	0	Not observed
Did “old symptoms” (defined as non-seasonal and non-cyclical symptoms that were previously thought to have resolved) reappear temporarily during the course of improvement?	+1	0	0	0	Not observed
Are there alternate causes (other than the medicine) that—with a high probability— could have caused the improvement? (Consider known course of disease, other forms of treatment, and other clinically relevant interventions)	-3	+1	0	1	In infectious conditions such a LA there are very low chances of improvement without appropriate medicinal intervention.
Was the health improvement confirmed by any objective evidence? (e.g., laboratory test, clinical observation, etc.)	+2	0	0	2	Yes by Ultrasonography reports after every 15 days
10. Did repeat dosing, if conducted, create similar clinical improvement?	+1	0	0	0	Not observed

Total Score=8



**Figure 3:** Ultrasonography - whole abdomen (27 June, 2020) showed mild hepatomegaly with a hypo-echoic lesion. Spleen enlarged to a span of 14.8 cm



**Figure 4:** Ultrasonography- whole abdomen (11 August, 2020): showed liver normal in size with resolving abscess

which suggests the causal relationship between homeopathic intervention and outcome in this case.

*Bryonia alba* covered the mental symptoms well, such as timidity, anxiety about how he developed the disease, aversion to answer, wants to be quiet, rest; and worried about his work. Also, the physical symptoms like desire for cold food and drinks, unquenchable thirst for cold water, frequent urination, pain in the right side of the abdomen (right hypochondrium), desire for complete rest, pain better by pressure were also covered by the medicine. As mentioned in the homeopathic literature,<sup>[8,9]</sup> the mechanism of action of *Bryonia alba* is such that it corresponds to fevers of almost all kinds, especially rheumatic, typhoid, bilious and remitting. In these, as in all other complaints, the exquisite sensitiveness of the drug to the movement of all kinds is a leading characteristic.

In the above case it is observed that though the natural tendency of conditions with pus accumulations and abscesses is pain on touch and motion; in this particular case, there was relief in the pain of the right hypochondrium region from pressure. Moreover, the patient entered the consultation room with his hand on the liver region and remained in same posture during entire narration process. Thus, amelioration by pressure and complete rest being leading characteristics of *Bryonia alba*, guided us toward the remedy for this case. Furthermore, it is verified that the amelioration from pressure is not applicable only for external impressions but internal manifestations as well. The 200 C potency was found to be useful in this case. Only four doses of *Bryonia alba* 200 C were required for pus to resolve completely. Furthermore, the patient showed significant improvement regarding mental symptoms as well as decreased anxiety related to his health as he could resume work. This case shows the effective role of individualized homeopathic medicine in treating LA when prescribed on the basis of homeopathic principles.

## CONCLUSION

Successful treatment with homeopathy is attributed to the fact that the treatment is individualized to each patient; remedies are given to treat the individual as a whole and not to his

sick parts alone. The notable reduction of pus in LA with the improvement of subjective symptoms is a documentary evidence. This shows the strength of the Nature's law of cure with single, simple medicine and signifies the importance of individualization in homeopathic prescription. However, this is a single case study and LA can be associated with variable presentations in different cases. Well-designed studies maybe undertaken for scientific validation of these results.

## DECLARATION OF PATIENT CONSENT

The authors certify that they had obtained all appropriate consent from the patient for his investigation reports and other clinical information to be reported in the journal. The patient was made to understand that his name and initials will not be published, and due efforts will be made to conceal his identity, but anonymity cannot be guaranteed.

## REFERENCES

1. Mischnik A, Kern WV, Thimme R. Pyogenic liver abscess: Changes of organisms and consequences for diagnosis and therapy. *Dtsch Med Wochenschr* 2017;142:1067-74.
2. Varanasi R, Nayak D. Homeopathy in the management of infectious diseases: Different facets of its use and implications for the future. *Indian J Res Homoeopathy* 2020;14:110-21.
3. Hau T, Hartmann E. Pathology, diagnosis and therapy of liver abscess. *Zentralbl Chir* 1987;112:529-47.
4. Czerwonko ME, Huespe P, Bertone S, Pellegrini P, Mazza O, Pekolj J, *et al.* Pyogenic liver abscess: Current status and predictive factors for recurrence and mortality of first episodes HPB (Oxford) 2016;18:1023-30.
5. Offline Radar Homeopathic Software 10.5.003, Development Platforms: Windows Synthesis 8.1. Ver 8.1; 2010.
6. Lodhi S, Sarwari AR, Muzammil M, Salam A, Smego RA. Features distinguishing amoebic from pyogenic liver abscess: A review of 577 adult cases. *Trop Med Int Health* 2004;9:718-23.
7. Lamba CD, Gupta VK, van Haselen R, Rutten L, Mahajan N, Molla AM, *et al.* Evaluation of the modified naranjo criteria for assessing causal attribution of clinical outcome to homeopathic intervention as presented in case reports. *Homeopathy* 2020;109:191-7.
8. Clarke JH. *A Dictionary of Practical Materia Medica*. Vol. 1. London: The Homeopathic Publishing Company; 1900. p. 311-9.
9. Allen HC. *Keynotes and Characteristics with Comparisons of Some of the Leading Remedies of the Materia Medica*. 10<sup>th</sup> ed. New Delhi: B Jain Publishers Pvt. Ltd.; 2006. p. 67.

## Homéopathie individualisée dans un cas d'abcès du foie: Rapport de cas

**RÉSUMÉ Introduction:** Les abcès hépatiques sont des collections purulentes dans le parenchyme hépatique qui résultent d'une infection bactérienne, fongique ou parasitaire qui peut s'étendre au foie par extension d'une infection adjacente, ou à la suite d'un traumatisme. L'approche homéopathique, qui consiste à traiter la maladie en fonction de l'ensemble des symptômes, est une alternative pertinente à la médecine conventionnelle, souvent insatisfaisante, dans les cas de LA. **Résumé du cas:** Un homme de 35 ans qui présentait un abcès du foie a été traité avec un médicament homéopathique basé sur la totalité des symptômes et une amélioration significative a été constatée avec la résolution de l'abcès du foie, ainsi qu'un soulagement des autres symptômes. Cela renforce notre conviction du potentiel de l'homéopathie individualisée dans le traitement des maladies infectieuses.

## Individualisierte Homöopathie in einem Fall von Leberabszess: Ein Fallbericht

**ABSTRAKT Einführung:** Leberabszesse sind eitrige Ansammlungen im Leberparenchym, die durch eine bakterielle, pilzartige oder parasitäre Infektion entstehen, die sich durch die Ausbreitung einer benachbarten Infektion oder als Folge eines Traumas auf die Leber ausbreiten kann. Der homöopathische Ansatz, die Krankheit auf der Grundlage der Gesamtheit der Symptome zu behandeln, ist eine sinnvolle Alternative zur oft unbefriedigenden konventionellen Medizin in Fällen von LA. **Zusammenfassung der Fälle:** Ein 35-jähriger Mann, der sich mit einem Leberabszess vorstellte, wurde mit homöopathischen Arzneimitteln behandelt, die auf der Gesamtheit der Symptome basierten, und es kam zu einer signifikanten Besserung mit Auflösung des Abszesses in der Leber, zusammen mit einer Linderung der anderen Symptome. Dies bestärkt uns in unserem Glauben an das Potenzial der individualisierten Homöopathie bei der Behandlung von Infektionskrankheiten.

## लीवर फोड़ा के एक मामले में व्यक्तिगत होम्योपैथी: एक मामले की रिपोर्ट

**परिचय:** लीवर फोड़े लीवर पैरेन्काइमा में पीप संग्रह हैं जो बैक्टीरिया, कवक, या परजीवी संक्रमण के परिणामस्वरूप होते हैं जो आसन्न संक्रमण के विस्तार से या आघात के परिणामस्वरूप लीवर में फैल सकते हैं। लक्षण समग्रता के आधार पर बीमारी के इलाज का होम्योपैथिक दृष्टिकोण एलए के मामलों में अक्सर असंतोषजनक पारंपरिक चिकित्सा के लिए एक प्रासंगिक विकल्प है। **केस सारांश:** लीवर के फोड़े के साथ प्रस्तुत एक 35 वर्षीय पुरुष को लक्षणों की समग्रता के आधार पर होम्योपैथिक दवा के साथ इलाज किया गया था और लीवर में फोड़ा के सुधार के साथ महत्वपूर्ण सुधार देखा गया था, साथ ही अन्य प्रस्तुत लक्षणों में राहत में थी। यह संक्रामक स्थितियों के इलाज में व्यक्तिगत होम्योपैथी की क्षमता में हमारे विश्वास को बढ़ाता है।

## Homeopatía individualizada en un caso de absceso hepático: Reporte de un caso

**ABSTRACTO Introducción:** Los abscesos hepáticos son colecciones purulentas en el parénquima hepático que resultan de una infección bacteriana, micótica o parasitaria que se puede diseminar al hígado por extensión de una infección adyacente, o como resultado de un trauma. El enfoque homeopático del tratamiento de la enfermedad basado en la totalidad de los síntomas es una alternativa relevante a la medicina convencional a menudo insatisfactoria en los casos de LA. **Resumen del caso:** Un varón de 35 años que presentaba absceso hepático fue tratado con medicina homeopática basada en la totalidad de los síntomas y se observó una mejoría significativa con resolución de absceso en el hígado, junto con alivio en otros síntomas que presentaban. Esto realza nuestra creencia en el potencial de la homeopatía individualizada en el tratamiento de condiciones infecciosas.

## 肝脓肿病例中的个体化顺势疗法: 一个案例报告

抽象的简介: 肝脓肿是由细菌、真菌或寄生虫感染引起的肝脏实质内的脓性集合, 可由邻近的感染扩展到肝脏, 或由外伤导致。在洛杉矶的病例中, 以症状为基础治疗疾病的顺势疗法方法是一种相关的替代方法, 而传统医学往往不能令人满意。案例摘要: 一位35岁的男性患有肝脏脓肿, 根据全部症状用同种疗法进行治疗, 随着肝脏脓肿的消退和其他症状的缓解, 病情得到了明显改善。这增强了我们对个体化顺势疗法在治疗感染性疾病方面的潜力的信念。