

# A case report of hyperuricaemia with nephrolithiasis treated with homoeopathy

Pooja Gautam\*

Regional Research Institute for Homoeopathy, Under CCRH, Guwahati, Assam, India

## Abstract

**Introduction:** Hyperuricaemia is serum urate concentration exceeding the limit of solubility, leading to its precipitation and predisposing the affected persons to gout. The increased level of uric acid in urinary excretion can also lead to nephrolithiasis. It has also been implicated as an indicator for diseases such as metabolic syndrome, diabetes mellitus, cardiovascular disease and chronic renal disease. Whereas homoeopathic literature enlists many medicines for this condition, there is a paucity of evidence-based published studies. **Case Summary:** The case presented here reported with the complaint of renal stone secondary to high serum uric acid levels. A single homoeopathic medicine *Lycopodium* was prescribed after thorough case taking which led to improvement in subjective symptoms and objectively reflecting in gradually decreasing levels of serum uric acid after elimination of stone. During the course of treatment, old symptoms also re-appeared depicting improvement in accordance with Hering's law of cure. The Modified Naranjo Criteria score after treatment was 8, which explicitly shows the positive causal attribution of the individualised homoeopathic medicine *Lycopodium* in this case. Homoeopathic treatment has shown favourable results in this case and demonstrates the scope of Homoeopathy in such cases.

**Keywords:** Homoeopathy, Hyperuricaemia, *Lycopodium*, Nephrolithiasis, Uric acid

## INTRODUCTION

The prevalence and disease burden of gout and hyperuricaemia are rising globally. The prevalence of hyperuricaemia in India was 44.6% according to the study published in 2012, which was reduced to 25.8% in 2018.<sup>[1]</sup> In other epidemiological study, the annual incidence of urolithiasis was 0.3% in patients with asymptomatic hyperuricaemia and 0.9% in patients with hyperuricaemia and gout.<sup>[2]</sup>

Gout is a common condition managed with conventional treatment approaches including management of the inflammatory pain associated with flares, urate-lowering therapies and patient education. However, patients can be benefited more if treatment paradigm shifts further towards active management of hyperuricaemia as it has also been implicated as an indicator for diseases such as metabolic syndrome, diabetes mellitus, cardiovascular disease and chronic renal disease.<sup>[3,4]</sup> The goal of treatment is to reduce the body's total uric acid pool and consequently, to reduce the complications.<sup>[5]</sup> At present, available drugs, including allopurinol and febuxostat, may have significant

adverse effects such as hypersensitivity drug reactions, and they are now not indicated for broad use in many hyperuricaemia-related diseases also.<sup>[6]</sup>

Homoeopathic literature enlists many medicines for gout or hyperuricaemia such as *Colchicum*, *Benzoic acid*, *Ledum palustre* and *Lithium benzoicum*. Among the published evidence based studies on gout only four preclinical studies<sup>[7-10]</sup>, five clinical trials<sup>[11-15]</sup> and two case reports<sup>[16-17]</sup> could be found which shows promising results in reduction of serum uric acid.

A case report on hyperuricaemia with nephrolithiasis successfully treated with single homoeopathic medicine *Lycopodium* is presented here. This case highlights

**\*Address for correspondence:** Dr. Pooja Gautam,  
Regional Research Institute for Homoeopathy, Under CCRH, Guwahati,  
Assam, India.  
E-mail: [dr.poojagautam@gmail.com](mailto:dr.poojagautam@gmail.com)

**Received:** 21.01.2021; **Accepted:** 28.05.2021; **Published:** 29.06.2021.

### Access this article online

Quick Response Code:



Website:  
[www.ijrh.org](http://www.ijrh.org)

DOI:  
10.4103/ijrh.ijrh\_6\_20

This is an open access journal, and articles are distributed under the terms of the Creative Commons Attribution-NonCommercial-ShareAlike 4.0 License, which allows others to remix, tweak, and build upon the work non-commercially, as long as appropriate credit is given and the new creations are licensed under the identical terms.

**For reprints contact:** [WKHLRPMedknow\\_reprints@wolterskluwer.com](mailto:WKHLRPMedknow_reprints@wolterskluwer.com)

**How to cite this article:** Gautam P. A case report of hyperuricaemia with nephrolithiasis treated with homoeopathy. Indian J Res Homoeopathy 2021;15:147-54.

the effectiveness of Homoeopathy for the treatment of hyperuricaemia and its associated conditions, following the basic principles of Homoeopathy.

## PATIENT INFORMATION

A 51-year-old, lean, thin man reported in the Outpatient

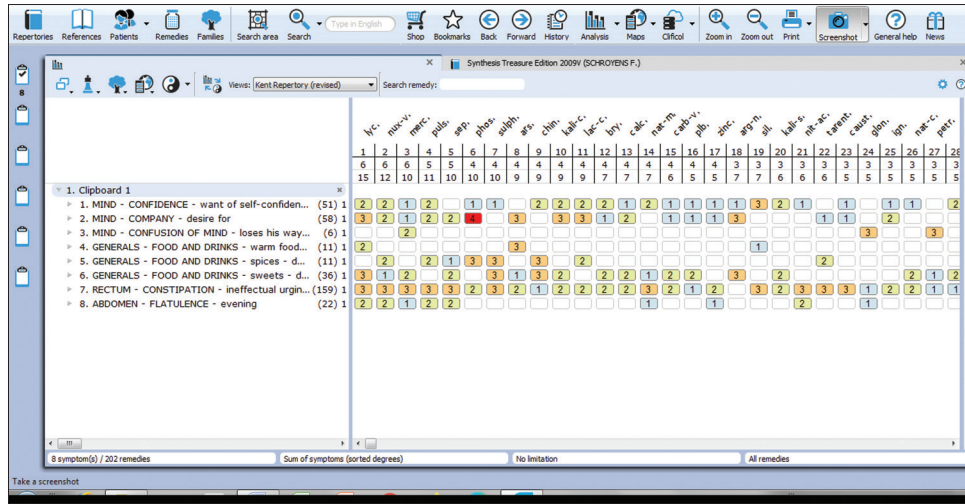


Figure 1: Repertory sheet

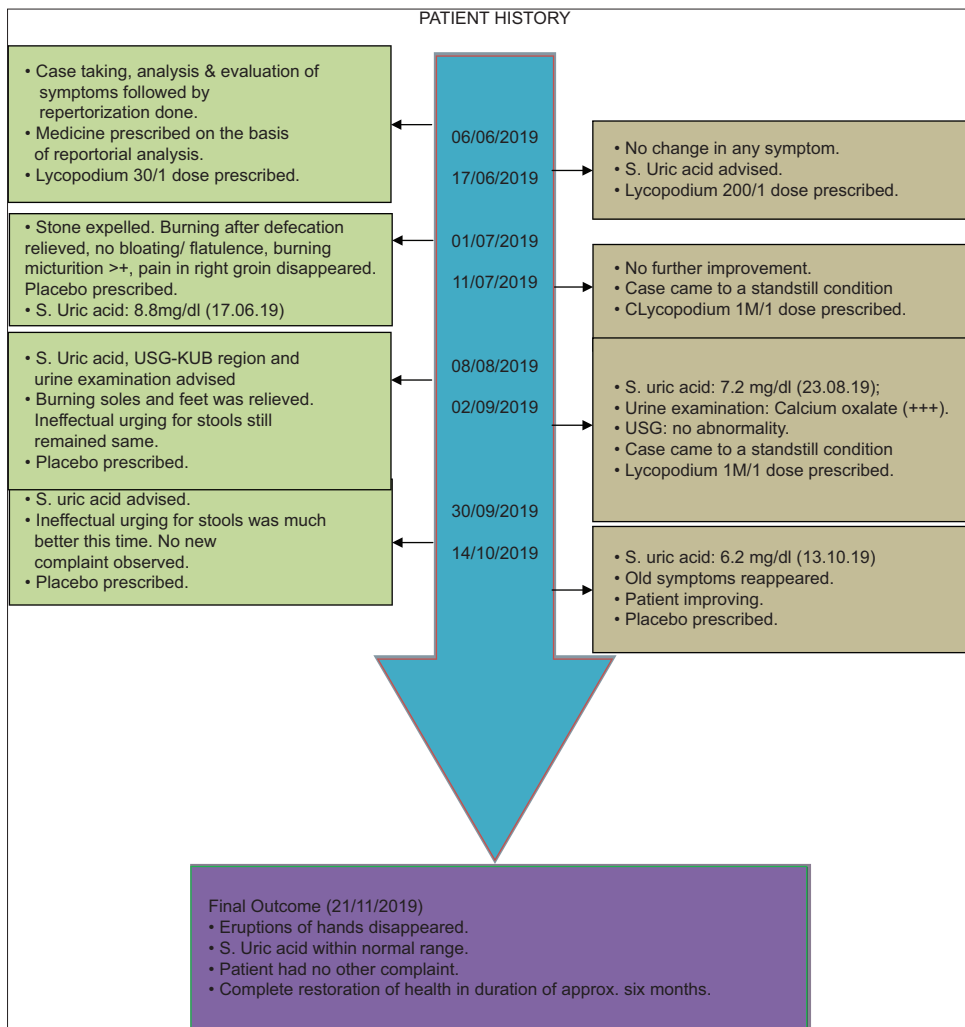


Figure 2: Timeline

Department of Regional Research Institute for Homoeopathy, Agartala on 6 June, 2019, with a complaint of on and off cramping pain in the right groin and burning during micturition in the past 2 weeks with uninterrupted – clear urine flow. The patient was a known case of renal calculi with a history of right-sided renal colic twice in the past 4 months for which he

underwent few investigations on physician’s advice and took conventional treatment also with temporary relief.

The patient did not suffer from any other major illness in the past, except from some gastric disturbances. Family history was not significant.

**Table 1: Follow-up and Outcomes**

Date	Indications for prescription	Medicine with doses and repetition	Justification
June 17, 2019	Patient reported again with no change in any of his symptoms Serum uric acid advised	<i>Lycopodium</i> 200/1 dose	As there was no change, the same medicine was prescribed in higher potency
July 1, 2019	Patient gave a history of passing few stone 4-5 days after the last visit. Burning after defecation was relieved. There was no bloating or flatulence since the last visit. Burning micturition was better and pain in the right groin disappeared Serum uric acid: 8.8 mg/dl (June 17, 2019)	Placebo	Patient was improving hence no medicine was prescribed
July 11, 2019	Patient came with a complaint of burning of soles and feet since few days. Burning micturition was completely relieved but ineffectual urging for stools remained same	<i>Lycopodium</i> 1M/1 dose; placebo	In view of no further improvement, potency of the medicine was raised
August 8, 2019	Burning of soles and feet was relieved. Ineffectual urging for stools still remained same Serum uric acid, USG-KUB region and urine examination advised	Placebo	Patient was improving hence no medicine was prescribed
September 2, 2019	Ineffectual urging for stools same Serum uric acid: 7.2 mg/dl (August 23, 2019) Urine examination: Calcium oxalate (+++) USG: No abnormality	<i>Lycopodium</i> 1M/1 dose; placebo	Case came to a standstill condition hence one more dose of the same medicine was prescribed
September 30, 2019	Ineffectual urging for stools was much better this time. No new complaint observed Serum uric acid advised	Placebo	Patient was improving hence placebo was prescribed again
October 14, 2019	Frequency of unsatisfactory stools reduced markedly Serum uric acid: 6.2 mg/dl (October 13, 2019) Dry itching eruptions appeared on back of hands for 8-10 days. On enquiring, he disclosed he had similar eruptions 5 years back also	Placebo	Old symptoms were reappearing which is a good sign, hence no medicine was prescribed
November 21, 2019	Eruptions of hands disappeared after 10-15 days of the last visit. He had no other complaint	Placebo	Complete restoration of health in the duration of approximately 6 months

+++; abundant USG-KUB: Ultrasound-kidneys, ureters and bladder

**Table 2: Assessment by Modified Naranjo criteria score**

Item	Yes	No	Not sure/N/A
Was there an improvement in the main symptom or condition for which the homoeopathic medicine was prescribed?	+2		
Did the clinical improvement occur within a plausible time frame relative to the drug intake?	+1		
Was there an initial aggravation of symptom?		0	
Did the effect encompass more than the main symptom or condition, that is, were other symptoms ultimately improved or changed?	+1		
Did overall well-being improve?	+1		
Direction of cure: Did some symptoms improve in the opposite order of the development of symptoms of the disease?	+1		
Direction of cure: Did at least two of the following aspects apply to the order of improvement of symptoms	+1		
From organs of more importance to those of less importance			
From deeper to more superficial aspects of the individual			
From the top downwards			
Did old symptoms (defined as non-seasonal and non-cyclical that were previously thought to have resolved) reappear temporarily during the course of improvement?	+1		
Are there alternate causes (other than the medicine) that with a high probability - could have caused the improvement? (consider known course of disease, other forms of treatment and other clinically relevant intervention)	-3		
Was the health improvement confirmed by any objective evidence? (e.g., laboratory test, clinical observation, etc.)	+2		
Did repeat dosing, if conducted, create similar clinical improvement?	+1		
Total	8		

N/A: Not available

The patient was a Government employee belonging to a middle-class socioeconomic group.

He consumed alcohol occasionally.

### Mental generals

The patient was very well behaved. During childhood, he was average in studies, and although he had limited friends, he interacted with everyone. He felt anxious before starting new work but performed well once he started. He had cordial relations with all his work colleagues. He disliked being alone at home, though he did not interact with his children much. He was forgetful, forgot things after keeping them and had marked habit of forgetting his usual road directions. Very often, he used to forget the way back home while returning from school. His mother had to accompany him for this reason. This was also seen during the college life and continued infrequently. He was married for 24 years and had three children. His relations with wife were good, except sometimes when he was tensed.

### Physical generals

The patient had a thermal reaction towards hot, wore minimal woollens during winter and bathed with cold water throughout the winters. His appetite was good and he always preferred warm food. He had the desire for sweet and spicy things with moderate thirst. There was constipation in the past 4–5 years with ineffectual urging for stools, had to go 3–4 times a day. It was often accompanied by burning pain during and after defecation for last few days, which remained for 10–15 min. He was prone to have gastric disturbances with bloating of the abdomen 2–3 times/week, mostly towards evening in the past 2–3 years. He passed urine 4–5 times a day with burning during micturition for 2 weeks. He perspired moderately. Sleep was usually adequate, refreshing with non-specific sleep posture and dreams.

### Clinical findings

Blood pressure was normal. Nothing abnormal was detected except for a mild deep tenderness in the right groin area. Pulse rate was 74/min; he was afebrile and weighed 64 Kg.

### Diagnostic assessment

The patient was already a diagnosed case of hyperuricaemia, and serum uric acid was tested again to know about the present status. His investigations revealed following significant findings:

- Serum uric acid was 8.0 mg% (21 May 2019).
- Urine examination revealed 8–10 red blood cell's/ high power field (HPF) and trace proteins (25 April 2019).
- Ultrasonography – kidney, ureter and bladder was suggestive of right renal tiny echogenic foci (0.28 cm) near lower pole probably renal calculus (1 February, 2019).

On further enquiry, the patient reported of having occasional pain in small joints of feet although there was no history of an acute gout episode.

### Therapeutic intervention

Detailed case taking was done as per Hahnemannian guidelines of case taking given in *Organon of Medicine* followed by analysis and evaluation of the symptoms.<sup>[18]</sup> Totality of symptoms was erected, and repertorisation was done taking into account only the most striking mental generals, physical generals and uncommon particulars using Kent's repertory in RADAR 10.5. Repertorisation result is shown in Figure 1. Following symptoms were considered for repertorisation:

1. Feels anxious before starting new work
2. Dislikes being alone
3. Habit of forgetting the streets
4. Prefers warm food
5. Desire for sweets
6. Desire for spicy things
7. Constipated with ineffectual urging for stools
8. Flatulence in evening.

After repertorisation, the top medicines were *Lycopodium*, *Nux vom*, *Merc.Sol*, *Pulsatilla* and *Sepia*. After carefully analysing the mental and physical generals of patient, considering the repertorial result, and referring back to homoeopathic materia medica similimum was prescribed. The patient was hot and *Lycopodium* has uric acid diathesis which further confirmed the selection of medicine. Individualised homoeopathic treatment was started with single dose of *Lycopodium* 30 followed by placebo following the law of minimum dose. Medicine was not repeated as long as the improvement in symptoms of the patient continued. During follow-up, changes in the signs and symptoms were assessed and serum uric acid was advised from time to time. Case was psoro-sycotic in nature pertaining to the nature of disease condition i.e., accumulation within the body. The patient was instructed to take plenty of water and limit the intake of all non-vegetarian and purine-rich food, although the patient informed that he took non-vegetarian foods only occasionally.

First prescription (06 June, 2019): *Lycopodium* 30/1 dose was prescribed on the basis of repertorial analysis.

### Follow-up and outcomes

Follow-up of the patient was assessed regularly as required. Date-wise detailed follow-ups with result in investigations are summarised in Table 1. Figure 2 gives the timeline of the case.

In this case, the total score of outcome as per Modified Naranjo Criteria score after treatment was 8, which is close to the



Figure 3: Expelled calculi

total score of 13, and explicitly shows the positive causal attribution of the individualised homoeopathic medicine *Lycopodium* [Table 2].

Improvement in the patient started immediately after medicine in appropriate potency was given to patient. Improvement was subjective in terms of relief in overall sign and symptoms such as burning during defecation disappeared completely, marked reduction in bloating and flatulence, as well as objective as evident by expulsion of calculi [Figure 3] within few days followed by gradual decline of serum uric acid levels from 8.8 mg% to 6.2 mg%.

No adverse events were reported during the whole duration of treatment.

## DISCUSSION

Homoeopathy is a system of medicine which embraces a holistic approach in the treatment of sick. In Homoeopathy, detailed case taking is done to elucidate the constitutional makeup of the patient and a single remedy is selected on the basis of totality of symptoms.

At the first instance, the present case appeared to be a simple case of renal calculus. However, upon carefully exploring the history, hyperuricaemia was revealed as the cause behind stone formation i.e., alteration of purine metabolism. After considering the totality of symptoms, homoeopathic medicine *Lycopodium* was selected as similimum. When prescribed in appropriate dose, it resulted in healing in the reverse order of appearance of symptoms. A single remedy took care of both, the manifestation (renal calculi) and causation (hyperuricaemia) by re-establishing the homoeostasis in purine metabolism which was manifested in gradually decreasing serum uric acid levels after expulsion of stone and thus preventing reformation of stone and probably other comorbidities also. Improvement in other unassociated symptoms was also observed during the course of treatment. Homoeopathy treatment is very commonly sought when patients see no hope in conventional system of medicine, which is generally towards the terminal stages of incurable diseases. This case report as an evidence in preclinical condition highlights the use of Homoeopathy right from the beginning of disease.

Here, our case differs from another case report where antisycotic drug was prescribed in the beginning of case to get the clearer picture because the case was one sided. It was followed by change of medicine on basis of repertorisation with intercurrent and acute prescription when needed.<sup>[16]</sup> While, in our case, totality of symptoms was very clear right from the beginning, and as continuous improvement was observed, change of medicine was not required, and a single remedy completed the cure which was similar to another case report.<sup>[16]</sup> This is due to different presentations of the cases.

Clinical outcomes are very frequently assessed by homoeopathic physicians using Hering's law of cure. It suggests that following a homoeopathic constitutional remedy, healing occurs from the head down, inside out, most important to the least important

organs and reverse order of symptoms in which they first appeared. But unfortunately, not much scientific reporting could be found depicting this law in clinical trials, except for a study on 35 patients of rheumatoid arthritis where 'healing from centre to periphery' was the most commonly reported response and 'reversal of order of symptoms' was reported least.<sup>[19]</sup> The present case is a classical case supporting this law and the same thing is reflected in miasmatic plane also where disappearance of sycotic manifestations was followed by appearance of psoric symptoms.

In the present case, possibility of spontaneous expulsion of stone due to its small size and decline in serum urate levels due to dietary modifications (less intake of purine rich food) could not be ruled out. Other limitation is inability to keep a check on persisting normal serum urate levels through long-term follow-up of case. Although homoeopathic treatment has shown favourable results in this case and undoubtedly thrown some light on scope of Homoeopathy and possible answer in this unexplored area, controlled studies with long-term follow-up and large sample size are required for validation of the effects of the homoeopathic treatment in such cases.

The outcome of interest, in this case, was reduction in serum urate levels and prevention of possible associated complications, which was successfully achieved while adhering to the basic fundamental principles of Homoeopathy.

## Acknowledgement

The author is grateful to Dr. Anil Khurana, Director General, CCRH, for his constant motivation and guidance in writing evidence based scientific articles. The patient is also acknowledged for his compliance in continued follow-ups.

## Declaration of patient consent

The author certifies that she has obtained appropriate patient's consent. In the consent, the patient has given his consent for reporting his clinical information in the journal. The patient understands that his name and initials will not be published and due efforts will be made to conceal his identity, but anonymity cannot be guaranteed.

## Financial support and sponsorship

Nil.

## Conflicts of interest

None declared.

## REFERENCES

1. Raja S, Kumar A, Aahooja RD, Thakuria U, Ochani S, Shaikat F. Frequency of Hyperuricemia and its Risk Factors in the Adult Population. *Cureus*. 2019;11:e4198. doi:10.7759/cureus.4198.
2. Dincer HE, Dincer AP, Levinson DJ. Asymptomatic hyperuricemia: To treat or not to treat. *Cleveland Clinic Journal of Medicine* 2002;69:594-608.
3. Benn CL, Dua P, Gurrell R, Loudon P, Pike A, Storer RI, *et al*. Physiology of hyperuricemia and urate-lowering treatments. *Front Med (Lausanne)* 2018;5:160.
4. George C, Minter DA. Hyperuricemia. In: StatPearls. Treasure Island (FL): StatPearls Publishing; 2019. Available from: <https://www.ncbi.nlm.nih.gov/books/NBK459218/>. [Last accessed on 2019 Jun 04].
5. Li Q, Li X, Wang J, Liu H, Kwong JS, Chen H, *et al*. Diagnosis and treatment for hyperuricemia and gout: A systematic review of clinical

- practice guidelines and consensus statements. *BMJ Open* 2019;9:e026677.
6. Chen C, Lü JM, Yao Q. Hyperuricemia-related diseases and Xanthine Oxidoreductase (XOR) inhibitors: An overview. *Med Sci Monit* 2016;22:2501-12.
  7. Shaikat A, Hussain K, Bukhari NI, Shehzadi N. Acid Uric 3×Tablet: Standardization and pharmacological evidence of uric acid use as anti-gout medicine. *J Pharm Pharmacogn Res* 2020;8:501-14.
  8. Yashwanth BM, Rai SS, Gowda KP. Effect of bryonia alba homeopathic formulation in mono sodium urate induced gouty arthritis and potassium oxonate induced hyperuricemia in experimental animals. *World J Pharm Pharm Sci* 2014;4:1120-34.
  9. Shaffique S, Ahmed S, Rehman T, Mumtaz W, Anwar H, Hussain G. Anti-hyperuricemic potential of *Rhododendron tomentosum Harmaja syn. Ledum palustre L.* 30c and 1M in potassium oxonate induced rat model. *Indian J Tradit Knowl* 2018;17:724-311.
  10. Smulders H. The homoeopathic simillimum treatment of acute arthritis in primary gout in terms of the illness intrusiveness scale, blood uric acid levels using the uricase conversion method as well as the acupulse homeostat machine. 2001. Available from: <https://openscholar.dut.ac.za> [Last accessed on 2019 Jun 04].
  11. Saha S, Sarkar P, Chattopadhyay R, Saha S. An open-label prospective observational trial for assessing the effect of homoeopathic medicines in patients suffering from gout. *Indian J Res Homoeopathy*. 2019;13:236-43.
  12. Nayak C, Pattanaik N, Chattopadhyay A, Misra P, Bhar K, Michael J. *et al.* Individualized homeopathic medicines and *Urtica urens* mother tincture in treatment of hyperuricemia: an open, randomized, pragmatic, pilot trial, *Journal of Complementary and Integrative Medicine* (published online ahead of print 2020. 20200129. doi: <https://doi.org/10.1515/jcim-2020-0129>).
  13. A Deep, A Kumar. Homoeopathic management of hyperuricemia in primary gout: Arandomized single blind placebo controlled study. *International Journal of Homoeopathic Sciences* 2020;4: 73-77.
  14. Cara R, Tikky M, Solomon EM, Deroukakis M. Homeopathic Treatment of Acute Gout. *Am J Homeopathic Med* 2007;100:40-9.
  15. Henriette Smulders. The homoeopathic simillimum treatment of acute arthritis in primary gout in terms of the illness intrusiveness scale, blood uric acid levels using the uricase conversion method as well as the acupulse homeostat machine. - [openscholar.dut.ac.za](https://openscholar.dut.ac.za). 2001
  16. Bala R, Shrivastava A. case report on hyperuricemia presenting as one-sided disease. *Homoeopathic Links*. 2019;32:105-111.
  17. Rajan SS, Shibina K. A case of gout treated with Homoeopathic constitutional remedy. *International Journal of Homoeopathic Sciences* 2020;4:365-8.
  18. Hahnemann S. *Organon of Medicine*. 5<sup>th</sup> ed. New Delhi: B. Jain Publishers; 2002.
  19. Harrison H. The development and use of Hering's Law Assessment Tool (HELAT) in clinical trials. *HRI Res Artic* 2012;18:1-3.

### होम्योपैथी से उपचारित हाइपरुरीसेमिया के साथ-साथ नेफ्रोलिथियासिस पर मामला प्रतिवेदन

**प्रस्तावना:** हाइपरुरीसेमिया, सीरम यूरेह सांद्रता है जो घुलनशीलता की सीमा से अधिक है, जो उसके अवक्षेपण का कारण बनता है तथा पीड़ित लोगों को गठिया के लिए प्रवृत्त करता है। पेशाब उत्सर्जन में यूरिक एसिड के बढ़े हुए स्तर भी नेफ्रोलिथियासिस का कारण बन सकते हैं। इसे चयापचयी लक्षण, मधुमेह मेलिटस, हृदवाहिनी बीमारी, तथा चिरकारी गुर्दे की बीमारियों के संकेतक के तौर पर भी सुझाया गया है। चूंकि होम्योपैथिक साहित्य इस स्थिति के लिए कई दवाईयों की सूची बनाता है, साक्ष्य आधारित प्रकाशित अध्ययनों का अभाव है। **मामले का सारांश:** यहाँ प्रस्तुत किया गया मामला उच्च सीरम यूरिक एसिड स्तरों के अतिरिक्त गुर्दे की पथरी की समस्या से प्रतिवेदित है। मामले के गहन अध्ययन पश्चात् एकल होम्योपैथिक दवा लाइकोपोडियम नियत की गई थी जिसके कारणवश व्यक्तिपरक लक्षणों में सुधार हुआ तथा पथरी को निकालने के बाद सीरम यूरिक एसिड के धीरे-धीरे कम होते हुए स्तरों को निष्पक्षता से दर्शाया गया। उपचार की अवधि के दौरान, पुराने लक्षण भी दोबारा उभरे जो हेरिंग्स के उपचार नियम के अनुरूप सुधार का वर्णन करते हैं। उपचार के पश्चात् संशोधित नरांजो मानदंड प्राप्तांक 8 था, जो इस मामले में व्यक्तिपरक होम्योपैथिक दवा लाइकोपोडियम के सकारात्मक हेतुक संबंध को स्पष्टतया दर्शाता है। होम्योपैथिक उपचार ने इस मामले में अनुकूल परिणाम दर्शाये हैं तथा ऐसे मामलों में होम्योपैथी की संभावनाओं को प्रदर्शित किया है।

### UN CAS À RAPPORT D'HYPERURICEMIE AVEC NEPHROLITHIASE TRAITÉE PAR HOMÉOPATHIE

**Introduction:** L'hyperuricémie est une concentration sérique d'urate dépassant la limite de solubilité, conduisant à sa précipitation et prédisposant les personnes atteintes à la goutte. L'augmentation du taux d'acide urique dans l'excrétion urinaire peut également entraîner une néphrolithiase. Il a également été impliqué comme indicateur de maladies telles que le syndrome métabolique, le diabète sucré, les maladies cardiovasculaires et les maladies rénales chroniques. Alors que la littérature homéopathique enrôle de nombreux médicaments pour cette condition, il y a peu d'études publiées basées sur des preuves. **Résumé du cas:** Le cas présenté ici a été signalé avec la plainte de calculs rénaux secondaires à des taux élevés d'acide urique sérique. Un seul médicament homéopathique Lycopodium a été prescrit après une prise de cas approfondie qui a conduit à une amélioration des symptômes subjectifs et se traduisant objectivement par une diminution progressive des taux d'acide urique sérique après élimination des calculs. Au cours du traitement, d'anciens symptômes sont également réapparus, représentant une amélioration conformément à la loi de guérison de Hering. Le score des Critères de Naranjo modifiés après traitement était de 8, ce qui montre explicitement l'attribution causale positive du médicament homéopathique individualisé Lycopodium dans ce cas. Le traitement homéopathique a montré des résultats favorables dans ce cas et démontre la portée de l'homéopathie dans de tels cas.

### UN INFORME DEL CASO SOBRE HYPERURICEMIA CON NEPHROLITHIASIS TRATÓ CON HOMEOPATÍA

**Introducción:** La hiperuricemia es la concentración de urato sérico que excede el límite de solubilidad, lo que lleva a su precipitación y predispone a las personas afectadas a la gota. El aumento del nivel de ácido úrico en la excreción urinaria también puede conducir a la nefrolitiasis. También se ha implicado como indicador de enfermedades como el síndrome metabólico, la diabetes mellitus, las enfermedades cardiovasculares y las enfermedades renales crónicas. Mientras que la literatura homeopática incluye muchos medicamentos para esta afección, hay escasez de estudios publicados basados en la evidencia. **Resumen del caso:** El caso presentado aquí reportó la queja de cálculos renales secundarios a niveles altos de ácido úrico en suero. Un solo medicamento homeopático Lycopodium fue prescrito después de tomar un caso completo que condujo a la mejora en los síntomas subjetivos y objetivamente refleja en los niveles gradualmente decrecientes de ácido úrico sérico después de la eliminación de la piedra. Durante el curso del tratamiento, los viejos síntomas también reaparecieron representando una mejoría de acuerdo con la ley de curación de Hering. La puntuación de los criterios de Naranjo modificado después del tratamiento fue de 8, lo que muestra explícitamente la atribución causal positiva del medicamento homeopático individualizado Lycopodium en este caso. El tratamiento homeopático ha mostrado resultados favorables en este caso y demuestra el alcance de la Homeopatía en tales casos.

## Ein Fallbericht über Hyperurikämie mit Nephrolithiasis, behandelt mit Homöopathie EIN FALLBERICHT ÜBER HYPERURIKÄMIE MIT NEPHROLITHIASIS MIT HOMÖOPATHIE BEHANDELT

**Einleitung Einführung:** Hyperurikämie ist eine Serumuratkonzentration, die die Grenze der Löslichkeit überschreitet, was zu ihrer Ausfällung führt und die Betroffenen zu Gicht veranlasst. Der erhöhte Harnsäurespiegel in der Harnausscheidung kann auch zu Nephrolithiasis führen. Es wurde auch als Indikator für Krankheiten wie metabolisches Syndrom, Diabetes mellitus, Herz-Kreislauf-Erkrankungen und chronische Nierenerkrankungen eingesetzt. Während die homöopathische Literatur viele Medikamente für diesen Zustand anwendet, gibt es wenig evidenzbasierte veröffentlichte Studien. **Fallzusammenfassung:** Der hier vorgestellte Fall berichtete über die Beschwerde von Nierenstein aufgrund hoher Serumharnsäurespiegel. Ein einziges homöopathisches Arzneimittel Lycopodium wurde nach gründlicher Einzelfallaufnahme verschrieben, was zu einer Verbesserung der subjektiven Symptome führte und objektiv zu einer allmählichen Abnahme der Serumurinsäurespiegel nach Beseitigung des Steins führte. Im Verlauf der Behandlung traten auch alte Symptome wieder auf, die eine Verbesserung gemäß Herings Heilgesetz darstellten. Der modifizierte Naranjo-Kriterienwert nach der Behandlung betrug 8, was die positive kausale Zuordnung des individualisierten homöopathischen Arzneimittels Lycopodium in diesem Fall eindeutig explizit zeigt. Die homöopathische Behandlung hat in diesem Fall günstige Ergebnisse gezeigt und zeigt den Umfang der Homöopathie in solchen Fällen.

### 高尿酸血症并肾结石并顺势疗法1例

**简介:** 高尿酸血症是血清尿酸盐浓度超过溶解度极限, 导致其沉淀并易患痛风。尿排泄中尿酸水平的增加也可导致肾结石。它也被认为是代谢综合征, 糖尿病, 心血管疾病和慢性肾病等疾病的指标。虽然顺势疗法文献为这种情况提供了许多药物, 但缺乏基于证据的已发表研究。 **病例摘要:** 这里介绍的病例报告了继发于高血清尿酸水平的肾结石的投诉。单药顺势疗法石松在彻底的病例服用后, 导致主观症状的改善, 客观上反映了消除结石后血清尿酸水平的逐渐下降。在治疗过程中, 旧症状也重新出现, 并根据赫林的治愈规律得到改善。治疗后修改的纳兰乔标准评分为8, 这明确显示了在这种情况下个体化顺势疗法药物石松的阳性因果归因。顺势疗法在这种情况下已经显示出有利的结果, 并证明了顺势疗法在这种情况下下的范围。