

Understanding the role of homoeopathic preparation of *Berberis vulgaris* in mitigation of sodium oxalate- induced hyperoxaluria: An experimental approach

Bhavani Tamilarasan¹, Porkodi Karthikeyan¹, Pugazhendhi Kannan¹, Kalaiselvi Periandavan^{1*}, Raj K. Manchanda², Anil Khurana², Debadatta Nayak², Shanthi Palainivelu³

Department of ¹Medical Biochemistry and ³Pathology, Dr ALM Post Graduate Institute for Basic Medical Sciences, University of Madras, Chennai, Tamil Nadu, ²Central Council for Research in Homoeopathy, New Delhi, India

Abstract

Background: Hyperoxaluria and calcium oxalate crystal deposition in the kidneys lead to overproduction of reactive oxygen species, resulting in the development of oxidative stress and renal injury. At the cellular levels, mitochondria and NADPH oxidase involved in reactive oxygen species production play a crucial role in the pathogenesis of hyperoxaluria-induced renal injury. **Objective:** The objective was to investigate the therapeutic effect of homoeopathic drug *Berberis vulgaris*, a potent antioxidant, upon regulation of NADPH oxidase against acute high-grade sodium oxalate-induced hyperoxaluria in rats. **Materials and Methods:** Hyperoxaluria was induced in male Wistar rats by administering a single dose of sodium oxalate (70 mg/kg body weight) intraperitoneally, and the treatment groups were pre-treated with homoeopathic drug *Berberis vulgaris* 6c (20 µl/100 g of body weight) ultra low dose for 7 days. **Results:** *Berberis vulgaris* significantly reduces hyperoxaluria-induced oxidative stress and restores antioxidant enzyme activities in kidney tissue. Histological analysis depicted that *Berberis vulgaris* treatment decreases renal epithelial damage and inflammation and restored normal glomerular morphology. Furthermore, immunoblotting analyses of NADPH oxidase revealed significant increased activity in the renal tissue of hyperoxaluric rats when compared to that of control rats. This has been brought back to normal by *Berberis vulgaris* treatment. **Conclusion:** Thus, our results emphasised that the Homoeopathy drug *Berberis vulgaris* has been effective in ameliorating sodium oxalate-induced acute hyperoxaluria in Wistar rats by modulating mitochondrial oxidative stress through the inhibition of NADPH oxidase.

Keywords: Acute hyperoxaluria, *Berberis vulgaris*, Homoeopathy, NADPH oxidase, Oxidative stress, Reactive oxygen species

INTRODUCTION

Hyperoxaluria is a major risk factor, and calcium oxalate (CaOx) is the chief constituent of most idiopathic urinary stones. Earlier studies reported that CaOx crystals and high oxalate (Ox) concentration are injurious to renal epithelial cells, which leads to the overproduction of reactive oxygen species (ROS) and the augmentation of oxidative stress in the kidneys.^[1] In addition, Khan^[1] and Thamilselvan *et al.*^[2] elucidate that NADPH oxidase (NOX), involved in the production of ROS, is well known to play an imperative role in the pathogenesis of hyperoxaluria-induced nephrolithiasis on regulation of NADPH oxidase activation and its associated cell injury; it may be ameliorated by antioxidants and free radical scavengers. Based on the above deliberation, attention was currently

focused on a novel approach of targeting the provocative sources of ROS (mitochondria and NADPH oxidase) to prevent accelerated oxidant production in hyperoxaluria, thereby eliminating pathological sources of ROS, further helping to comprehend the intricate procedure of stone formation.

***Address for correspondence:** Dr. Kalaiselvi Periandavan,
Department of Medical Biochemistry, Dr ALM Post Graduate Institute for
Basic Medical Sciences, University of Madras, Chennai, Tamil Nadu, India.
E-mail: pkalaiselvi2011@gmail.com

Received: 13.05.2020; **Accepted:** 14.10.2020; **Published:** 29.12.2020

This is an open access journal, and articles are distributed under the terms of the Creative Commons Attribution-NonCommercial-ShareAlike 4.0 License, which allows others to remix, tweak, and build upon the work non-commercially, as long as appropriate credit is given and the new creations are licensed under the identical terms.

For reprints contact: WKHLRPMedknow_reprints@wolterskluwer.com

How to cite this article: Tamilarasan B, Karthikeyan P, Kannan P, Periandavan K, Manchanda RK, Khurana A, *et al.* Understanding the role of homoeopathic preparation of *Berberis vulgaris* in mitigation of sodium oxalate- induced hyperoxaluria: An experimental approach. *Indian J Res Homoeopathy* 2020;14:251-9.

Access this article online

Quick Response Code:



Website:
www.ijrh.org

DOI:
10.4103/ijrh.ijrh_44_20

Tamilarasan, *et al.*: Plausible role of a potentised Homoeopathy drug, *Berberis vulgaris*, in ameliorating sodium oxalate-induced acute hyperoxaluria in Wistar rats

Since ancient times, herbal drugs which are the part of traditional medicine have been utilised as the major source for the treatment and prevention of diseases and health promotion, as well as for the enhancement of life span and quality of life.^[3] In the folklore of medicine, *Berberis vulgaris* L holds a prominent place in treating urinary stone disease for more than 2500 years.^[4] *Berberis vulgaris* plant is extensively distributed in Europe and Asia; its root, bark, leaf and fruit exhibit medicinal properties such as antioxidant, anti-inflammatory, antimicrobial, antipyretic, antiurolithic, anticonvulsant and antiarrhythmic activities.^[5] Our earlier study reported that Homoeopathy drug *Berberis vulgaris* proved to be a potent antioxidant and highlighted its effectiveness as a nephroprotective, in reducing oxalate deposition in tissues and protecting renal cell membrane integrity, thereby reducing the risk of stone formation.^[6]

As crystallisation is an ongoing process associated with continued oxidative damage, its further consequence leads to renal epithelial injury, partially caused by ROS production, and the involvement of NOX might provide sites for crystal attachment and eventual retention within the kidney.^[7,8] At the cellular levels, NADPH oxidase and mitochondria are found to be the major sources of ROS present in the renal tissues as it has been found that these NADPH oxidase complexes play a crucial role in host defence and various signalling pathways leading to regulation of gene expression, and protein functions are disturbed under physiological conditions of oxidative balance.^[8] Hence, our main emphasis focused primarily on oxidative stress caused by ROS produced by NADPH oxidase and their effects on interactions to be targeted in order to reduce the function and downstream effects of NADPH oxidase.^[9]

Comprehensive studies recommend pre-treatment with antioxidants along with NADPH oxidase inhibitor, which significantly decreases renal CaOx crystal deposition, which is a surrogate marker of nephrolithiasis in animal models. Thus, the present findings were hypothesised to develop an inhibitor with increased efficiency and specificity with a combinatorial therapy based on the attenuation of oxidative stress with antioxidant, free radical scavenger and NADPH oxidase inhibition, which may completely ameliorate hyperoxaluric manifestations in acute sodium oxalate-induced rats.

MATERIALS AND METHODS

Drugs and chemicals

Homoeopathic preparation of *Berberis vulgaris* (6c, batch no: 2194) was procured from Hahnemann Publishing Co. Pvt. Ltd., Kolkata, West Bengal, India. The potentised homoeopathic drug, *Berberis vulgaris* 6c, used in the current study was suggested by the Central Council for Research in Homoeopathy (CCRH), which was used as the stock solution. All other chemicals and solvents used in the present study were procured from standard agencies and of analytical grade.

Animal model

Male Albino rats of Wistar strain weighing about 120 ± 150

g were obtained from the Central Animal House Facility, University of Madras, Taramani campus. The experimental protocol employed in this study received approval from the Institutional Animal Ethical Committee (IAEC no. 01 November 2015). The animals were acclimatised two per cage in large spacious cages under the conditions of controlled temperature (25°C ± 2°C) with 12/12 h light/dark cycle and were allowed food and water *ad libitum*. In addition, the animals were maintained on a commercial rat feed manufactured by Hindustan Lever Ltd., Mumbai, Maharashtra, India, under the trade name 'Gold Mohur Rat Feed'. The feed constitutes 5% fat, 21% protein, 55% nitrogen free extract and 4% fibre (w/w) with adequate vitamins and minerals.

Experimental protocol

In the present study, four groups, each comprising six rats ($n = 6$), were employed for the investigation. Potentials of a potentised homoeopathic drug, *Berberis vulgaris* 6c as an antioxidant and anti-urolithic, was used to treat acute high-grade hyperoxaluria in the current analysis.

- Group I (normal control) – Rats were maintained on standard food and water and no treatment was given
- Group II (urolithic control) – Rats were administered a single injection of sodium oxalate (70 mg/kg/day intraperitoneal) in 0.89% normal physiological saline on the 8th day of the experiment, to induce rapid screening of calcium oxalate crystals
- Group III (*Berberis vulgaris* 6c-treated group) – Rats were pre-administered with potentised homoeopathic drug, *Berberis vulgaris* 6c, (20 µl/day/100 g body weight, oral gavage) for 7 days with a single dose of sodium oxalate (70 mg/kg body weight) intraperitoneally on the 8th day as in Group II
- Group IV (drug control) – Rats were pre-administered with potentised homoeopathic drug, *Berberis vulgaris* (20 µl/day/100 g body weight, oral gavage), alone for 7 days

Sample collection

Collection and analysis of urine

The animals were housed in individual metabolic cages. Urine was collected in ice-jacketed flasks at 4°C for the assessment of renal function. The urine free from faecal contamination was collected for 24 h (at the end of the treatment, 8th day from the administration of sodium oxalate) with 0.2% sodium azide as a preservative. Cell debris and particulate matter were then removed from the urine samples by 1000 ×g centrifugation at 4°C for 15 min. The total urinary volume was measured by using a measuring cylinder and reported in millilitre. The pH of the freshly collected urine sample was measured using pH strips, and 24-h urine samples were analysed for its calcium,^[10] oxalate,^[11] phosphate,^[12] magnesium,^[12] uric acid^[13] and creatinine.^[14]

Renal tissue analysis

After blood collection, all animals, which were anaesthetised (with ketamine, 22 mg/kg body weight,

Tamilarasan, *et al.*: Plausible role of a potentised Homoeopathy drug, *Berberis vulgaris*, in ameliorating sodium oxalate-induced acute hyperoxaluria in Wistar rats

intramuscular), were sacrificed. The abdomen was cut open to remove both kidneys from each animal. The isolated kidneys were cleaned off extraneous tissue, rinsed in ice-cold physiological saline and used for tissue homogenate and histopathological analysis.

Homogenate analysis

The left kidney was finely minced and 10% homogenate was prepared in Tris-HCl buffer (0.01 mol/l, pH 7.4). The left kidney was finely minced and 10% homogenate was prepared in Tris-HCl buffer (0.01 mol/l, pH 7.4 and used for analysis of enzymatic and non-enzymatic antioxidants such as superoxide dismutase (SOD),^[15] catalase (CAT)^[16] and glutathione peroxidase (GPx),^[17] glutathione-S-transferase activity (GST)^[18] and the levels of Vitamin E^[19] and Vitamin C (Omaye *et al.*^[20]) as per standard protocols. Reduced glutathione was assayed by the method of Moron *et al.*^[21]

Histopathology

The right kidney was fixed in 10% neutral buffered formalin, processed in a series of graded alcohol and xylene, embedded in paraffin wax, sectioned at 5 µm and stained with haematoxylin and eosin for examination under a light microscope.

Western blot analysis

Renal tissues were lysed with radioimmunoprecipitation assay (RIPA) buffer containing 1% protease inhibitor PMSF. The supernatant was gathered after centrifugation. All lysates were diluted with sodium dodecyl sulphate (SDS) loading buffer and boiled for 5 min. Equal amounts of protein (50 µg) were loaded into each lane of a 10% SDS-PAGE gel for electrophoresis. Proteins were then transferred onto a polyvinylidene fluoride (PVDF) membrane. Then, the membranes were blocked with 5% BSA for an hour and incubated with primary rabbit polyclonal antibodies against No×2 (1:1000) against β-actin (1:1000) or a mouse polyclonal antibody at 4°C overnight, followed by incubation with a secondary antibody (anti-rabbit or anti-mouse IgG) for 1 h at 37°C. Membranes were developed using an enhanced chemiluminescence. Bio-Rad Clarity Western ECL kit. Band intensities were analysed using Image Lab software. Protein levels were normalised to β-actin expression. (Bio-Rad Laboratories, Inc. United States).

Data analysis

All values were expressed as mean ± standard error of

mean (SEM) of the results obtained from the average of at least three to six independent experiments. The data were analysed by one-way analysis of variance (ANOVA) using the SPSS software package for Windows (Version 20.0; SPSS Inc., Chicago, IL, USA) and *P* values were determined using the Student–Newman–Keuls and least significant difference (LSD) *post hoc* test. The statistical significance was set at *P* < 0.05.

RESULTS

Effect of potentised homoeopathic drug *Berberis vulgaris* on body weight, tissue weight, relative organ weight, urinary pH and volume of hyperoxaluria experimental rats

Table 1 depicts the effect of *Berberis vulgaris* on body weight, tissue weight, relative organ weight, urinary pH and volume in control and experimental rats. The analysis of body weight, urinary pH and volume showed that there was a statistically significant (*P* < 0.05) reduction in stone-forming group as compared to the normal control group, whereas the tissue and relative organ weight were higher (*P* < 0.05) in the stone-forming group compared to that of the normal saline animals. Pre-administration of homoeopathic preparation of *Berberis vulgaris* 6c for 7 days (20 µl/100 g of body weight) prevented (*P* < 0.05 vs. stone-forming group) the loss in body weight; significant attenuation of these parameters compared to urolithic vehicle control rats suggests its preventive effect on urolithiasis. A single intraperitoneal injection of sodium oxalate (7 mg/100 g of body weight) administered caused statistically significant (*P* < 0.05) 7% reduction in body weight with increase in 45% relative body and 33% organ weight of rats in Group II compared to normal control rats.

Pre-treatment with the Homoeopathy drug *Berberis vulgaris* (6c) statistically significantly (*P* < 0.05) attenuated the gain in body (1.86%) and organ weight (16.78%) compared to urolithic group, and no remarkable changes were observed in drug alone-treated rats. Administration of sodium oxalate (7 mg/100 g, i.p.) statistically significantly (*P* < 0.05) decreased (18.42%) urine pH and (43.47%) volume as compared with that of Group I, and pre-administration of *Berberis vulgaris* caused a statistically significant increase (16.12%) in urinary pH and (61.53%) volume compared with that of Group II.

Table 1: Effect of potentised homoeopathic drug *Berberis vulgaris* on body weight, tissue weight, relative organ weight, urinary pH and volume in acute hyperoxaluria experimental rats

Parameters	Group I	Group II	Group III	Group IV
Body weight (kg)	147.56±11.42	137.33±13.78a*	139.89±13.93b*	145.74±12.91
Kidney weight (mg)	0.735±0.06	0.978±0.13a*	0.813±0.09b*	0.761±0.09
Relative organ weight (mg/g)%	0.49±0.04	0.69±0.05a*	0.55±0.06 b*	0.53±0.06
Urine pH	7.3±0.56	6.2±0.55 a*	7.0±0.87b*	7.1±0.05
Urine volume (ml)/24 h	4.6±0.33	2.6±0.24a*	4.2±0.41b*	4.3±0.18

Values are expressed as mean ± SEM for six animals in each group. The letters 'a' and 'b' represent comparative study with Group I and Group II, respectively.

* Statistical significance at *P* < 0.05, SEM: Standard error of mean

Table 2: Effect of potentised homoeopathic drug *Berberis vulgaris* on urinary stone-forming biochemical constituents in acute hyperoxaluria experimental rats

Parameters	Group I	Group II	Group III	Group IV
Oxalate	1.55±0.10	2.23±0.1a*	1.83±0.12b*	1.65±0.11
Calcium	0.165±0.01	0.20±0.01a*	0.17±0.01b*	0.167±0.01
Magnesium	2.57±0.20	1.93±0.13a*	2.41±0.17b*	2.54±0.18
Phosphorus	0.34±0.03	0.28±0.02a*	0.31±0.03b*	0.33±0.03
Uric acid	0.11±0.01	0.16±0.02a*	0.15±0.17b*	0.14±0.02
Creatinine	1.24±0.14	1.4±0.15a*	1.31±0.09b*	1.26±0.13

Values are expressed as mean±SEM for six animals in each group. The letters 'a' and 'b' represent comparative study with Group I and Group II, respectively. *Statistical significance at $P < 0.05$. SEM: Standard error of mean

Effect of potentised homoeopathic drug *Berberis vulgaris* on urinary stone-forming biochemical constituents in hyperoxaluric experimental rats

There was a significant increase in urinary oxalate excretion (43.87%) [Table 2] in hyperoxaluria-induced rats compared to the control group rats. Simultaneously, *Berberis vulgaris*-treated group showed a statistically significant ($P < 0.05$) decrease (15%) in urine calcium and (17.93%) oxalate content compared with that of Group II [Table 2]. Administration of sodium oxalate (Group II) caused a significant decrease in magnesium (24.91%) and (17.64%) phosphorus content in urine, whereas the uric acid (45.45%) and (16.66%) creatinine content increased compared with that of the untreated group (Group I). Significant increase in magnesium (24.87%) and (10.71%) phosphorus, whereas decrease in uric acid (90.68%) and (7.14%) creatinine were observed in *Berberis vulgaris*-treated group [Table 2], and no significant changes were observed in drug control group rats.

Effect of potentised homoeopathic drug *Berberis vulgaris* on enzymatic antioxidants in hyperoxaluria experimental rats

Figures 1 and 2 show the activities of antioxidant enzymes in the kidneys of normal and experimental rats. As a result of oxalate exposure, a statistically significant ($P < 0.05$) decline in the enzymic antioxidant activities (SOD, CAT, GPx, GR, GST and G6PD) was observed in Group II animals. These changes highlight the deteriorating antioxidant status in the hyperoxaluric group. Non-enzymic antioxidants showed a marked decline in the levels of non-enzymic antioxidants such as GSH and levels of Vitamins C and E in sodium oxalate-treated rats, whereas a statistically significant increase ($P < 0.05$) in the activity of non-enzymic antioxidant towards control range was obtained by pre-treatment with *Berberis vulgaris* (6c), indicating its protective effect against oxidative stress induced by hyperoxaluria. No significant changes were observed in drug control (Group IV) animals.

Effect of potentised homoeopathic drug *Berberis vulgaris* on renal tissue histology of hyperoxaluria experimental rats

The histopathological changes observed are highlighted in the photomicrographs in Figure 3. Group 1 (control)

rats exhibited normal histoarchitecture of the kidney with normal glomeruli, tubules and interstitium. Sections from the kidney of rats with sodium oxalate (Group 2) administration showed glomerular shrinkage, tubular dilation and increased urinary space. An eosinophilic material was seen within the lumens of many of the tubules, and focal areas of interstitial inflammation were also observed. Group 3 rats (treated) showed amelioration of changes – glomeruli were normal and tubular dilatation was decreased. The renal tissue of Group 4 (drug control) rats showed normal histology, similar to that of control rats.

Effect of potentised homoeopathic drug *Berberis vulgaris* on the expression of NADPH oxidase of hyperoxaluria experimental rats

The expression of NADPH oxidase by Western blot analysis was markedly elevated in the sodium oxalate-induced acute hyperoxaluric rats when compared with normal control rats [Figure 4]. A marginal yet statistically significant ($P < 0.05$) decrease in No×2 expression was observed in the control group, and similar results were exhibited in *Berberis vulgaris*-treated and drug control groups when compared to the pathology group (Group II), indicating attenuation in renal oxidative stress.

DISCUSSION

The results of the current study show that exposure to Ox and CaOx crystals is associated with elevated levels of oxalate and calcium in urine of hyperoxaluria-induced rats as this may cause precipitation of oxalate in urine due to the poor solubility of calcium oxalate. Further, it leads to heterogeneous nucleation followed by aggregation of calcium oxalate crystals in the renal tubules, thereby inducing functional damage too.^[22,23] An earlier study conducted in our laboratory by Jyothilakshmi *et al.*^[6] in 2013 strengthened that increased urinary excretion of oxalate might be a consequence of increased activity of oxalate-synthesising enzymes on ingestion of ethylene glycol that attributes to cause oxidative damage in the tubules of hyperoxaluria-treated rats.

Hyperoxaluria and hypercalciuria are often encountered in calcium oxalate stone formers, signifying hypercalciuria to be one of the secondary causative factors for stone formation.

Tamilarasan, *et al.*: Plausible role of a potentised Homoeopathy drug, *Berberis vulgaris*, in ameliorating sodium oxalate-induced acute hyperoxaluria in Wistar rats

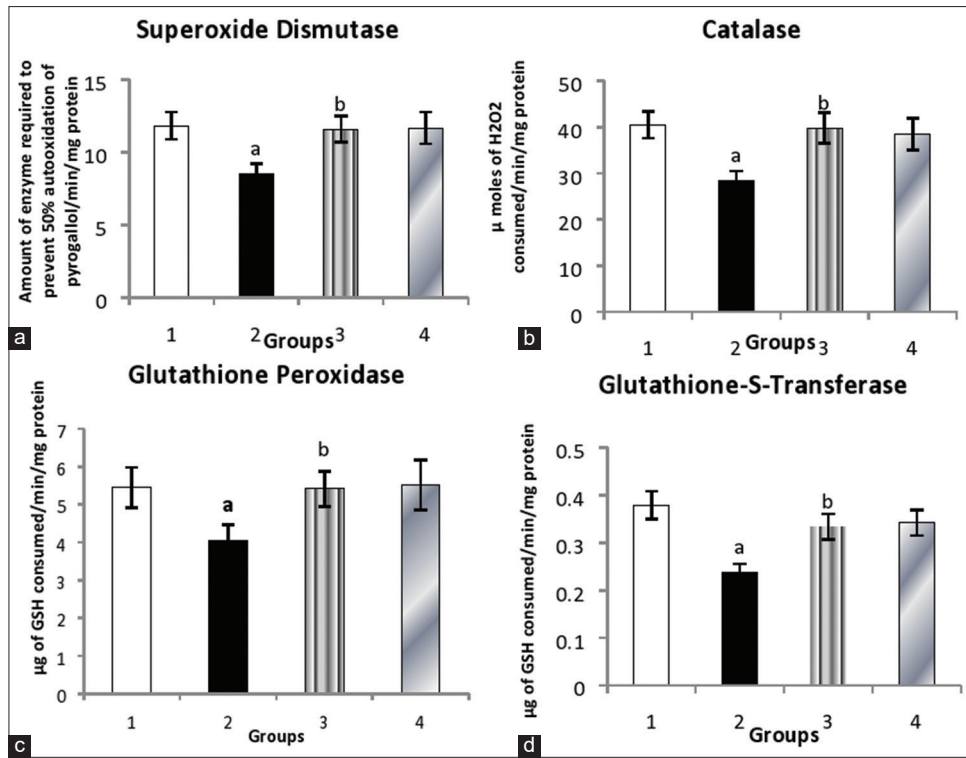


Figure 1: Effect of potentised homoeopathic drug of *Berberis vulgaris* on enzymatic antioxidants in acute hyperoxaluria experimental rats. (a) Superoxide dismutase. (b) Catalase. (c) Glutathione peroxidase. (d) Glutathione-S-transferase. Values are expressed as mean \pm standard error of the mean for six animals in each group. The letters 'a' and 'b' represent comparative study with Group I and Group II, respectively. The symbol * represents statistical significance at $P < 0.05$

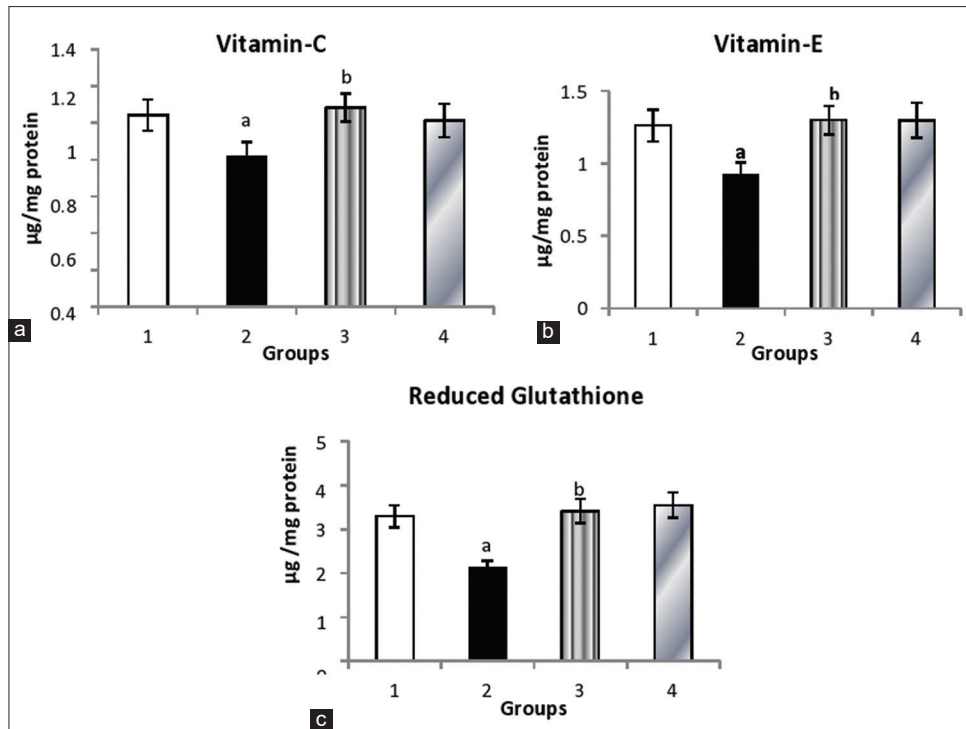


Figure 2: Effect of homoeopathic drug *Berberis vulgaris* on non-enzymatic antioxidants in acute hyperoxaluria experimental rats. (a) Vitamin C. (b) Vitamin E. (c) Reduced glutathione. Values are expressed as mean \pm standard error of the mean for six animals in each group. The letters 'a' and 'b' represent comparative study with Group I and Group II, respectively. The symbol * represents statistical significance at $P < 0.05$

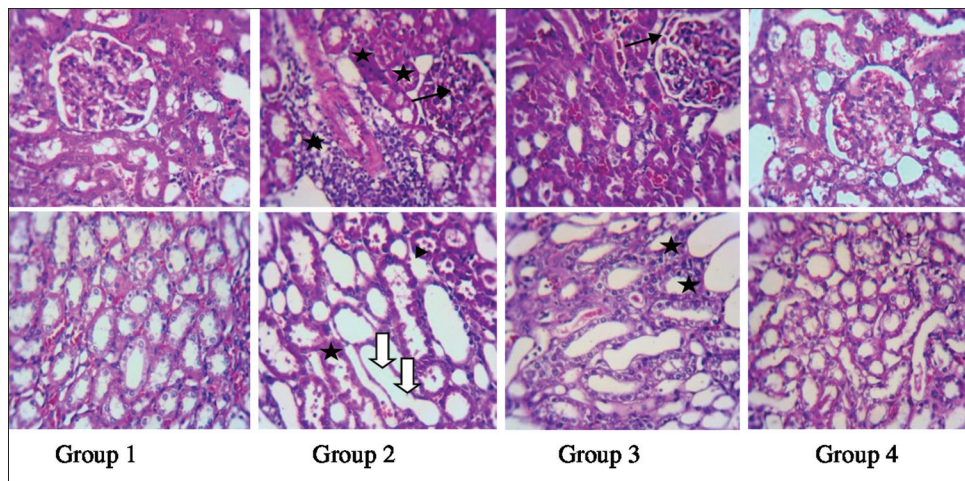


Figure 3: Histo-architecture of the renal sections of hyperoxaluria in experimental groups stained with haematoxylin and eosin ($\times 400$) Group 1 – control rats showing normal histo-architecture; Group 2 – hyperoxaluria-induced rats showing glomerular shrinkage (arrows), tubular dilation (broad arrows) and eosinophil material within tubular lumina (arrow heads), a focus of inflammation (stars) is also seen; Group 3 – hyperoxaluria-induced rats showing normal glomeruli (arrow), tubular dilation is mild as compared to that of Group 2. Group 4 – control drug rats showing normal histology

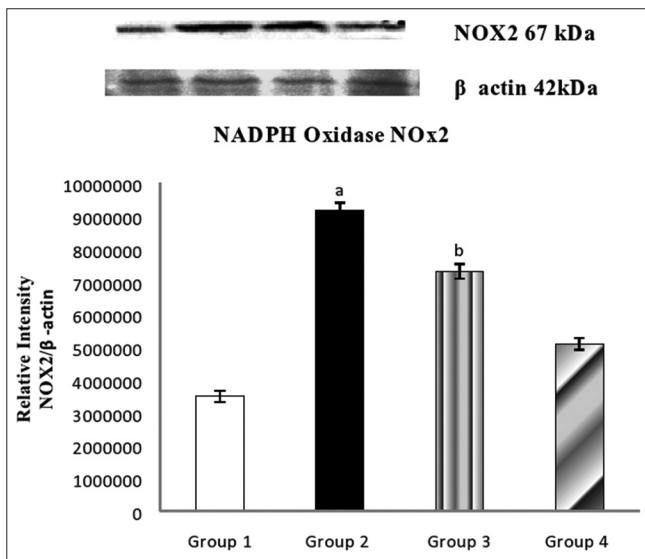


Figure 4: Effect of *Berberis vulgaris* on the expression of NOX2 (NADPH oxidase) in the experimental hyperoxaluria. Data were expressed as the mean \pm standard error of the mean ($n = 3$). Values are statistically significant at the level of $P < 0.05$, where 'a' compared with Group 1; 'b' compared with Group 2. Lane 1: Control; Lane 2: Hyperoxaluria; Lane 3: *Berberis vulgaris* + hyperoxaluria; Lane 4: *Berberis vulgaris* alone

Hypercalciuria could occur in both healthy and individuals with stone formation, wherein stone formers tend to excrete larger and aggregated particles than healthy individuals. Increased urinary calcium excretion in oxalate-induced rats favours the nucleation and precipitation of calcium oxalate from urine and subsequently crystal growth.^[24] Nevertheless, the present study corroborates an increased excretion of calcium in the urine of hyperoxaluric rats.

Calcium oxalate crystallisation of urolithiasis relies on various stone-promoting and -inhibiting factors. As far as the fact that calcium and phosphates are stone-promoting inorganic factors while magnesium is a stone-inhibiting factor is concerned,^[25]

in the existing study, a diminished level of magnesium was observed in urolithic rats. In urolithiasis, glomerular filtration rate (GFR) decreases due to stones in the urinary system obstructing urine outflow, which leads to the accumulation of waste products in the blood, particularly nitrogenous substances such as urea, creatinine and uric acid.^[26] Sodium oxalate induced renal dysfunction as revealed by the renal profile is ameliorated on administration of *Berberis vulgaris* obviating its protective role.

Several studies have supported the involvement of oxidative stress in CaOx nephrolithiasis by treating hyperoxaluric rats with antioxidants. In our study, we found that *Berberis vulgaris* furnishes a strong defensive antioxidant activity against oxidative stress and thereby helps in the management of oxidative stress by protecting the renal tissue from oxidative stress. The antioxidant effect of *Berberis vulgaris* might be attributed to the predominant active compound berberine, an isoquinoline alkaloid, which has antioxidant property by nature.^[27]

The current study supported the above findings along with the histological features where oxalate-induced hyperoxaluric rats showed glomerular damage, tubular dilatation, membrane damage, increased urinary space and deposition of CaOx crystals; on the other hand, treatment with *Berberis vulgaris* demonstrated notable improvements which might be due to the potent antioxidant, anti-inflammatory and antiurolithic activities as reported by earlier studies.^[27]

Previously, Khan^[1] reported that calcium oxalate rat model nephrolithiasis is associated with the activation of NADPH oxidase, production of ROS, development of oxidative stress and renal injury. Among the NOX family members, NOX2 is expressed in macrophages and kidney cells that participate in excessive ROS generation. By inhibiting antioxidant defences, oxalate can induce oxidative damage in experimental rats and increase oxidative stress, which plays a crucial role in the

Tamilarasan, *et al.*: Plausible role of a potentised Homoeopathy drug, *Berberis vulgaris*, in ameliorating sodium oxalate-induced acute hyperoxaluria in Wistar rats

progression of renal disease. In our existing study, harmful cellular oxidative stress was suppressed on pre-treatment with *Berberis vulgaris* in treated group, thereby inhibiting oxalate-induced ROS production which may have prevented crystal adherence and the subsequent development of nephrolithiasis, suggesting that early activation of NADPH oxidase delayed the sequential events of urolithiasis.

This study has certain limitations. First, the mechanism by which NOX2 affects the kidney's redox state, and inhibition of this enzyme to modulate oxidative stress and ROS production, remains to be delineated. Second, the extent oxidative stress-induced renal injury in renal tissue provoking the retention of calcium oxalate crystals, which forms the nidus and results to a cascade of events such as nephrolithiasis is not clear. Similarly, in-depth analysis of the genes that involve specific biological pathways triggered as renal tissue responses to hyperoxaluria, and ROS production remains to be further investigated.

CONCLUSION

Thus, these data suggest that a combination of antioxidants and NADPH oxidase inhibitor may synergistically inhibit nephrolithiasis progression and may be considered for the development of novel therapeutics. Potentised homoeopathic drug *Berberis vulgaris* might ameliorate hyperoxaluria by eliminating oxidative stress of renal tissue, which plays a key role in the production of reactive oxygen species (ROS) with the involvement of NADPH oxidase as a potential target in the treatment and reoccurrence of renal stone disease. There is still a paucity of information on the exact physiologic and pathologic roles of NADPH oxidases in the kidney and hence further research should elucidate these effects.

Financial support and sponsorship

This study was supported by a research grant from the Central Council for Research in Homoeopathy, New Delhi, India. [FNO: 17-211/2013-14].

Conflicts of interest

None declared.

REFERENCES

- Khan SR. Reactive oxygen species, inflammation and calcium oxalate nephrolithiasis. *Transl Androl Urol* 2014;3:256-76.
- Thamilselvan V, Menon M, Thamilselvan S. Selective Rac1 inhibition protects renal tubular epithelial cells from oxalate-induced NADPH oxidase-mediated oxidative cell injury. *Urol Res* 2012;40:415-23.
- Benzie IF, Wachtel-Galor S. Herbal medicine: An introduction to its history, usage, regulation, current trends, and research needs. *Herbal medicine: Biomolecular and clinical aspects*. In: Benzie IF, Wachtel-Galor S, editors. *Herbal Medicine: Biomolecular and Clinical Aspects*. Ch. 1., 2nd ed. Boca Raton, FL: CRC Press/Taylor & Francis; 2011.
- Arayne MS, Sultana N, Bahadur SS. The *Berberis* story: *Berberis vulgaris* in therapeutics. *Pak J Pharm Sci* 2007;20:83-92.
- Zuo J, Khan A, Glenton PA, Khan SR. Effect of NADPH oxidase inhibition on the expression of kidney injury molecule and calcium oxalate crystal deposition in hydroxy-L-proline-induced hyperoxaluria in the male Sprague-Dawley rats. *Nephrol Dial Transplant* 2011;26:1785-96.
- Jyothilakshmi V, Thellamudhu G, Kumar A, Khurana A, Nayak D, Kalaiselvi P. Preliminary investigation on ultra high diluted *B. vulgaris* in experimental urolithiasis. *Homeopathy* 2013;102:172-8.
- Khan SR. Crystal/cell interaction and nephrolithiasis. *Arch Ital Urol Androl* 2011;83:1-5.
- Khan SR. Reactive oxygen species as the molecular modulators of calcium oxalate kidney stone formation: Evidence from clinical and experimental investigations. *J Urol* 2013;189:803-11.
- Joshi S, Khan SR. Opportunities for future therapeutic interventions for hyperoxaluria: Targeting oxidative stress. *Expert Opin Ther Targets* 2019;23:379-91.
- Mustafa FA, Medeiros DM. Proximate composition, mineral content, and fatty acids of catfish (*Ictalurus punctatus*, Rafinesque) for different seasons and cooking methods. *J Food Sci* 1985;50:585-8.
- Hodgkinson A, Williams A. An improved colorimetric procedure for urine oxalate. *Clin Chim Acta* 1972;36:127-32.
- Fiske CH, Subbarow Y. The colorimetric determination of phosphorus. *J Biol Chem* 1925;66:375-400.
- Caraway WT, Hald PM. Uric acid. In: Seligson D, ed. *Standard Methods of Clinical Chemistry*, Vol. 4. New York, NY: Academic Press; 1963;21:239-47.
- Slot C. Plasma creatinine determination. A new and specific Jaffe reaction method. *Scand J Clin Lab Invest* 1965;17:381-7.
- Marklund S, Marklund G. Involvement of the superoxide anion radical in the autoxidation of pyrogallol and a convenient assay for superoxide dismutase. *Eur J Biochem* 1974;47:469-74.
- Sinha AK. Colorimetric assay of catalase. *Anal Biochem* 1972;47:389-94.
- Rotruck JT, Pope AL, Ganther HE, Swanson AB, Hafeman DG, Hoekstra WG. Selenium: Biochemical role as a component of glutathione peroxidase. *Science* 1973;179:588-90.
- Habig WH, Pabst MJ, Jakoby WB. Glutathione S-transferases. The first enzymatic step in mercapturic acid formation. *J Biol Chem* 1974;249:7130-9.
- Desai ID. Vitamin E analysis methods for animal tissues. *Methods Enzymol* 1984;105:138-47.
- Omaye ST, Turnbull JD, Sauberlich HE. Selected methods for the determination of ascorbic acid in animal cells, tissues, and fluids. *Methods Enzymol* 1979;62:3-11.
- Moron MS, Depierre JW, Mannervik B. Levels of glutathione, glutathione reductase and glutathione S-transferase activities in rat lung and liver. *Biochim Biophys Acta* 1979;582:67-78.
- Thamilselvan S, Khan SR, Menon M. Oxalate and calcium oxalate mediated free radical toxicity in renal epithelial cells: Effect of antioxidants. *Urol Res* 2003;31:3-9.
- Scheid CR, Cao LC, Honeyman T, Jonassen JA. How elevated oxalate can promote kidney stone disease: Changes at the surface and in the cytosol of renal cells that promote crystal adherence and growth. *Front Biosci* 2004;9:797-808.
- Patel D, Kulshrestha D. Ayurveda perspective on Mootrashmari and its management: An literature based review. *J Drug Deliv Ther* 2018;8:77-80.
- Ghodasara J, Pawar A, Deshmukh C, Kuchekar B. Inhibitory effect of rutin and curcumin on experimentally-induced calcium oxalate urolithiasis in rats. *Pharmacognosy Res* 2010;2:388-92.
- Jyothilakshmi V, Thellamudhu G, Chinta R, Alok K, Anil K, Debadatta N, *et al.* Beneficial antioxidative effect of the homeopathic preparation of *Berberis vulgaris* in alleviating oxidative stress in experimental urolithiasis. *Complement Med Res* 2014;21:7-12.
- Bashir S, Gilani AH, Siddiqui AA, Pervez S, Khan SR, Sarfaraz NJ, *et al.* *Berberis vulgaris* root bark extract prevents hyperoxaluria induced urolithiasis in rats. *Phytother Res* 2010;24:1250-5.

Tamilarasan, *et al.*: Plausible role of a potentised Homoeopathy drug, *Berberis vulgaris*, in ameliorating sodium oxalate-induced acute hyperoxaluria in Wistar rats

बर्बरिस वल्गारिस से तैयार होम्योपैथिक औषधि एनएडीपीएच ऑक्सीडेस और सोडियम ऑक्सालेट से उत्प्रेरित उच्च श्रेणी के गंभीर हाइपेरोक्जालुरिया को रोकता है

पृष्ठभूमि: गुर्दा में हाइपेरोक्जालुरिया और कैल्शियम ऑक्सालेट क्रिस्टल का निक्षेप प्रतिक्रियाशील ऑक्सीजन प्रजातियों के अतिउत्पादन का मार्ग प्रशस्त करता है जिसके परिणामस्वरूप, ऑक्सीडेटिव तनाव में वृद्धि और गुर्दे की क्षति होती है। कोषिकीय स्तर पर, प्रतिक्रियाशील ऑक्सीजन प्रजातियों के उत्पादन में सम्मिलित माइटोकॉन्ड्रिया और एनएडीपीएच ऑक्सीडेस हाइपेरोक्जालुरिया से उत्प्रेरित गुर्दे की क्षति के पैथोजेनेसिस में एक गंभीर भूमिका का निर्वाह करता है। **उद्देश्य:** इसका उद्देश्य चूहों में सोडियम ऑक्सालेट से उत्प्रेरित उच्च श्रेणी के गंभीर हाइपेरोक्जालुरिया के विरुद्ध एनएडीपीएच ऑक्सीडेस के नियमन पर होम्योपैथी औषधि, बर्बरिस वल्गारिस; एक प्रबल एन्टीऑक्सीडेंट के चिकित्सीय प्रभाव का अनुसंधान करना था। **पदार्थ और पद्धति:** नर विस्टर चूहों में हाइपेरोक्जालुरिया को इन्ट्रा-पेरिटोनियम के माध्यम से सोडियम ऑक्सालेट (70 मिग्रा/किग्रा शरीर का वजन) का एकमात्र डोज देकर उत्प्रेरित किया गया और चिकित्सा समूहों का पूर्व उपचार होम्योपैथी औषधि, बर्बरिस वल्गारिस 6सी (20 µl/शरीर के वजन का 100 ग्राम) के बहुत कम डोज के साथ 7 दिनों तक किया गया। **परिणाम:** बर्बरिस वल्गारिस ने हाइपेरोक्जालुरिया से उत्प्रेरित ऑक्सीडेटिव तनाव को महत्वपूर्ण रूप से कम किया और गुर्दे के ऊतकों में एन्टीऑक्सीडेंट एन्जाइम के गतिविधियों को बहाल किया। ऊतकीय विश्लेषण ने निरूपित किया कि बर्बरिस वल्गारिस द्वारा किया गया उपचार गुर्दे की एपिथेलियल क्षति और सूजन को कम करता है और सामान्य ग्लोमेरुलर मॉर्फोलॉजी को बहाल करता है। इसके अतिरिक्त, एनएडीपीएच ऑक्सीडेस के इम्युनोब्लॉटिंग विश्लेषण ने हाइपेरोक्जालुरिक चूहों के गुर्दों के ऊतकों में बढ़ी हुई महत्वपूर्ण सक्रियता को प्रकट करता है जब इसकी तुलना नियंत्रित चूहों से की गयी। इसे बर्बरिस वल्गारिस के उपचार द्वारा सामान्य स्थिति की ओर लौटाया गया। **निष्कर्ष:** इसलिए, हमारे परिणामों ने इस बात पर बल दिया कि होम्योपैथी औषधि, बर्बरिस वल्गारिस विस्टर चूहों में सोडियम ऑक्सालेट से उत्प्रेरित गंभीर हाइपेरोक्जालुरिया को एनएडीपीएच ऑक्सीडेस के निषेध से माइटोकॉन्ड्रियल ऑक्सीडेटिव तनाव को व्यवस्थित करके सुधारने में प्रभावशाली होता है।

La préparation homéopathique de *Berberis vulgaris* inhibe la NADPH oxydase et améliore l'hyperoxalurie aiguë de haut grade induite par l'oxalate de sodium

Contexte: L'hyperoxalurie et le dépôt de cristaux d'oxalate de calcium dans les reins entraînent une surproduction d'espèces réactives de l'oxygène, entraînant le développement d'un stress oxydatif et de lésions rénales. Au niveau cellulaire, les mitochondries et la NADPH oxydase impliquées dans la production d'espèces réactives de l'oxygène jouent un rôle crucial dans la pathogenèse des lésions rénales induites par l'hyperoxalurie. **Objectif:** L'objectif était d'étudier l'effet thérapeutique du médicament homéopathique *Berberis vulgaris*, un antioxydant puissant, sur la régulation de la NADPH oxydase contre l'hyperoxalurie aiguë induite par l'oxalate de sodium chez le rat. **Matériel et méthodes:** Une hyperoxalurie a été induite chez des rats mâles Wistar en administrant une dose unique d'oxalate de sodium (70 mg / kg de poids corporel) par voie intrapéritonéale, et les groupes de traitement ont été prétraités avec le médicament homéopathique *Berberis vulgaris* 6c (20 µl / 100 g de corps) dose ultra-faible pendant 7 jours. **Résultats:** *Berberis vulgaris* a réduit de manière significative le stress oxydatif induit par l'hyperoxalurie et restauré les activités enzymatiques antioxydantes dans les tissus rénaux. L'analyse histologique a montré que le traitement par *Berberis vulgaris* diminue les lésions épithéliales rénales et l'inflammation et rétablit la morphologie glomérulaire normale. En outre, les analyses d'immunoempreinte de la NADPH oxydase ont révélé une activité accrue significative dans le tissu rénal des rats hyperoxaluriques par rapport à celle des rats témoins. Cela a été ramené à la normale par le traitement *Berberis vulgaris*. **Conclusion:** Ainsi, nos résultats ont souligné que le médicament homéopathique *Berberis vulgaris* est efficace pour améliorer l'hyperoxalurie aiguë induite par l'oxalate de sodium chez les rats Wistar en modulant le stress oxydatif mitochondrial par l'inhibition de la NADPH oxydase.

La preparación homeopática de *Berberis vulgaris* inhibe la NADPH oxidasa, y mejora la hiperoxaluria aguda de alto grado inducida por oxalato sódico

Antecedentes: La hiperoxaluria y la deposición de cristal de oxalato de calcio en los riñones conducen a la sobreproducción de especies reactivas de oxígeno, lo que resulta en el desarrollo de estrés oxidativo y lesión renal. A nivel celular, las mitocondrias y la NADPH oxidasa que participan en la producción de especies reactivas de oxígeno desempeñan un papel crucial en la patogénesis de la hiperoxaluria inducida por la lesión renal. **Objetivo:** El objetivo era investigar el efecto terapéutico del fármaco homeopático *Berberis vulgaris*, un potente antioxidante, sobre la regulación de la NADPH oxidasa contra la hiperoxaluria aguda inducida por oxalato de sodio de alto grado en ratas. **Materiales y métodos:** Se indujo hiperoxaluria en ratas Wistar masculinas mediante la administración de una dosis única de oxalato sódico (70 mg/kg de peso corporal) intraperitoneal, y los grupos de tratamiento fueron pretratados con el medicamento homeopático *Berberis vulgaris* 6c (20 µl/100 g de peso corporal), dosis ultrabaja durante 7 días. **Resultados:** *Berberis vulgaris* redujo significativamente el estrés oxidativo inducido por la hiperoxaluria y restauró las actividades enzimáticas antioxidantes en el tejido renal. El análisis histológico describió que el tratamiento con *Berberis vulgaris* disminuye el daño epitelial renal y la inflamación y restauró la morfología glomerular normal. Además, los análisis de inmunotransferencia de NADPH oxidasa revelaron un aumento significativo de la actividad en el tejido renal de ratas hiperoxalúricas cuando se comparan con las ratas control. Esto fue llevado de vuelta a la normalidad por el tratamiento de la vulgaris de *Berberis*. **Conclusión:** Así, nuestros resultados enfatizaron que el fármaco de Homeopatía *Berberis vulgaris* es eficaz en la mejora de la hiperoxaluria aguda inducida por oxalato sódico en ratas Wistar, modulando el estrés oxidativo mitocondrial a través de la inhibición de la NADPH oxidasa.

Tamilarasan, *et al.*: Plausible role of a potentised Homoeopathy drug, *Berberis vulgaris*, in ameliorating sodium oxalate-induced acute hyperoxaluria in Wistar rats

die Homöopathischen Zubereitung von *Berberis vulgaris* hemmt die NADPH-Oxidase, und bessert Natrium-Oxalat-induzierten akuten hochgradigen Hyperoxaluria

Hintergrund: Hyperoxaluria- und calcium-Oxalat-Kristall-Ablagerung in den Nieren führen zu einer überproduktion von reaktiven Sauerstoff-Spezies, was in der Entwicklung von oxidativem stress und der renalen Schädigung. Auf der zellulären Ebene, Mitochondrien und NADPH-oxidase beteiligt reaktiven Sauerstoff-Spezies Produktion spielen eine entscheidende Rolle in der Pathogenese der hyperoxaluria induzierten renalen Schädigung. **Ziel:** Das Ziel war es, zu untersuchen, die therapeutische Wirkung von homöopathischen Medikaments *Berberis vulgaris*, ein starkes Antioxidans, die auf die Regulierung der NADPH-oxidase vor akuten hohen Grad der Natrium-Oxalat - induzierten hyperoxaluria in Ratten. **Materialien und Methoden:** Hyperoxaluria war induzierten männlichen Wistar-Ratten durch die Verabreichung einer einzigen Dosis von Natrium-Oxalat (70 mg/kg Körpergewicht) intraperitonealer und den Behandlungsgruppen wurden vor Behandlung mit homöopathischen Medikaments *Berberis vulgaris* 6C (20 µl/100 g Körpergewicht) ultra-niedrig-Dosis für 7 Tage. **Ergebnisse:** *Berberis vulgaris* deutlich reduzierend hyperoxaluria induziert oxidativen stress und die Wiederherstellung antioxidativen Enzym-Aktivitäten in der Niere Gewebe. Bei der histologischen Untersuchung dargestellt, die *Berberis vulgaris* - Behandlung vermindert den renalen epithelialen Schäden und Entzündungen und restauriert, normale glomeruläre Morphologie. Darüber hinaus immunoblotting analysiert der NADPH-oxidase zeigte signifikant erhöhte Aktivität im Nieren-Gewebe hyperoxaluric Ratten im Vergleich zu der Kontrolle Ratten. Dieser wurde gebracht, wieder normal *Berberis vulgaris* Behandlung. **Fazit:** Also, unsere Ergebnisse Unterstrichen, dass die Homöopathie-Medikament *Berberis vulgaris* ist wirksam bei der Verbesserung der Natrium-Oxalat - induzierten akuten hyperoxaluria in Wistar-Ratten durch die Modulation der mitochondrialen oxidativen stress durch die Hemmung der NADPH-oxidase.

柏柏尔里斯的同源性制剂抑制NADPH氧化酶，和增生酸钠草酸钠诱导急性高档高氧沙利亚

背景：在肾脏中，高氧酸和氧化钙晶体沉积导致活性氧物种生产过剩，导致氧化应激和肾损伤的发展。在细胞水平上，参与活性氧物种生产的线粒体和NADPH氧化酶在高氧分诱导肾损伤的发病机制中起着至关重要的作用。目的：目的是调查顺势疗法药物小檗寻常，强效的抗氧化剂，对急性高品位草酸钠诱导高尿症大鼠NADPH氧化酶调节的治疗效果。材料和方法：高草酸尿症被诱导雄性威斯塔大鼠的通过施用草酸钠的单剂量（70毫克/千克体重）腹膜内，并且治疗组与顺势疗法药物小檗6C（20微升/100g体重的治疗体重）超低剂量持续7天。结果：柏柏尔里斯庸俗显著减少高氧铝引起氧化应激和恢复抗氧化酶活性在肾脏组织。组织学分析表明，柏柏拉里斯治疗可减少肾上皮损伤和炎症，恢复正常的肾球状形态。此外，与对照大鼠相比，NADPH氧化酶的免疫印迹分析表明，高氧大鼠的肾脏组织活性显著增加。这被柏柏拉里斯的粗俗待遇恢复正常了。结论：因此，我们的研究结果强调，通过抑制NADPH氧化酶，调节线粒体氧化应激，有效改善威斯塔大鼠的氧化钠诱导急性高氧沙。