

Pelvic Inflammatory Disease Treated with Homoeopathic Medicine *Calcarea carbonica*: A case Report

Swati Pandey, Raj K. Pandit*

Department of Case Taking and Repertory, Mahesh Bhattacharyya Homoeopathic Medical College and Hospital, Howrah, West Bengal, India

Abstract

Introduction: Pelvic Inflammatory Disease (PID) is a polymicrobial infection of the upper genital tract characterised clinically by triad of symptoms and signs: pelvic pain, cervical motion with adnexal tenderness and fever. Conventional treatment is with broad-spectrum antibiotics. The alternative medicine, especially Homoeopathy, is the second choice of therapy as per the WHO. Case reports of PID in the medical literature are scant. We aim to report a case treated with homoeopathic constitutional medicine in a woman suffering from PID. **Case Summary:** A 29-year-old female presented with the symptoms of white discharge per vagina, constant dull pain in the lower abdomen, low backache, fever and lassitude for 2 weeks. Clinical findings and ultrasound of the whole abdomen suggested PID. Individualised homoeopathic medicine *Calcarea carbonica* was prescribed in centesimal potency which showed a positive role in the treatment of PID. Causal attribution of changes in her condition to the homoeopathic treatment was depicted by modified Naranjo criteria. Future observational studies and randomised control trials are suggested to ascertain the efficacy of homoeopathy in the cases of PID.

Keywords: *Calcarea carbonica*, Homoeopathy, Individualised medicine, Modified Naranjo criteria, Pelvic inflammatory disease

INTRODUCTION

Pelvic inflammatory disease (PID) is a spectrum of infection and inflammation of the upper genital tract organs, typically involving the uterus (endometrium), fallopian tubes, ovaries, pelvic peritoneum and surrounding structures.^[1,2] Upper reproductive tract infection is believed to be caused by bacteria that ascend from the lower reproductive tract. It is assumed that this ascension is enhanced during menstruation due to loss of endocervical barriers.^[3]

The primary organisms are sexually transmitted (60%–75%) and limited approximately to *Neisseria gonorrhoeae* (30%), *Chlamydia trachomatis* (30%) and *Mycoplasma hominis* (10%). The secondary organisms normally found in the vagina are almost always associated sooner or later. These are *Escherichia coli* (30%–40%), group B *Streptococcus* and *Staphylococcus*, *Bacteroides* species – *fragilis* (20%) and *bivius*, *Peptostreptococcus* and *Peptococcus*.^[1,2,4]

The incidence varies from 1% to 2% per year among sexually active women. About 85% are spontaneous infections in sexually active females of reproductive age.^[1]

Some patients may be asymptomatic. The classic triad, however, is pelvic pain, cervical excitation pain and adnexal tenderness, often in the presence of fever. In severe cases, abdominal rebound tenderness may be present; vaginal discharge may be seen. Some women may have associated menorrhagia, metrorrhagia and urinary symptoms.^[5]

As a system of medicine, Homoeopathy offers an effective treatment by reducing both the symptoms as well as further spread of infection. A study of 40 women between 18 and 40 years of age having infertility due to polycystic ovarian syndrome, chronic PID and endometriosis demonstrated the effectiveness of homoeopathic constitutional *Similimum* in the management of female infertility.^[6]

***Address for correspondence:** Dr. Raj K. Pandit,
Department of Case Taking and Repertory, Mahesh Bhattacharyya
Homoeopathic Medical College and Hospital, Howrah,
West Bengal, India.
E-mail: raj.dr2609@gmail.com

Received: 12.06.2020; **Accepted:** 27.11.2020; **Published:** 29.12.2020

Access this article online

Quick Response Code:



Website:
www.ijrh.org

DOI:
10.4103/ijrh.ijrh_60_20

This is an open access journal, and articles are distributed under the terms of the Creative Commons Attribution-NonCommercial-ShareAlike 4.0 License, which allows others to remix, tweak, and build upon the work non-commercially, as long as appropriate credit is given and the new creations are licensed under the identical terms.

For reprints contact: WKHLRPMedknow_reprints@wolterskluwer.com

How to cite this article: Pandey S, Pandit RK. Pelvic inflammatory disease treated with homoeopathic medicine *Calcarea carbonica*: A case report. Indian J Res Homoeopathy 2020;14:287-92.

CASE REPORT

Patient information

A 29-year-old female came to the Outpatient Department of Mahesh Bhattacharyya Homoeopathic Medical College and Hospital on 10th August 2019, with complaints of copious, purulent, white discharge per vagina, constant dull pain in the lower abdomen, low backache, fever and lassitude for 2 weeks. Initially, the patient had taken few doses of paracetamol for pain and fever herself with temporary relief.

She was fat, flabby and whitish complexioned in appearance. She had a history of typhoid fever during her childhood and an episode of PID a year ago which was treated with allopathic treatment. The patient was married and had two daughters. Family history was insignificant.

Generals

The patient was short tempered and anxious. Her memory and intellect were good, but it took time for her to understand things. She was lazy and did not want company. The appetite was good with desire for mutton, sour and salty⁺⁺ and cold things⁺⁺ (++ indicates moderate intensity of the symptom). She drank profuse quantity of water, and the tongue was moist. The patient also had a tendency of profuse sweating even on slight exertion which was not offensive in nature and did not stain the clothes. Her bowel movement was regular, and the character of stool was hard and offensive. The patient usually preferred to lie down after slight physical exertion and the sleep was sound. She was susceptible to cold and her thermal reaction was chilly. Her menses were regular, but the flow was clotted and offensive.

Clinical findings

Clinical findings were tenderness of the lower abdomen and purulent white discharge per vagina. Temperature was 99.4°F. Ultrasonography (USG) of the whole abdomen suggested PID [Figure 1]. The case fulfilled the clinical diagnosis of PID as per the Centers for Disease Control and Prevention 2015.^[7]

Repertorial analysis

Repertorisation was done by HOMPAT Classic M.D. Repertory Version 8.0 software (Mind Technologies, Mumbai,

Maharashtra, India)^[8] using Kent repertory giving priority to mental generals over physical generals and then to particular symptoms [Figure 2].

After the repertorial analysis, *Sepia* was found to cover 10 of 11 rubrics and scored highest marks, i.e., 27. Both *Calcarea carbonica* and *Sulphur* covered all the rubrics (11) and scored 25 marks. After consulting Homoeopathic Materia Medica, *Calcarea carbonica* was prescribed. The indications for prescription were fat patient with relaxed musculature, short tempered, full of anxiety, easily tired, mentally as well as physically, could not tolerate even slightest exertion, desire for salty things and cold drinks, wanted to drink lot of water, profuse sweat, tendency to catch cold easily and chilly thermal reaction.

Prescription

Two doses of *Calcarea carbonica* 200c were prescribed on the day of first visit along with placebo for 4 weeks. The patient was advised to maintain local hygiene.

The patient was followed for another 3 months, and no complication or relapse of the symptoms was noted during this period [Table 1].

The modified Naranjo criteria (Monarc) was used^[9] for assessing causal attribution of improvement to the homoeopathic medicine and the total score was 9 [Table 2].

DISCUSSION

PID is a clinical diagnosis implying upper genital tract infection and inflammation. Conventional treatment is with broad-spectrum antibiotics. PID is a polymicrobial infection, where two or more antibiotics may be necessary. Some patients with a severe infection need to be hospitalised to receive antibiotics intravenously. With antibiotics, acute PID may resolve within 10–14 days; however, for chronic PID, surgery is the treatment of choice.^[4] In this case, a history of previous episode of PID a year back favours the diagnosis of chronic PID.

Homoeopathy is a system of medicine which treats the patient not the disease. It also aims at a rapid, gentle and permanent restoration of health.^[10] As per §61, ‘...no physician ever

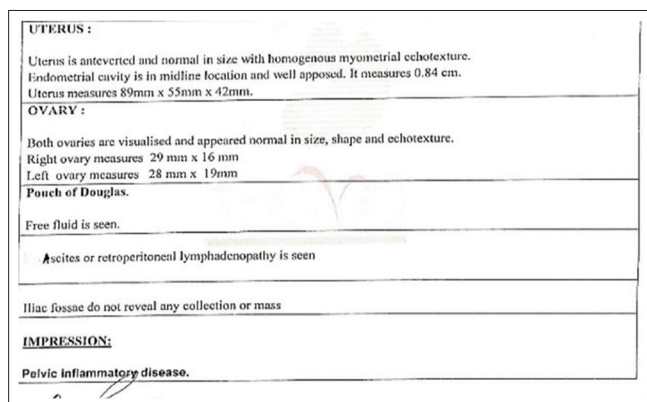


Figure 1: Ultrasongraphy of the whole abdomen on 9th August 2019

Remedy Name	Sep	Calc	Sulp	Phos	Am	Hell	Nat-s	Calc-v	Lyc	Sph	Merc	Chin	Hell-v	Ph-ar
Totally	27	25	25	24	23	21	21	21	21	20	19	19	19	19
Symptom Covered	10	11	11	10	10	10	10	9	9	9	10	9	8	8
[K1] [Mind]Ange-prachin(see irritability quarrelsome)	3	2	3	2	3	3	1	2	3	3	1	1	3	2
[K1] [Mind]Anxiety	2	3	3	3	2	3	3	3	3	3	2	3	3	2
[K1] [Mind]Dullness sluggishness difficulty of thinking and comprehension	3	3	3	3	1	3	3	3	3	3	2	2	2	3
[K1] [Mind]Indolence aversion to work	3	2	3	2	1	3	1	2	2	1	1	3	3	2
[K1] [Stomach]Desires Cold drinks	2	2	1	3	3	1	2	2	2	3	3	3	3	2
[K1] [Stomach]Desires Salt things	2	1	3	3	3	3	3	3	3	3	3	3	3	2
[K1] [Perspiration]Profuse	3	3	2	2	3	3	2	3	3	3	3	3	3	3
[K1] [Generations]Weakness aversion (see lassitude weakness) Exertion	2	3	2	3	3	2	3	2	2	3	2	2	3	3
[K1] [Abdomen]Pain.Aching dull pain (see Boring Gearing etc.) Hypoga	3	1	3	2	3	1	2	2	2	2	2	2	1	1
[K1] [Genitalia female]Leucorrhoea Copious	3	3	2	2	2	2	2	1	1	1	2	1	1	2
[K1] [Genitalia female]Leucorrhoea Offensive	3	1	2	2	2	2	2	2	2	2	2	2	2	3

Figure 2: Repertorisation chart

Table 1: Follow-up and intervention

Date of follow-up	Main complaints	Investigation findings	Prescription
7 September 2019	Copious discharge per vagina - decreased (↓) Dull pain in lower abdomen - decreased (↓) Low backache - decreased (↓) No fever and lassitude		Placebo
12 October 2019	Copious discharge per vagina - further decreased (↓↓) Dull pain in lower abdomen - further decreased (↓↓) No backache		Placebo
9 November 2019	No pain in lower abdomen Slight discharge per vagina		Placebo
21 December 2019	Slight discharge per vagina		Placebo
18 January 2020	Slight discharge per vagina No menstrual abnormality	USG of the whole abdomen suggested slightly bulky uterus [Figure 3]	<i>Calcarea carbonica</i> 200/2 doses
15 February 2020	No discharge per vagina		Placebo
7 March 2020	No other complaint		Placebo
16 March 2020	No other complaint	USG of whole abdomen suggest normal finding [Figure 4]	

The patient was followed for another 3 months, and no complication or relapse of the symptoms was noted during this period

Table 2: Assessment by modified Naranjo criteria score

Item	Yes	No	Not sure/N/A
Was there an improvement in the main symptom or condition, for which the homoeopathic medicine was prescribed?	+2		
Did the clinical improvement occur within a plausible time frame relative to the drug intake?	+1		
Was there an initial aggravation of symptom? (need to define in glossary)		0	
Did the effect encompass more than the main symptom or condition, i.e., were other symptoms ultimately improved or changed?	+1		
Did overall well-being improve? (suggest using validated scale)	+1		
Direction of cure: Did some symptoms improve in the opposite order of the development of symptoms of the disease?	+1		
Direction of cure: Did at least two of the following aspects apply to the order of improvement of symptoms: From organs of more importance to those of less importance From deeper to more superficial aspects of the individual From the top downwards			0
Did 'old symptoms' (defined as non-seasonal and non-cyclical symptoms that were previously thought to have resolved) reappear temporarily during the course of improvement?			0
Are there alternate causes (other than the medicine) that – with a high probability – could have caused the improvement? (consider known course of disease, other forms of treatment and other clinically relevant interventions)		+1	
Was the health improvement confirmed by any objective evidence? (e.g. laboratory test, clinical observation)	+2		
Did repeat dosing, if conducted, create similar clinical improvement?			0

N/A: Not available

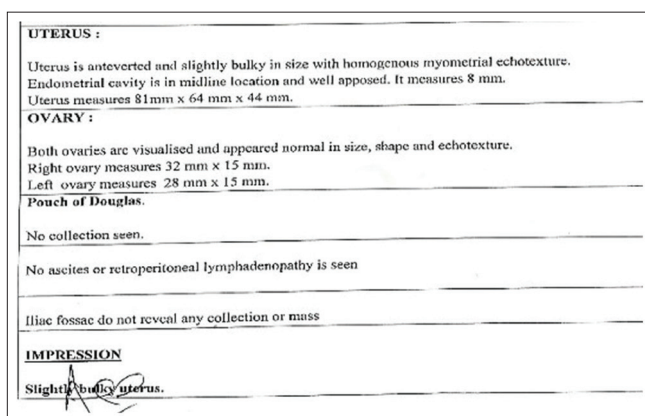


Figure 3: Ultrasonography of the whole abdomen on 17th January 2020

effected a permanent cure of disease of considerable or of long standing unless some homoeopathic agent was accidentally a chief ingredient in his prescription.^[10]

The patient already had a history of PID a year back, treated allopathically. She was taking paracetamol for fever and pain lower abdomen intermittently for 2 weeks, without medical prescription. However, after starting Homoeopathy, she was on homoeopathic treatment alone. No recurrence was noted for 3 months after stopping the homoeopathic treatment.

Here, with the help of single constitutional medicine in a minimum dose, the patient got relieved. As mentioned in §274, 'it is wrong to attempt to employ complex means when




Figure 4: Ultrasonography of the whole abdomen on 16th March 2020

simple means suffice' never think of giving as a remedy any but a single, simple medicinal substance.

This case report describes the effectiveness of constitutional homeopathic treatment in a case of PID. The remedy was selected on the basis of repertorisation together with consulting Homeopathic Materia Medica. A marked improvement of the symptoms was noted gradually in subsequent visits and marked resolution after the complete course of treatment. Monarc have been applied for the assessment of causal attribution of homeopathic medicine, which showed the positive role of constitutional medicine in the treatment of PID in a young woman.

Appropriate constitutional and anti-miasmatic medicines, when given in proper dosage are found effective in the treatment of disease. Selection of potency, dose and repetition must be strict accordance to the guideline laid down in *Organon of medicine*.

As per Dr Stuart Close, in the chapter General Pathology of Homeopathy, '*Individualization is the cardinal principle of a true pathology as well as of a true therapeutics*'.^[11]

CONCLUSION

The present case report evidently suggests the successful treatment of PID and restoration of well-being of patient with the help of constitutional homeopathic medicine. This case has highlighted the importance of holistic approach in the treatment considering the individuality of a patient for remedy selection, and not just disease symptoms. However, it would not be appropriate to generalise the usefulness of Homeopathy

in cases of PID on the basis of this single case report. Therefore, observational and randomised control trials are suggested to ascertain the result obtained in the present case report.

Consent

The written consent of the patient was obtained.

Declaration of patient consent

The authors certify that they have obtained all appropriate patient consent forms. In the form, the patient has given her consent for her images and other clinical information to be reported in the journal. The patient understands that her name and initials will not be published and due efforts will be made to conceal identity, but anonymity cannot be guaranteed.

Financial support and sponsorship

Nil.

Conflicts of interest

None declared.

REFERENCES

1. Dutta D, Konar H. DC Dutta's Textbook of Gynaecology. 6th ed. New Delhi: Jaypee Brothers; 2013. p. 127-33.
2. Berek Jonathan S. Berek and Novak's Gynaecology. 14th ed. Philadelphia: Lippincott Williams and Wilkins; 2007. p. 549-51.
3. Hoffman B, Schorge J, Bradshaw K, Halvorson L, Schaffer J, Corton M. Williams Gynaecology. 3rd ed. USA: McGraw Hill; 2016. p. 65-70.
4. Padubidri V, Daftary S. Howkins and Bourne Shaw's Textbook of Gynaecology. 16th ed.. Haryana, India: Elsevier; 2015. p. 177-86.
5. Malhotra N, Kumar P, Malhotra J, Bora N, Mittal P. Jeffcoate's Principles of Gynaecology. 8th ed. New Delhi: Jaypee Brothers Medical Publishers; 2014. p. 326.
6. Anita L, Prema D, Blany L. Effectiveness of homeopathic treatment in female infertility. *Reprod Med Int* 2018;1:8.
7. Cdc.gov. Pelvic Inflammatory Disease (PID)-2015 STD Treatment Guidelines; 2020 Available from: <https://www.cdc.gov/std/tg2015/pid.htm>. [Last accessed on 2020 Nov 26].
8. Shah J. Homopath Classic M.D. Repertory Version. 8.0. Mumbai: Mind Technologies Pvt. Ltd.; 2002.
9. Van Haselen RA. Homeopathic clinical case reports: Development of a supplement (HOM-CASE) to the CARE clinical case reporting guideline. *Complement Ther Med* 2016;25:78-85.
10. Hahnemann S. Organon of Medicine. 5th and 6th ed. Translated by Dudgeon RE. William Boericke 26th Impression. New Delhi: B. Jain; 2010.
11. Close S. The Genius of Homeopathy-Lectures and Essays on Homeopathic Philosophy with Word Index. 6th impression. New Delhi: B. Jain Publishers (P) Ltd; 2012.

पेल्विक इंप्लामेटरी रोग का उपचार होम्योपैथी औषधि, कैल्केरिया कार्बोनिका से किया गया: एक केस रिपोर्ट

परिचय: पेल्विक इंप्लामेटरी डिजीज़ (पीआईडी) ऊपरी जननांग तंत्र का एक पॉलीमाइक्रोबियल संक्रमण है जिसका चरित्र—चित्रण नैदानिक रूप से तीन लक्षणों और संकेतों; पेड़ू का दर्द, उपांगीय पीड़ा के साथ गर्भाशय ग्रीवा के हलचल और ज्वर द्वारा किया जाता है। परम्परागत उपचार ब्रॉड स्पेक्ट्रम एन्टीबायोटिक से किया जाता है। डब्ल्यूएचओ के अनुसार, वैकल्पिक औषधि; विशेषकर होम्योपैथी उपचार का दूसरा विकल्प है। चिकित्सा साहित्य में पीआईडी का केस रिपोर्ट नाममात्र का है। हमारा लक्ष्य एक ऐसे केस को रिपोर्ट करना था जिसमें पीआईडी से पीड़ित एक महिला को होम्योपैथी की संवैधानिक औषधि द्वारा उपचार किया गया। **केस का सारांश:** एक 29 वर्षीय महिला को दो सप्ताह से योनि से श्वेत स्राव, निचले पेट में लगातार हल्का दर्द, निचले कमर में दर्द, ज्वर और शिथिलता के लक्षणों के साथ प्रस्तुत किया गया। नैदानिक निष्कर्ष और सम्पूर्ण पेट के अल्ट्रासाउंड से पेल्विक इंप्लामेटरी रोग होने का सुझाव दिया गया। व्यक्तिगत होम्योपैथिक औषधि, कैल्केरिया कार्बोनिका को सेंटेंसिमल (सौवें भाग) पोटेंसी में दिया गया जिसने पीआईडी के उपचार में एक सकारात्मक भूमिका को प्रदर्शित किया। परिवर्तनों के संभावित आकस्मिक गुणधर्म का प्रदर्शन संशोधित नारांजो मापदंड द्वारा किया गया। इसके अतिरिक्त, पीआईडी के प्रकरणों में होम्योपैथी की प्रभावशालिता को सुनिश्चित करने के लिए एक यादच्छिक्त नियंत्रित परीक्षण का सुझाव दिया जाता है।

Maladie inflammatoire pelvienne traitée avec la médecine homéopathique Calcarea carbonica: un rapport de cas

Introduction: La maladie inflammatoire pelvienne (MIP) est une infection polymicrobienne du tractus génital supérieur caractérisée cliniquement par une triade de symptômes et de signes: douleur pelvienne, mouvement cervical avec sensibilité annexielle et fièvre. Le traitement conventionnel est avec des antibiotiques à large spectre. La médecine alternative, en particulier l'homéopathie, est le deuxième choix de thérapie selon l'OMS. Les rapports de cas de MIP dans la littérature médicale sont rares. Notre objectif est de rapporter un cas traité par médecine constitutionnelle homéopathique chez une femme souffrant de MIP. **Case summary:** A 29 years old lady presented with the symptoms of white discharge per vagina, constant dull pain in the lower abdomen, low backache, fever and lassitude for two weeks. Clinical findings and ultrasound of whole abdomen suggested pelvic inflammatory disease. Individualised homoeopathic medicine Calcarea carbonica was prescribed in centesimal potency which showed a positive role in the treatment of PID. Possible causal attribution of changes was depicted by Modified Naranjo Criteria. Furthermore, a randomised control trial is suggested to ascertain the efficacy of homoeopathy in the cases of PID. **Résumé du cas:** Une femme de 29 ans a présenté des symptômes d'écoulement blanc par vagin, une douleur sourde constante dans le bas de l'abdomen, des maux de dos, de la fièvre et une lassitude pendant deux semaines. Les résultats cliniques et l'échographie de l'abdomen entier suggéraient une maladie inflammatoire pelvienne. Le médicament homéopathique individualisé Calcarea carbonica a été prescrit en puissance centésimale qui a montré un rôle positif dans le traitement de la MIP. L'attribution causale possible des changements a été décrite par les critères de Naranjo modifiés. De plus, un essai contrôlé randomisé est suggéré pour vérifier l'efficacité de l'homéopathie dans les cas de MIP.

Enfermedad inflamatoria pélvica tratada con medicina homoeopática Calcarea carbonica: Un informe de caso

Introducción: La Enfermedad Inflamatoria Pélvica (PID) es una infección polimicrobiana del tracto genital superior caracterizada clínicamente por la tríada de síntomas y signos: dolor pélvico, movimiento cervical con sensibilidad adnexal y fiebre. El tratamiento convencional es con antibióticos de amplio espectro. La medicina alternativa, especialmente la homoeopatía, es la segunda opción de terapia según la OMS. Los informes de casos de PID en la literatura médica son escasos. Nuestro objetivo es reportar un caso tratado con medicina constitucional homoeopática en una mujer que sufre de PID. **Resumen del caso:** Una señora de 29 años presentó los síntomas de secreción blanca por vagina, dolor sordo constante en la parte inferior del abdomen, dolor de espalda bajo, fiebre y latitud durante dos semanas. Los hallazgos clínicos y el ultrasonido de abdomen entero sugirieron enfermedad inflamatoria pélvica. La medicina homoeopática individualizada Calcarea carbonica se prescribió en potencia centesimal que mostró un papel positivo en el tratamiento de la PID. La posible atribución causal de cambios fue representada por los Criterios Naranjo Modificados. Además, se sugiere un ensayo de control aleatorio para determinar la eficacia de la homoeopatía en los casos de PID.

Becken-Entzündliche Erkrankung, die behandelt wird mit Homöopathischen Medikament Calcium carbonicum: Ein Fallbericht

Einleitung: Entzündliche Erkrankungen des Beckens (PID) ist ein polymicrobial Infektion der oberen Genitaltrakt zeichnet sich klinisch durch die Trias von Symptomen und Zeichen: Becken-Schmerz, HWS-Bewegung mit adnexeingriffe machen den Hauptanteil Zärtlichkeit und Fieber. Die konventionelle Behandlung mit Breitbandantibiotika. Die alternative Medizin, insbesondere der Homöopathie ist die zweite Wahl der Therapie, wie pro DIE. Fall-Berichte der PID in der medizinischen Literatur sind spärlich. Wollen wir zu berichten über einen Fall behandelt mit homöopathischen konstitutionellen Medizin in eine Frau leidet PID. **Zusammenfassung:** Eine 29Jahre alte Frau präsentiert mit Symptomen von weißen Ausfluss pro vagina, Konstante, dumpfer Schmerz im unteren abdomen, niedrigen Rückenschmerzen, Fieber und Mattigkeit für zwei Wochen. Klinische Befunde und Ultraschall des ganzen Bauches vorgeschlagen, Becken-entzündliche Krankheit. Individualisierte Homöopathische Medizin Calcium carbonicum verordnet wurde in zentesimale Potenz, die zeigten, eine positive Rolle in der Behandlung von PID. Mögliche kausale attribution der Veränderungen wurde dargestellt, die durch Veränderte Naranjo Kriterien. Darüber hinaus eine randomisierte kontrollierte Studie vorgeschlagen, zu prüfen, die Wirksamkeit der Homöopathie in den Fällen der PID.

佩尔维克炎症病治疗同源性药物卡尔卡雷卡：病例报告

介绍：Pelvic 炎症性疾病（PID）是上生殖道的多微生物感染，临床上由三重症状和体征组成：骨盆疼痛、颈椎运动、前肢柔情和发烧。常规治疗是广谱抗生素。替代医学，特别是同性恋病是世卫组织的第二选择疗法。医学文献中关于PID的病例报告很少。我们的目标是报告一个患有PID的妇女用同源性宪法医学治疗的病例。案例摘要：一位29岁的女士每个阴道出现白色分泌物症状，下腹部持续沉闷疼痛，腰酸低，发烧和精神不振两周。临床结果及全腹部超声显示盆腔炎。个体同病药物卡尔卡里亚碳化药以百分效力开处方，在PID的治疗中显示出积极的作用。修改的纳兰霍标准描述了变化的可能因果归因。此外，建议进行随机对照试验，以确定同性恋病在PID病例中的疗效。