

Homoeopathic treatment of chronic urticaria – A case series

Padmalaya Rath, Parul

Dr. D.P. Rastogi Central Research Institute of Homoeopathy, Under CCRH, Noida, Uttar Pradesh, India

Abstract

Introduction: Urticaria is a kind of skin complaint with red, raised and itchy bumps. Urticaria frequently occurs after an infection or as a result of an allergic response to some medication, insect bites or food. Psychological stress, exposure to cold or vibration may also trigger urticaria. Urticaria occurs with a lifetime prevalence of around 20%. In around 30% patients of urticaria, attacks often recur for months or years. **Cases summary:** This is a case series of five patients suffering from chronic urticaria having erythematous lesions, intense itching, redness and swelling treated at the Dermatology outpatient department of Dr D. P. Rastogi Central Research Institute for Homoeopathy, Noida, Uttar Pradesh, India. The patients were prescribed indicated constitutional Homoeopathic medicines. Changes in haematological and serological tests, Measure Yourself Medical Outcome Profile 2 and Urticaria Activity Score summed over 7 days at baseline and at the end of treatment showed reasonable improvement in disease as well as in the quality of life. Homoeopathic medicines such as *Apis mellifica*, *Calcarea carbonica*, *Rumex crispus*, *Pulsatilla* and *Histamine* were found useful.

Keywords: *Apis mellifica*, *Calcarea carbonica*, *Chronic urticaria*, *Histamine*, Homoeopathy, *Pulsatilla*, *Rumex crispus*, Urticaria

INTRODUCTION

Chronic urticaria is defined as the presence of urticaria for a period exceeding 6 weeks, assuming symptoms for most days of the week.^[1,2] Urticaria is characterised by dermal oedema and erythema, also known as hives. Hive lesions typically last <24 h and are usually pruritic.^[3] Urticaria is a common clinical condition presenting with wheals, angioedema or both. Urticaria has a complex pathogenesis, along with a high disease burden, a significant impact on quality of life, and high healthcare costs.^[4] Acute urticaria can develop suddenly and will last <6 weeks.^[5] About one in six people will have acute hives at one point in their life.^[5] Chronic urticaria can develop suddenly and will persist >6 weeks.^[5] Twenty percent of people with chronic urticaria report still having problems 10 years after its onset.^[6]

Over half of all cases of chronic urticaria are thought to occur by an autoimmune mechanism, primarily autoantibodies against the high-affinity immunoglobulin E (IgE) receptor.^[7]

Around a quarter of people with acute urticaria and half of the people with chronic urticaria also develop angioedema, which is localised and self-limiting oedema of the subcutaneous and submucosal tissue, due to a temporary increase in vascular permeability caused by the release of vasoactive mediator.^[8]

Chronic urticaria can be upsetting and negatively impact a person's mood and quality of life.^[9]

Homoeopathic treatment for urticaria is more beneficial because with conventional medicines, there are chances of long-term dependency on anti-allergic medicines. While the Homoeopathic treatment involves analysing complete and detailed information from the patient to select the right constitutional medicine for providing marked improvement with long-term relief.

To assess the clinical results, The Measure Yourself Medical Outcome Profile (MYMOP) is used which is a 'patient-centred' outcome scale where patients are asked to nominate one or two symptoms (physical or mental) of a specific problem they need assistance with and consider the severity of these symptoms over the last week. The third item asks the patient to list an activity (such as walking) that they have had difficulty completing due to their problem. The fourth item asks patients

***Address for correspondence:** Dr. Padmalaya Rath, Dr. D. P. Rastogi Central Research Institute of Homoeopathy, Under Central Council for Research in Homoeopathy, A1/1, Sector-24, Noida, Uttar Pradesh, India.
E-mail: drpadmalaya@gmail.com

Received: 11.02.2020; **Accepted:** 03.12.2020; **Published:** 29.12.2020

Access this article online

Quick Response Code:



Website:
www.ijrh.org

DOI:
10.4103/ijrh.ijrh_9_20

This is an open access journal, and articles are distributed under the terms of the Creative Commons Attribution-NonCommercial-ShareAlike 4.0 License, which allows others to remix, tweak, and build upon the work non-commercially, as long as appropriate credit is given and the new creations are licensed under the identical terms.

For reprints contact: WKHLRPMedknow_reprints@wolterskluwer.com

How to cite this article: Rath P, Parul. Homoeopathic treatment of chronic urticaria – A case series. Indian J Res Homoeopathy 2020;14:267-78.

to rate their general well-being over the last week. This scale has been used to analyse the outcomes in the presented cases.

METHODS

All the five cases reported here suffered from urticarial rashes for which Urticaria Activity Score summed over 7 days (UAS7)^[10] and MYMOP2^[11] were noted at baseline, at every follow-up and at the end of treatment. IgE was tested in every case at baseline.

Five cases of urticaria were treated with homoeopathic medicines selected on the basis of individualisation, considering location, sensation, modalities (i.e., aggravating and ameliorating factors) and concomitants of the symptoms in each case.

Consent was taken from all the patients for publication.

CASE REPORTS

Case 1

A 21-year-old female presented with eruptions over the whole body with swelling of the upper lip, eye and face, for 3 years [Figure 1 shows the presentation at the time of consultation].

- Three years ago, she gradually developed itching and redness of the whole body with wheals on the knee, face and chest with 4–5 such paroxysms in a week. Eruptions and itching aggravated at night, cold weather and sunlight
- She had a tendency to catch cold and suffered from recurrent tonsillitis in the past. She had typhoid 8 years back
- There was no history of chronic rhinitis, asthma and hay fever
- She was having irregular menses for 7 years
- In her family, grandmother had diabetes mellitus and father and mother had hypothyroidism
- She had desire for egg.

This is a case of chronic urticaria having acute exacerbation with angioedema.

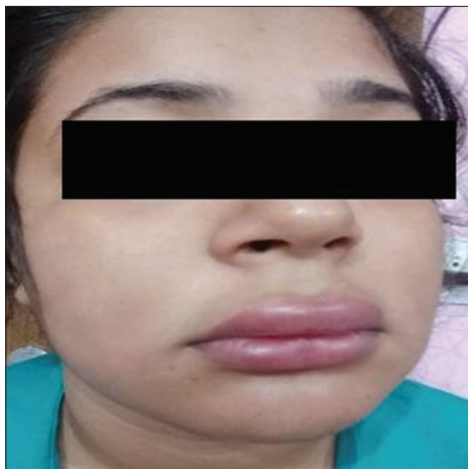

Figure 1: Initial presentation with swollen lips (Case 1)

Physical examination and clinical findings

1. The patient was obese and flabby having a body mass index of 28.6 (height – 1.62 m and weight – 75 kg)
2. Type of lesion – Wheals and oedema
3. Colour of lesion – Reddish
4. Margin – Ill defined
5. Shape – Irregular
6. Number – Multiple
7. Size – 5–6 mm in diameter
8. Site of lesion – Face, knee, chest, upper lip (swollen) and eyes
9. Serum IgE – 354.3 IU/ml

UAS at baseline was 30 and at the end of treatment was 6.

MYMOP2 score at baseline was 5.75, and at the end of treatment was 1 [Table 1].

Basis of prescription

On repertorial analysis [Figure 2], *Calcarea carbonica* was found to be the most similar medicine to the case and also scored highest, that is 17/7. She was obese and flabby with irregular menses and a history of repeated tonsillitis and desire for eggs led to the selection of *Calcarea carbonica*.

Prescription on 5 October 2018

Calcarea carbonica was prescribed in fifty millesimal scale in increasing potency and was advised to be taken in distilled water, twice daily for 20 days.

Follow-ups and observation are represented in Table 2.

Case 2

A 28-year-old female presented with erythematous, oedematous, pruritic lesions all over the body, more marked on face, causing angioedema, with unexpected puffiness of skin with red discoloration, which blanched^[12] [Figure 3].

- She reported of gradual development of redness and burning sensation on the face and some part of the arms and legs daily, for the last 7 years. Various parts of the body had a sensation of heat and burning, which got ameliorated by scratching
- Her complaints usually got aggravated in summers from heat and sunlight and itching got better by pressure or rubbing hard and cold exposure

Remedy Name	Calc	Sulph	Sep	Sil	Apis	Ars	Hep	Nit-ac	Lach
Calc	17	16	13	13	13	13	12	12	11
Sulph	7	7	7	7	5	5	5	5	7
Kingdom									
(Kent) [Face]Eruptions (see skin)Urticaria: (24)	2	3	2	1	3	3	2		1
(Kent) [Face]Swelling Lips: (78)	2	2	3	2	3	2	1	3	1
(Kent) [Skin]Eruptions/Urticaria: (102)	3	3	2	1	3	3	3	1	1
(Kent) [Throat]Inflammation/Tonsils: (97)		2	1	3	2	2	3	3	3
(Kent) [Generalities]Heat/Struck off: (108)	3	2	2	3		3	3	3	2
(Kent) [Stomach]Desires/Eggs: (4)	2								
(Kent) [Sexualia Female]Menses/Irregular: (61)	2	2	2	2	2			2	2
(Kent) [Generalities]Obesity: (59)	3	2	1	1					1

Figure 2: Repertorisation of Case 1

- She had a past history of dengue in 2017 and abortion at 7 months of gestation in 2018.
- Her menses were scanty and lasted for 2 days
- Her father had diabetes mellitus
- She was sensitive to slightest trifles, was impatient and was restless
- She had desire for salty things
- She has been taking anti-allergic medicines, on and off, for the last 7 years.

Physical examination and clinical findings

- The patient was of average built and flabby, having a body mass index of 25.51 (height –1.40 m and weight –50 kg)
- Type of lesion – Erythematous wheals with oedema
- Colour of lesion – Brick red
- Margin – Ill defined
- Shape – Irregular

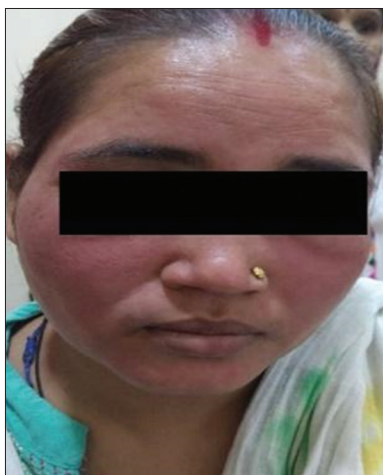

Figure 3: Initial presentation with swelling on face (Case 2)

- Number – Multiple
- Size – Varied from 2 mm to 8 cm
- Site of the lesion – Arms, legs, face – both cheeks
- Serum IgE – 166.90 IU/ml.

UAS at baseline was 39, and at the end of treatment, it was 2.

MYMOP2 score at baseline was 6 and 0.75 at the end of treatment [Table 1].

Basis of prescription

On repertorisation [Figure 4], *Sulphur* scored highest marks, that is 32/13. However, after consulting *Lotus Materia Medica*, ‘Histamine’ was prescribed after considering physical generals, modalities and particulars of the case, that is sensation of heat and burning on the

Remedy	32	25	24	24	23
Totally	32	25	24	24	23
Symptoms Covered	13	10	11	11	10
Kingdom	1	1	1	1	1
[Kent] [Stomach] [DESIRE: Salt things: (30)	1		2		
[Kent] [Mind] [RESTLESSNESS, NERVOUSNESS: (48)	3	3	3	3	3
[Kent] [Mind] [IMPATIENCE: (82)	3	3	2	2	2
[Kent] [Mind] [BROODING (SEE ANXIETY, SADNESS): (26)	1				
[Complete] [Face] [DISCOLORATION: Cheek: (182)	3	4	3	3	4
[Complete] [Face] [ITCHING: Warm, on becoming: (2)					1
[Kent] [Skin] [DISCOLORATION: Red: (87)	2	1	1	2	2
[Kent] [Skin] [DISCOLORATION: Red Spots: Burnt as if: (11)					
[Kent] [Sensitila female] [ABORTION: Suppressed grief: Tendency to: (26)	2	2	2	1	1
[Kent] [Sensitila female] [MENSES: Scanty: (101)	3	3	1	3	2
[Kent] [Skin] [ERUPTIONS: Urticaria: (102)	3	2	3	2	2
[Kent] [Skin] [ITCHING: Burning: (120)	3	2	2	3	3
[Kent] [Skin] [ERUPTIONS: Itching: (109)	3	3	2	2	2
[Kent] [Skin] [ITCHING: Scratching: Ache: (84)	2	2	3		
[Kent] [Skin] [ITCHING: Warm: On becoming: (22)	3			2	2

Figure 4: Repertorisation of Case 2

Table 1: Improvement status

Base line	Dose tapering of anti allergic medications in the six follow ups						Uas7 score in 6 follow ups						IgE LEVELS	MYMOP2 score in 6 follow ups						Modified naranjo		
	1 st	2 nd	3 rd	4 th	5 th	6 th	Base line	1 st	2 nd	3 rd	4 th	5 th		6 th	Before Treatment	Base line	1 st	2 nd	3 rd		4 th	5 th
Twice daily	Twice daily	Once daily	Twice weekly	Twice weekly	Once weekly	Nil	30	28	16	11	11	10	6	354.31 U/ml	5.75	4.5	3	2	2.25	1.75	1	11
Thrice daily	Twice daily	Once daily	Once daily	Nil	Nil	Nil	39	34	29	21	18	13	2	166.90 IU/ml	6	5.5	4.25	4	3.25	2	0.75	10
Once daily	Twice weekly	Twice weekly	Nil	-	-	-	33	22	10	0	-	-	-	150 k UA/L	6	2.5	1.25	0.25	-	-	-	9
Twice daily	Once daily	Twice weekly	Nil	Once weekly	Nil	Nil	28	16	9	6	5	3	3	369 k UA/L	5.75	4	3	2.75	1.75	1	0.75	9
Thrice daily	Thrice daily	Twice daily	Once daily	Once daily	Nil	-	42	38	36	19	18	16	-	5989 k UA/L	6	5.75	5.25	3.5	3.5	2.75	-	6

head and face, urticaria and redness of face.^[13] Certain areas of the skin had a sensation of heat and burning; hyperaesthesia; red itching papules and amelioration by scratching, pressure or rubbing hard. The patient was sensitive to slightest trifles, was impatient and was restless. *Histamine hydrochloricum* is a capillary vessel dilator and an arteriole vessel constrictor.^[13]

Prescription on 8 May 2019

Histamine 30 was prescribed, and the patient was advised to take medicine thrice daily for 3 days, followed by placebo for

the next 7 days. After 10 days, the patient reported with mild improvement in complaints.

Follow-ups and observation are represented in Table 3.

Case 3

A 41-year-old male presented with itchy wheals of different sizes all over the body, more marked on the back, abdomen and arms [Figure 5].

- Six months back, the complaint started with intense itching over the back, with longitudinal wheals of variable size. Gradually, it spread to the skin all over the body, more marked on the abdomen and arms with redness, burning and swelling. He was taking anti-allergic medication daily for the complaints with mild relief, but it occurred repeatedly

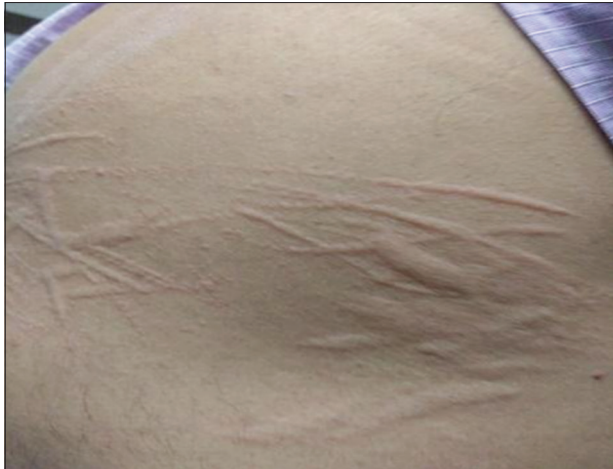

Figure 5: Initial presentation with lesion on the upper back (Case 3)

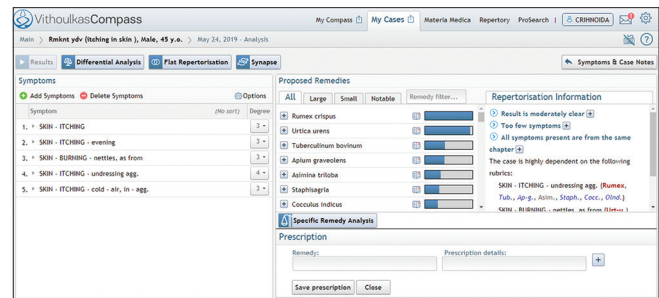


Figure 6: Repertorisation of Case 3

Table 2: Prescription table of Case 1											
Follow up	Date	Symptoms	Prescription	UAS7			MYMOP2				
				Wheals (D1-D7)	Pruritis (D1-D7)	Total	Swelling	Redness and itching	Activity	General well being	Total
1	17-11-2018	wheals appeared only 7-8 times in last 15 days and much improvement in itching.	Calc carb0/3/bd/10 days; Calc carb0/4/bd/10 days	17	11	28	5	4	5	4	4.5
2	14-12-2018	frequency of wheals has reduced markedly, 5 episodes in last 15 days with no itching.	Calc carb0/5/bd/10 days; Calc carb0/6/bd/10 days	12	4	16	4	2	3	3	3
3	25-01-2019	no wheal appeared since last month, only slight itching.	Calc carb0/7/bd/10 days; Calc carb0/8/bd/10 days	1	10	11	1	3	2	2	2
4	16-02-2019	distribution of wheals was in small area of leg and intensity has also reduced, only slight itching.	Calccarb0/9/bd/10 days; Calccarb0/10/bd/10 days	4	7	11	2	3	2	2	2.25
5	25-03-2019	no itching, wheals appeared only twice in last 15 days.	Calccarb0/11/bd/10 days; Calccarb0/12/bd/10 days	8	2	10	2	1	2	2	1.75
6	20-04-2019	no itching, no wheals since 2 months.	Calccarb0/13/bd/10 days; Calccarb0/14/bd/10 days	1	5	6	1	1	1	1	1

- Itching aggravated in the evening and while undressing, when exposed to cold air
- He had a past history of renal calculi 9 years back, relieved with allopathic medicine.
- In his family, his mother also had urticaria
- His sleep was disturbed due to intense itching
- He had desire for sour and salty things.

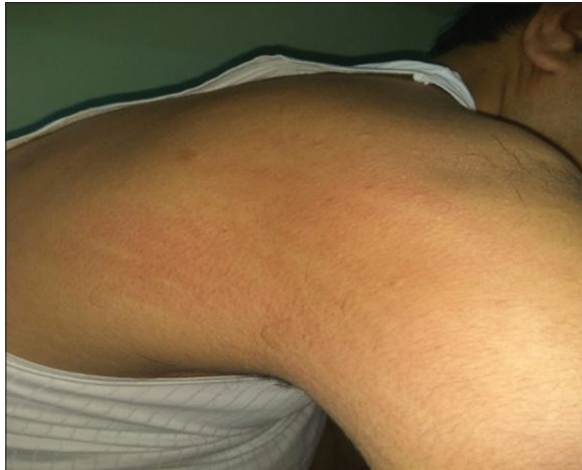

Figure 7: Initial presentation (Case 4)

Physical examination and clinical findings

- The patient had average-built, fair complexion
- Type of lesions – Wheals with mild swelling
- Colour of lesions – Reddish discolouration
- Margins – Well defined
- Shape – Linear striae of variable sizes
- Number – Multiple
- Size – Vary from 5 to 9 mm in length
- Site of lesion – Back, abdomen and arms
- Serum IgE – 150 kUA/L.

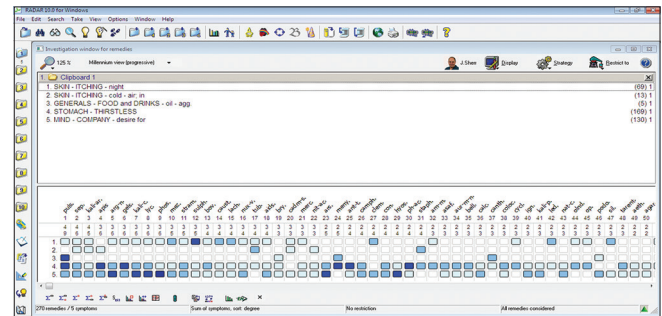


Figure 8: Repertorisation of Case 4

Follow up	Date	Symptoms	Prescription	UAS7			MYMOP2				
				Wheals (D1-D7)	Pruritis (D1-D7)	Total	Itching	Redness and Swelling	Activity	General well being	Total
1	16-05-2019	mild improvement in itching, but burning and redness was same.	Histamine30/ bd/5 days; SI30/bd/10 days	18	16	34	5	6	6	5	5.5
2	31-05-2019	mild improvement in itching, burning and redness was also slightly reduced.	Histamine30/ bd/7 days; SI30/ bd/10 days	17	12	29	4	5	4	4	4.25
3	17-06-2019	itching in eyes and face was much better, no itching in arms and legs, redness has also reduced. But slight burning was still there after scratching.	Histamine30/ bd/3 days; SI30/ bd/10 days	12	9	21	3	5	4	4	4
4	02-07-2019	much improvement in itching, distribution of wheals were in less area. No burning after scratching.	SI30/ bd/15 days	12	6	18	2	4	4	3	3.25
5	18-07-2019	itching decreased by 90%, redness was also reduced markedly.	SI30/ bd/15 days	10	3	13	1	3	2	2	2
6	02-08-2019	No redness, no burning and mild itching. 95% improvement in pruritic lesions all over body.	SI30/ bd/15 days	2	0	2	0	1	1	1	0.75

Table 4: Prescription table of Case 3

Follow up	Date	Symptoms	Prescription	UAS7			MYMOP2				
				Wheals (D1-D7)	Pruritis (D1-D7)	Total	Redness and swelling	Itching	Activity	General well being	Total
1	01-04-2019	itching has reduced by 50%, frequency of wheals decreased by 30%, patient was taking anti allergic medicines twice in a week.	Rume×30/tds/7 days	13	9	22	4	1	2	3	2.5
2	09-04-2019	70% improvement in itching, no wheals appeared, didn't took anti allergic medicines	Rume×30/tds/7 days	6	4	10	2	1	1	1	1.25
3	07-05-2019	no rashes with 100% improvement in itching.	SI30/tds/7 days	0	0	0	1	0	0	0	0.25

Table 5: Prescription table of Case 4

Follow up	Date	Symptoms	Prescription	UAS7			MYMOP2				
				Wheals (D1-D7)	Pruritis (D1-D7)	Total	Itching	Redness and Swelling	Activity	General well being	Total
1	18-04-2019	itching and wheals has reduced by 40%, patient took anti allergic medicines once daily.	Pulsatilla30/bd/5 days; SI30/bd/15 days	7	9	16	5	5	5	5	4
2	25-04-2019	Improvement in itching with red papules, mild wheals appeared, took anti allergic medicines twice weekly	Pulsatilla30/bd/3 days; SI30/bd/15 days	2	7	9	4	1	4	3	3
3	09-05-2019	75% improvement in itching, occurred only 2-3 times and wheals occurred thrice in last 15 days.	Pulsatilla200/bd/3 days; SI30/bd/15 days	3	3	6	3	2	3	3	2.75
4	06-06-2019	80% improvement in itching, no wheals appeared.	Pulsatilla200/od/3 days; SI30/bd/15 days	2	3	5	2	1	2	2	1.75
5	21-06-2019	no eruptions, no wheals, occasional itching only on sweating.	Pulsatilla200/od/3 days; SI30/bd/15 days	0	3	3	1	1	1	1	1
6	19-07-2019	no eruptions, no wheals occasional itching on cold exposure.	Pulsatilla1M/od/1 day; SI30/bd/15 days	0	3	3	1	1	0	1	0.75

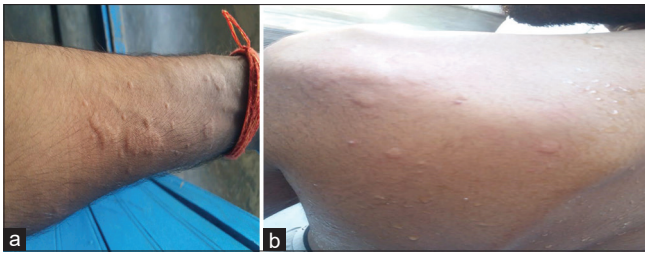


Figure 9: Initial presentation with lesions on the forearm (a) and back (b) (Case 5)

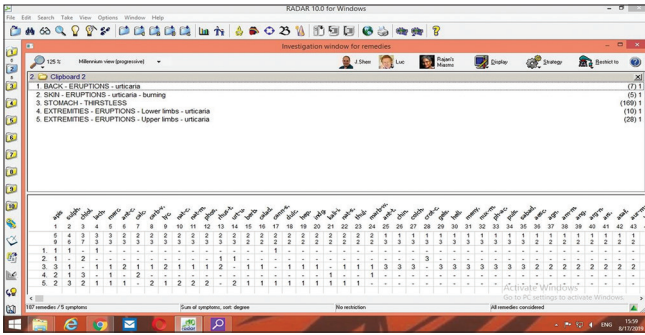


Figure 10: Repertorisation of Case 5

UAS at baseline – 33 and UAS at the end of treatment – 7.

MYMOP2 score at baseline – 6 and MYMOP2 Score at the end of treatment – 0.25 [Table 1].

Basis of prescription

On repertorial analysis by Vithoulkas Compass [Figure 6], *Rumex crispus* scored the highest marks and covered maximum rubrics. It is one of the leading remedies used for intense itching of urticaria as well. Modalities and particular generals were well covered, that is itching aggravates in the evening and while undressing, uncovering^[14] when exposed to cold air by this remedy. Hence, the most appropriate remedy for this case was *Rumex crispus*.

Prescription on 8 March 2019

Rumex 30 was prescribed and was advised to take the medicine thrice daily for 5 days, followed by *saccharum lactis 30* twice daily for 10 days.

Follow-ups and observations are represented in Table 4.

Case 4

A 40-year-old male presented with itching over the whole body with raised erythematous lesions of variable size [Figure 7].

- Nine months back, he developed intense itching in the whole body with mild swelling, which got aggravated with exposure to cold air, at night and change of weather for which he was taking anti-allergic medicines twice daily
- Thermal reaction of the patient was hot
- He had desire for salty things
- The patient was thirstless
- He had intolerance for oily food which was causing

flatulence

- The patient desired for company all times.

Physical examination and clinical findings

- The patient was robust and had a body mass index of 26.2 (height – 1.80 m and weight – 85 kg)
- Type of lesion – Erythematous wheals with mild swelling
- Colour of lesion – Reddish
- Margin – Ill defined
- Shape – Irregular and linear
- Number – Multiple
- Size – Vary from 8 to 10 mm in length
- Site of lesion – Whole body especially arms
- Serum IgE – 369 kUA/L

UAS at baseline – 28 and UAS at the end of treatment – 4.

MYMOP2 score at baseline – 5.75; MYMOP2 at the end of treatment – 0.75 [Table 1].

Basis of prescription

On repertorial analysis [Figure 8], '*Pulsatilla*' scored highest marks, that is 9/4. Modalities and general symptoms, that is

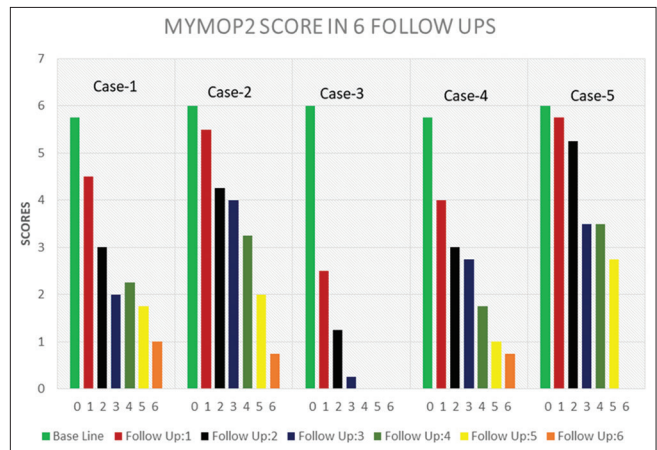


Figure 11: Improvement in MYMOP2 score in follow-ups

thirstlessness, intolerance for oily food and desire for company, were well covered by this remedy.^[15]

Prescription on 4 April 2019

Pulsatilla 30 was prescribed and was advised to take the medicine twice daily for 5 days, followed by placebo twice daily for 10 days.

Follow-ups and observation are represented in Table 5.

Case 5

A 22-years-old male presented with itchy, swollen and raised erythematous lesions of variable size on different parts of the body, more marked on the back, legs and arms [Figure 9a and b].

- Nine years ago, he developed itching all over the body with red streaks and burning sensation, which get

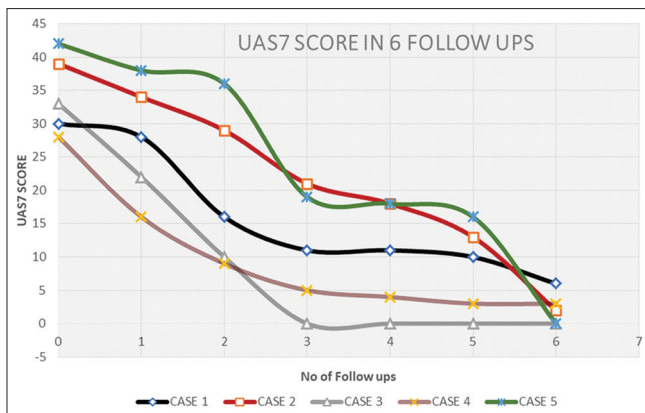


Figure 12: Improvement in UAS7 score in follow-ups

ameliorated by cold bathing. Wheals burnt and itched intolerably at night, with stinging pains

- He was taking anti-allergic medicines daily for the last 9 years
- The patient was thirstless
- He had desire for milk
- Thermally, the patient was hot.

Physical examination and clinical findings

- Type of lesion – Wheals
- Colour of lesion – Red
- Margin – Ill defined
- Shape – Irregular
- Number – Multiple
- Size – Vary from 3 to 20 mm in diameter
- Site of lesion – Face, forearms, upper back and legs
- Serum IgE – 5989 kUA/L.

UAS at baseline – 42 and UAS at the end of treatment – 16.

MYMOP2 score at baseline – 6, MYMOP2 at end of treatment – 2.75 [Table 1].

This is a case of chronic urticaria having acute exacerbation at the time of reporting with no history of hay fever, asthma or chronic rhinitis.

Basis of prescription

On repertorial analysis [Figure 10], '*Apis mellifica*' has scored the highest marks, that is, 9/5. Physical generals, particulars and modalities, that is red streaks and burning sensation, got ameliorated by cold bathing, thirstlessness and stinging pains,^[14] which led to selection of *Apis mellifica*. Hence, the most appropriate medicine for this case was *Apis mellifica*.

Prescription on 16 May 2019

Apis mellifica was prescribed in fifty millesimal scale in increasing potency and was advised to take with aqua dist. twice daily for 20 days.

Follow-ups and observation are shown in Table 6.

DISCUSSION

In the above cases, homoeopathic medicines were given on the basis of individualisation, and were found to be successful in the treatment of chronic urticaria, leading to removal of signs and symptoms. These five patients were on anti-allergic medicines, along with homoeopathic treatment. Gradually, their quality of life improved, with reduction in the frequency of taking anti-allergic medicines. UAS and MYMOP2 scores were recorded in each follow-up for measuring clinical change associated with the course of homoeopathic treatment. Under MYMOP2 scoring, for each patient, symptoms considered were itching, redness, swelling, physical activity and general feeling of well-being. For every follow-up, the minimum clinically important change in score after intervention should be between 0.5 and 1.0, any change >1.0 can be considered clinically significant.^[11] In this case series, each patient had shown reduction in score between 1.25 and 1.50 at every follow-up [Table 1 and Figure 11]. IgE is an Ig that plays a central role in chronic inflammatory allergic urticaria, so serum IgE levels were also recorded before treatment. IgE is believed to be one of the major mediators of hypersensitivity reaction such as urticaria and were found significantly raised in these patients. Limitation in these cases was that serum IgE levels were not recorded after treatment because patients were reluctant as the test was expensive; earlier, it was done before treatment because patients thought it would help in the diagnosis and line of treatment would be in the right direction. Modified Naranjo Criterion^[16] was used for analysing any adverse effect and for validating the symptoms after medicine has acted.

Cases 1 and 2, having chronic urticaria with angioedema, showed marked improvement in the symptoms of urticaria, with no adverse effects. On comparing the duration of illness with outcomes, in cases 1 and 5, it was observed that because these cases were treated with fifty millesimal potencies, the response of treatment was fast, as we could avoid aggravation by minimising the quantity of the medicine. Case 2 improved with homoeopathic medicine *Histamine*, which is conventionally a capillary vessel dilator and an arteriole vessel constrictor. *Histamine* is normally used in the form of histamine bi-chlorhydrate, which serves as the stock for homoeopathic preparations. Moreover, individualised remedy has always been proved effective, as in case 1 and case 4, implying the benefit of holistic approach of homoeopathy, improving not only the symptoms, but also the overall quality of life of patients. Moreover, cases 1, 2 and 4 showed UAS7 band^[17] with a range from 1 to 6, that is well-controlled urticaria, which indicates a good response to treatment [Table 1 and Figure 12]. Case 3 improved with *Rumex crispus*, which is found to be effective in treating urticaria, apart from upper respiratory tract allergies. Case 3 showed UAS7 band:^[17] 0, that is free of itch and hives, that indicates cure [Table 1 and Figure 12], and case 5 showed UAS7 band^[17] with a range from 16 to 27, that is moderate activity urticaria, indicating low response [Table 1 and Figure 12]. A study by Sharma *et al.* showed that patient-related outcomes improve the quality of life of patients with chronic urticaria by reducing

Table 6: Prescription table of Case 5

Follow up	Date	Symptoms	Prescription	UAS7			MYMOP2				
				Wheals (D1-D7)	Pruritis (D1-D7)	Total	Redness and Swelling	Itching	Activity	General well being	Total
1	06-06-2019	slight improvement in itching, but intensity and distribution of wheals were same. Patient was taking anti-allergic medicines thrice daily.	Apis 0/3/bd/10 days; Apis 0/4/bd/10 days	21	17	38	6	5	6	6	5.75
2	28-06-2019	much improvement in itching, intensity of wheals were same.	Apis 0/5/bd/10 days; Apis 0/6/bd/10 days	21	15	36	6	4	5	6	5.25
3	19-07-2019	intensity and distribution of wheals were in less area, marked improvement in itching. Still on anti-allergic medicines but dosage has reduced to once daily.	Apis 0/7/bd/10 days; Apis 0/8/bd/10 days	13	6	19	4	2	4	4	3.5
4	09-08-2019	intensity of wheals has reduced, occurred only thrice in last 15 days.	Apis 0/9/bd/10 days; Apis 0/10/bd/10 days	9	9	18	3	3	4	3	3.5
5	23-08-2019	Marked improvement in wheals and itching. Didn't take anti- allergic medicines for last 4 days. [See Figure 10 (a) and (b)]	Apis 0/11/bd/10 days; Apis 0/12/bd/10 days	8	8	16	3	2	3	3	2.75

pruritus, intensity of wheals and swelling.^[18] The findings of this case series also corroborate with that of the said study. Another case report^[19] also showed marked improvement in urticaria with *Apis mellifica*, which is consistent with our case series.

CONCLUSION

Homoeopathic medicines reduce both the intensity and frequency of attacks of urticaria and help in improving the quality of life of patients. Individualised homoeopathic treatment is associated with significant alleviation of urticaria symptoms, thus also leading to reduction in the use of conventional anti-allergic medication.

Declaration of patient consent

The authors certify that they have obtained all appropriate patient consent forms. In the form, the patients have given their consent for their images and other clinical information to be reported in the journal. The patients understand that their names and initials will not be published and due efforts

will be made to conceal their identity, but anonymity cannot be guaranteed.

Financial support and sponsorship

Nil.

Conflicts of interest

None declared.

REFERENCES

- Saini SS, Kaplan AP. Chronic spontaneous urticaria: The devil's itch. *J Allergy Clin Immunol Pract* 2018;6:1097-106.
- Fine LM, Bernstein JA. Guideline of chronic urticaria beyond. *Allergy Asthma Immunol Res* 2016;8:396-403.
- Lee EE, Maibach HI. Treatment of urticaria. *Am J Clin Dermatol* 2001;2:27-32.
- Antia C, Baquerizo K, Korman A, Bernstein JA, Alikhan A. Urticaria: A comprehensive review: Epidemiology, diagnosis, and work-up. *J Am Acad Dermatol* 2018;79:599-614.
- Harding M. Hives (Urticaria). Patient. Available from: <https://patient.info/skin-conditions/hives-inducible-urticaria>. [Last accessed on 2019 Apr 20].
- Katellaris C. Treatment of urticaria. *Aust Prescr* 2001;24:124-6.

7. Fraser K, Robertson L. Chronic urticaria and autoimmunity. *Skin Therapy Lett* 2013;18:5-9.
8. Cicardi M, Aberer W, Banerji A, Bas M, Bernstein JA, Bork K, *et al.* Classification, diagnosis, and approach to treatment for angioedema: Consensus report from the hereditary angioedema international working group. *Allergy* 2014;69:602-16.
9. Yadav S, Bajaj AK. Management of difficult urticaria. *Indian J Dermatol* 2009;54:275-9.
10. Godse KV. Urticaria meter. *Indian J Dermatol* 2012;57:410-1.
11. Lima PM, Brito RF, Farias RT, Paiva GS, Barbosa FT, Rodrigues CF, *et al.* Cultural adaptation and reproducibility of the Measure Yourself Medical Outcome Profile (MYMOP2). *Fisioterapiaem Movimento* 2016;29:251-67.
12. Kaplan A, Greaves MW. *Urticaria and Angioedema*. Florida: CRC Press; 2009.
13. Murphy R. *Lotus Materia Medica*. 3rd ed. New Delhi: B. Jain Publishers Pvt. Ltd.; 2003.
14. Allen HC. *Keynotes Rearranged and Classified with Leading Remedies of the Materia Medica and Bowel Nosodes*. 10th ed. New Delhi: B. Jain Publishers Pvt. Ltd.; 1999. p. 33, 262, 263.
15. Boericke W. *New Manual of Homoeopathic Materia Medica with Repertory*. Third Revised and Augmented Edition. New Delhi: B. Jain Publishers Pvt. Ltd.; 2007. p. 536-8.
16. Lamba CD, Gupta VK, van Haselen R, Rutten L, Mahajan N, Molla AM, *et al.* Evaluation of the modified naranjo criteria for assessing causal attribution of clinical outcome to homeopathic intervention as presented in case reports. *Homeopathy* 2020;109:191-7.
17. Hollis K, Proctor C, McBride D, Balp MM, McLeod L, Hunter S, *et al.* Comparison of Urticaria Activity Score over 7 days (UAS7) values obtained from once-daily and twice-daily versions: Results from the ASSURE-CSU study. *Am J Clin Dermatol* 2018;19:267-74.
18. Sharma R, Kumar S, Vimal VK, Manchanda RK. Assessment of the effectiveness of homoeopathic remedies in improving quality of life of chronic urticaria patients in a typical clinical setting. *Indian J Res Homoeopathy* 2018;12:139-48.
19. Pais G. Case of Idiopathic Urticaria. Homeopathic Academy of Naturopathic Physicians. Available from: https://hanp.net/wp-content/uploads/2017/08/Case_Submission_Examples.pdf. [Last accessed on 2020 May 05].

दीर्घस्थायी अर्टिकैरिया का होम्योपैथी से उपचार – एक केस श्रृंखला

परिचय: अर्टिकैरिया एक प्रकार का त्वचा रोग है जिसमें लाल, उभरे हुए, खुजली वाले एलर्जिक फफोले उत्पन्न होते हैं। अर्टिकैरिया का प्रकोप किसी संक्रमण या औषधि, कीड़े के काटने या भोजन लेने के पश्चात् एलर्जिक प्रतिक्रिया के परिणामस्वरूप बार बार होते हैं। मनोवैज्ञानिक तनाव, ठंड, कंपन के संपर्क में आने से भी अर्टिकैरिया उत्प्रेरित हो सकता है। अर्टिकैरिया की प्रबलता लगभग 20 प्रतिशत लोगों में जीवनभर रहती है। अर्टिकैरिया के 30 प्रतिशत रोगियों में, इसका प्रकोप महीनों या वर्षों तक बार बार होता है। **सारांश:** यह दीर्घस्थायी अर्टिकैरिया से पीड़ित पाँच रोगियों की एक केस श्रृंखला है जिनमें एरिथ्रोमेटस लीजन्स, गंभीर खुजली, लाली और सूजन पाया गया एवं जिनका उपचार डा. डी. पी. रस्तोगी, सेंट्रल रिसर्च इंस्टिट्यूट फॉर होम्योपैथी, नोएडा के डर्माटोलॉजी की ओपीडी में किया गया। इन रोगियों को निर्दिष्ट संवैधानिक होम्योपैथिक औषधियाँ लिखी गईं। हेमाटोलॉजिकल एवं सीरोलॉजिकल परीक्षणों में परिवर्तन, मेजर योरसेल्फ मेडिकल आउटकम प्रोफाइल (एमवाईएमओपी2) और अर्टिकैरिया एक्टिविटी स्कोर (यूएस7) का सार आधाररेखा पर 7 दिनों से अधिक समय के बाद प्रस्तुत किया गया और उपचार के अंत में रोग और जीवन की गुणवत्ता में उचित सुधार देखा गया। होम्योपैथी औषधियों, जैसे कि ऐपिस मेलिफिका, कैल्केरिया कार्बोनििका, रूमेक्स क्रिस्पस, पल्सेटिला और हिस्टामाइन को उपयोगी पाया गया।

Traitement homéopathique de l'urticaire chronique - Une série de cas

Introduction: L'urticaire est une sorte de maladie de la peau avec des bosses rouges, en relief et qui démangent. L'urticaire survient fréquemment après une infection ou à la suite d'une réaction allergique à certains médicaments, piqûres d'insectes ou aliments. Le stress psychologique, l'exposition au froid ou aux vibrations peuvent également déclencher de l'urticaire. L'urticaire survient avec une prévalence à vie d'environ 20%. Chez environ 30% des patients souffrant d'urticaire, les crises se reproduisent souvent pendant des mois ou des années. **Résumé des cas:** Il s'agit d'une série de cas de cinq patients souffrant d'urticaire chronique présentant des lésions érythémateuses, des démangeaisons intenses, des rougeurs et des gonflements traités dans l'Ambulatoire Dermatologie du Dr D. P. Rastogi Central Research Institute for Homéopathie, Noida. Les patients se sont vu prescrire des médicaments homéopathiques constitutionnels indiqués. Les modifications des tests hématologiques et sérologiques, Mesurez vous-même le profil des résultats médicaux (MYMOP2) et du score d'activité de l'urticaire additionnés sur 7 jours (UAS7) au départ et à la fin du traitement ont montré une amélioration raisonnable de la maladie ainsi que de la qualité de vie. Les médicaments homéopathiques comme Apis mellifica, Calcarea carbonica, Rumex crispus, Pulsatilla et Histamine se sont avérés utiles.

Tratamiento homeopático de la urticaria crónica – Una serie de casos

Introducción: Urticaria es una especie de queja de la piel con bultos rojos, elevados y con picazón. La urticaria ocurre con frecuencia después de una infección o como resultado de una respuesta alérgica a algunos medicamentos, picaduras de insectos o alimentos. El estrés psicológico, la exposición al frío o a la vibración también pueden desencadenar la urticaria. Urticaria ocurre con una prevalencia de por vida de alrededor del 20%. En alrededor del 30% de los pacientes de urticaria, los ataques a menudo se repiten durante meses o años. **Resumen de casos:** se trata de una serie de casos de cinco pacientes que sufren de urticaria crónica con lesiones eritematosas, picazón intensa, enrojecimiento e hinchazón tratados en Dermatología OPD del Dr. D. P. Rastogi Instituto Central de Investigación para Homeopatía, Noida. Los pacientes fueron prescritos con medicamentos homeopáticos constitucionales. Cambios en las pruebas hematológicas y serológicas, medirase usted mismo Perfil de resultados médicos (MYMOP2) y la Puntuación de Actividad de Urticaria resumida durante 7 días (UAS7) al inicio y al final del tratamiento mostraron una mejoría razonable en la enfermedad, así como en la calidad de vida. Se encontraron útiles medicamentos homeopáticos como Apis mellifica, Calcarea carbonica, Rumex crispus, Pulsatilla e Histamina.

Homöopathische Behandlung of Chronische Urtikaria – Eine Fallserie

Einleitung: Urtikaria ist eine Art von Hautkrankheit mit roten, erhabenen, juckenden Beulen. Urtikaria Häufig auftretens nach einer Infektion oder als Folge einer allergischen Reaktion auf einige Medikamente, Insektensticheoder Nahrungsmittel. Psychischer stress, Kälte oder vibration kann auch Auslöser der Urtikaria. Urtikaria tritt mit einer lebenszeitprävalenz von etwa 20%. In rund 30% der Patienten von Urtikaria, Angriffe Häufig wiederholen, die für Monate oder Jahre. **Fälle Zusammenfassung:** Dies ist eine Fallserie von fünf Patienten mit chronischer Urtikaria mit erythematöser Hautveränderungen, starken Juckreiz, Rötung und Schwellung behandelt Dermatologie OPD von Dr. D. P. Rastogi zentralen Forschungsinstitut für Homöopathie, Noida. Die Patienten verschrieben wurden angegeben konstitutionelle Homöopathische Medikamente. Änderungen in den hämatologischen und serologischen tests, Messen Sie Sich Medical-Outcome-Profile (MYMOP2) und Urticaria Activity Score summiert über 7 Tage (UAS7) an der Grundlinie und am Ende der Behandlung zeigte Fortschritt der Erkrankung, sowie in der Qualität des Lebens. Die homöopathischen Arzneien wie Apis mellifica, Calcarea carbonica, Rumex crispus, Pulsatilla und Histamin wurden als nützlich empfunden.

慢性尿道的同源治疗 - 病例系列

介绍：荨麻疹是一种皮肤投诉与红色，凸起，发痒颠簸。荨麻疹经常发生在感染后或由于对某些药物，昆虫叮咬或食物的过敏反应。心理压力，暴露于寒冷或振动也可能引发荨麻疹。荨麻疹发生在20%左右的一生患病率。在大约30%的荨麻疹患者中，发作往往会复发数月或数年。病例摘要 这是五例患有慢性麻疹患者，红斑病、剧烈瘙痒、发红和肿胀的病例系列，在诺伊达大学拉斯托吉博士皮肤病研究所治疗。患者被开出的显示宪法同源药物。血液学和血清学测试的变化，测量自己的医疗结果概况（MYMOP2）和麻疹活动评分总结超过7天（UAS7）在基线和治疗结束时显示合理的改善疾病以及生活质量。同源性药物，如阿皮斯美利卡，卡尔卡雷达碳，鲁梅克斯脆，普尔萨蒂拉和西塔明被发现有用。