

# Management of post-intubation subglottic stenosis with individualised homoeopathic therapy: A case report

Shelly Satish Sharma<sup>1</sup>, Seema Mahesh<sup>2\*</sup>, George Vithoulkas<sup>3</sup>

<sup>1</sup>Department of Homeopathy, Janardan Rai Nagar, Rajasthan Vidyapeeth, Udaipur, Rajasthan, India, <sup>2</sup>School of Medicine, Faculty of Health and Medical Sciences, Taylor's University, Subang Jaya, Malaysia, <sup>3</sup>Postgraduate Doctors Training Institute, Health Care Ministry of the Chuvash Republic, Cheboksary, Russian Federation

## Abstract

**Introduction:** Subglottic stenosis is a narrowing of the airway just below the vocal cords. This narrowing can cause serious breathing difficulties. Subglottic stenosis can be congenital or acquired. Frequent or long-term intubation is the most common cause of acquired subglottic stenosis. **Case Summary:** In this case report, adjuvant homoeopathic treatment helped prevent tracheal stent implantation surgery, otherwise deemed necessary in such a state and improved the overall general state. This case report gives ground to further investigate the extent to which individualised Homoeopathy may be applied in postintubation subglottic stenosis.

**Keywords:** *Antimonium tartaricum*, Coronary artery bypass grafting, Homoeopathy, Paralytic ileus, Postintubation stenosis, Postoperative pulmonary dysfunction, Tracheal stent

## INTRODUCTION

Postoperative pulmonary dysfunction (PPD) is a frequent and significant<sup>[1]</sup> complication after coronary artery bypass grafting (CABG) with over 40% of patients readmitted into intensive care units (ICUs) with this state, presenting with respiratory failure.<sup>[2]</sup> Treatment of acute respiratory failure frequently requires intubation of the trachea with either an endotracheal or tracheostomy tube. As the subglottic space is the narrowest part of the airway at the cricoid level, translaryngeal intubation may result in damage involving both the glottis and the subglottis. Subglottic stenosis is graded according to the Cotton–Myer classification system<sup>[3]</sup> from Grade 1 to 4 based on the severity of blockage: Grade I up to 50% obstruction, Grade II from 51% to 70% obstruction, Grade III from 71% to 99% obstruction and Grade IV no detectable lumen.

Subglottic stenosis is a common complication in these cases due to injury during tracheal intubation. This usually follows periods of prolonged intubation in ICUs due to need for mechanical ventilatory support.<sup>[4]</sup> The most common symptom is gradually worsening breathlessness, which in severe cases can be identified as stridor. Stabilisation of the

patient's airway, evaluation with bronchoscopy and use of a temporising airway appliance are the important components of the management of airway complications.<sup>[4]</sup> A subglottic stenosis is potentially life-threatening condition, and if not corrected in time, it may portend limited life expectancy and cause considerable suffering from debilitating complications.<sup>[5]</sup> The general line of treatment depending on the diagnosis is tracheal dilation using rigid bronchoscope, laser surgery and endoluminal stenting, tracheal resection and laryngotracheal reconstruction.<sup>[6]</sup> Tracheal stent is the common treatment modality, but it leads to complications such as granulation tissue formation (27%), restenosis (19%), migration (10%), fracture (8%), erosion (4%) and bleeding (1%). Granulation tissue formation may be mild enough to remain asymptomatic, moderate to produce stridor or severe enough to present as life-threatening respiratory distress.<sup>[7]</sup>

**\*Address for correspondence:** Dr. Seema Mahesh, School of Medicine, Faculty of Health and Medical Sciences, Taylor's University, Subang Jaya, Malaysia. E-mail: [research@vithoulkas.com](mailto:research@vithoulkas.com)

**Received:** 19.11.2019; **Accepted:** 14.08.2020; **Published:** 28.09.2020

Video Available on: [www.ijrh.org](http://www.ijrh.org)

Access this article online

Quick Response Code:



Website:  
[www.ijrh.org](http://www.ijrh.org)

DOI:  
10.4103/ijrh.ijrh\_80\_19

This is an open access journal, and articles are distributed under the terms of the Creative Commons Attribution-NonCommercial-ShareAlike 4.0 License, which allows others to remix, tweak, and build upon the work non-commercially, as long as appropriate credit is given and the new creations are licensed under the identical terms.

**For reprints contact:** [reprints@medknow.com](mailto:reprints@medknow.com)

**How to cite this article:** Sharma SS, Mahesh S, Vithoulkas G. Management of post-intubation subglottic stenosis with individualised homoeopathic therapy: A case report. *Indian J Res Homoeopathy* 2020;14:211-7.

Classical homoeopathy has been reported<sup>[8]</sup> in the treatment of hospitalised critical illness<sup>[9,10]</sup> before; there are published cases such as postoperative coma,<sup>[11]</sup> severe sepsis<sup>[12]</sup> and typically surgical cases<sup>[13]</sup> which have documented remarkable effects of Homoeopathy. However, there have not been any other reports on PPD or subglottic stenosis treated with Homoeopathy, to the best of the authors' knowledge.

## CASE REPORT

A 47-year-old Indian male patient's relative brought the patient's report on November 20, 2014, at Cura Homeopathic Clinic, Vasai, Maharashtra. The patient was admitted in the ICU for severe breathlessness, tachypnoea, tachycardia and severe stridor with sudden lung collapse.

Before the patient was introduced to the homoeopathic treatment, the pulmonologist examining the patient found a 50% subglottic stenosis narrowing of tracheal lumen. He was advised to have a tracheal stent. However, due to the collapsed lung, as mentioned in the inpatient department's case paper of the patient, the patient was not in a state to undergo the procedure. He had also developed paralytic ileus and antibiotic resistance. Resistance to penicillins, beta-lactamase inhibitors, cephalosporins, aminoglycosides, fluoroquinolones, carbapenams and co-trimoxazole was reported. The patient was sensitive to Colistin and intermediate to tigecycline. The patient's left ventricular ejaculation was reported as 25%.

## Clinical History

The patient had undergone CABG two months earlier. During that period, the patient had a history of dyspnoea with recurrent cough and was intubated twice to provide ventilator support.

The patient, at present, was in no state to give the symptoms in his collapsed state, and at the time of first consultation, the totality for homoeopathic prescription was drawn from information gathered from his attendants, on bedside observations made by the prescribing physician and from the clinical diagnosis. On 20<sup>th</sup> November 2014, the medicine prescribed was *Antimonium tartaricum* 200C, single dose.

## Bedside observations

- The patient could not bring up expectoration, but was relieved when he brought it up
- Cough forced him to sit erect
- Anguished look
- Delusions of ghosts at night
- Wants to hold hand of attendant at night
- Fear of being alone
- Anger on contradiction
- Sunken look of the face and eyes
- Strong offensive odour from the body of the patient
- Nostrils flapping motion
- The patient seems in lot of pain

- Coldness of breath
- Angered if his wife asked him anything.

## Physical generals

- Temperature: 99.6°F
- Blood pressure: 160/94 mm Hg
- Pulse rate: 82 per minute
- SpaO<sub>2</sub> with O<sub>2</sub> insufflation: 88%.

Acute dispositional and characteristic symptoms of the patient were selected for constructing the totality and for repertorisation.

The details of prescription and the follow-up are given in Table 1.

The follow-up lasted for over 18 months, during which the patient showed remarkable improvement in respiratory complaints with no severe relapse. His quality of life improved.

Modified Medical Research Council Dyspnoea scale was used to assess the prognosis of the patient at each follow-up which is represented graphically in figure 1. (X-axis is follow-up and Y-axis is the score. The scoring was performed by a homoeopathic doctor.

## DISCUSSION

Tracheal injuries, independent of their origin, may be life-threatening. Surgical repair is regarded as the treatment of choice, but has not been compared with other approaches.<sup>[14]</sup> There are well documented case reports which show the possibility of homoeopathy to treat severe pathologies.<sup>[15-18]</sup> Homoeopathic prescription is based on the signs and symptoms of the patient and not on the diagnosis or pathology alone.<sup>[19]</sup> This way, the entire immunological events and reactions in a person's life are considered to arrive at a solution that is integrative.<sup>[20,21]</sup>

Therefore, it is able to address the multifactorial nature of the autoimmune diseases and other conditions that involve the whole organism. In this case also, we see that there is a systemic inflammatory response prior to the lung collapse and this itself might have triggered the later events.

We could observe that on the second day, after administration of *Antimonium tartaricum*, the frequency of suction was reduced to 3–4 times a day from 1-2 hourly, followed by improvement in breathlessness and decrease in expectoration. Furthermore, the patient passed stools on the second day which he was previously unable to, due to paralytic ileus. The remedy *Antimonium tartaricum* 200C<sup>[22]</sup> not only helped the patient to recover from his pulmonary dysfunction, but brought about an overall well-being. Although prognosis is bad in postoperative pulmonary complications,<sup>[23]</sup> this patient improved with homoeopathy given along with the conventional medication to control hypertension and elevated blood lipid levels, as well as anticoagulation medication and anti-allergic remedies.

**Table 1: Follow Up**

Date	Detailed symptom/observation	Homoeopathic Prescription	Allopathic treatment
20 November 2014	Breathlessness, peripheral capillary SapO <sub>2</sub> with O <sub>2</sub> insufflation - 88% Suction required every 1-2 hours Expulsion power of lung diminished. Paralytic ileus. Swelling of lower extremities. Advised tracheal stent Homoeopathic totality of the case Expectoration after amelioration Coldness of breath Face expression suffering, Hippocratic, anxious, sunken Rattling Face, Hippocratic Fan like motion of wings if nose Delusion sees spectres, ghost, spirits Clinging to attendant Anger from contradiction Vitals Temperature: 99.6°F Blood Pressure: 160 systolic and 94 Diastolic Pulse Rate: 82	<i>Antimonium tartaricum</i> 200C single dose	Allopathic medications as prescribed
22 November 2014	After patient took the first dose of <i>Antimonium tartaricum</i> 200C single dose, patient had lot of cough and expectoration on 20 November 2014 Patient was restless all night. On 21 November 14, passed stools without enema Tracheal stenting was not performed as patient was better SpaO <sub>2</sub> maintained 95% with O <sub>2</sub> insufflation Suction done every 3-4 hours	Nil	Allopathic medications as prescribed
3 December 2014	Patient was discharged from hospital SpaO <sub>2</sub> maintained between 91%-96% without O <sub>2</sub> insufflation	Nil	Allopathic medications as prescribed
07 December 2014	Passing stool without enema SpaO <sub>2</sub> maintained between 91%-96% without O <sub>2</sub> insufflation	Nil	Allopathic medications as prescribed
21 December 2014	Patient had cough with little expectoration Cough followed by breathlessness, better by expectoration Is of angry and irritable disposition Passing stool without enema SpaO <sub>2</sub> maintained between 88%-92% without O <sub>2</sub> insufflation Patient had stopped tablet montelukast, tablet ciprofloxacin 500 Mg, tablet acetylcysteine 600 Mg, Lactobacillus Sachet, Multivitamin and whey powder and advised to stop tablet alprazolam 0.5 Mg	<i>Antimonium tartaricum</i> 200 single dose	Allopathic medications as prescribed
6 January 2015	Breathlessness better Appetite improved Passing stool without enema SpaO <sub>2</sub> maintained between 91%-98% without O <sub>2</sub> insufflation Patient was advised to taper the doses of tablet theophylline 150 Mg and use if experience wheezing, shortness of breath and breathing problems Formoterol inhaler 200 Mg advised once a day	Nil	Allopathic medications as prescribed
7 February 2015	Breathlessness improved SpaO <sub>2</sub> maintained between 91%-98% without O <sub>2</sub> insufflation Patient did not need to take tablet theophylline 150 mg. Patient was advised to take if breathless Patient was advised to stop tiotropium inhaler	Nil	Allopathic medications as prescribed
9 March 2015	Breathlessness improved Passing motions without enema SpO <sub>2</sub> maintained between 90%-95% without O <sub>2</sub> insufflation Patient did not need to take tablet theophylline 150 Mg. He was advised to take if breathless. Formoterol inhaler 200 Mg to be taken if breathless	Nil	Allopathic medications as prescribed

Contd...

Table 1: Contd...

Date	Detailed symptom/observation	Homoeopathic Prescription	Allopathic treatment
11 April 2015	Breathlessness improved Patient can manage his personal work Able to do little household work SpaO <sub>2</sub> maintained between 94%-97% without O <sub>2</sub> insufflation. Patient did not need to take tablet theophylline 150 Mg was advised to take if breathless. Patient did not need to take formoterol inhaler. Advised to be taken if breathless	Nil	Allopathic medications as prescribed

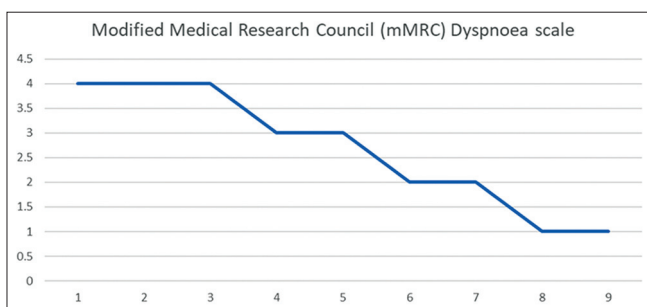
SpO<sub>2</sub>: Oxygen saturation

Figure 1: Modified medical research council dyspnea scale

Of these, the anti-allergics, bronchodilators, steroids and mucolytic agents could further be tapered down. Although it may be difficult to achieve good response in all cases with such a poor prognosis, this case demonstrates the potential and scope of homoeopathy. When the patient was admitted in a state of acute respiratory distress, he was examined by the pulmonologist and was advised for tracheal stenting. The patient's left ventricle ejection fraction was 25%. The relatives did not give the consent for the tracheal stenting because the patient's respiratory, cardiac and general condition was poor and non responsive. Then, homoeopathic medicine *Antimonium tartaricum* 200C was prescribed. The patient was advised for bronchoscopy and Computed Tomography scan. As the patient did not undergo the procedure, so the investigators are not in a position to describe the post interventional state of the respiratory tract. This case can also have a selection bias as the patient and attendants chose to take homoeopathic treatment. As case reports are the first line of evidence and the scientific documentation of a single clinical observation, a good case report should be clear about the importance of the observation being reported. If multiple case reports show something similar, the next step might be a case-control study to determine if there is a relationship between the relevant variables. Hence, conducting controlled studies could clear this bias.

## CONCLUSIONS

This case of PPD with subglottic stenosis after CABG surgery, was treated with individualised homoeopathic therapy along with conventional medicine, preventing the tracheal stenting, which was otherwise indicated. Further, the patient's general condition and quality of life improved greatly, as shown by a

long follow-up after the crisis. Although, a case report would not lead to a conclusion to arrive upon the role of homoeopathy in tracheal injuries, it gives a scope and potential to study more tracheal injury cases with homoeopathy which are not responding to conventional medicines. Clinical practice, and further randomized controlled trials are needed to arrive to definitive conclusion.

## Declaration of patient consent

The authors certify that they have obtained all appropriate patient consent forms. The patient understands that his name and initials will not be published and due efforts will be made to conceal identity, but anonymity cannot be guaranteed.

## Ethical approval

Not obtained as the patient volunteered for homoeopathic treatment.

## Financial support and sponsorship

Nil.

## Conflicts of interest

None declared.

## REFERENCES

- Piotto RF, Ferreira FB, Colósimo FC, Silva GS, Sousa AG, Braile DM. Independent predictors of prolonged mechanical ventilation after coronary artery bypass surgery. *Rev Bras Cir Cardiovasc* 2012;27:520-8.
- Kogan A, Cohen J, Raanani E, Sahar G, Orlov B, Singer P, *et al.* Readmission to the intensive care unit after "fast-track" cardiac surgery: Risk factors and outcomes. *Ann Thorac Surg* 2003;76:503-7.
- Myer CM, O'Connor DM, Cotton RT. Proposed grading system for subglottic stenosis based on endotracheal tube sizes; 1994. *Journals.sagepub.com*; 2018. Available from: <http://journals.sagepub.com/doi/10.1177/000348949410300410>. [Last accessed on 2018 Dec 01].
- Antonio D, Andrilli E. Subglottic Tracheal Stenosis. *PubMed Central (PMC)*; 2018. Available from: <https://www.ncbi.nlm.nih.gov/pmc/articles/PMC4775266/>. [Last accessed on 2018 Nov 21].
- Saenghirunvattana S, Pitiguagool V, Suwanakijboriharn C, Pupipat P, Saenghirunvattana B, Gonzales M, *et al.* Different approaches on various cases of tracheal stenosis. *Open J Respir Dis* 2014;4:90-100.
- Karapantzou I, Karapantzou C, Zarogoulidis P, Tsakiridis K, Charalampidis C. Benign tracheal stenosis a case report and up to date management. *Ann Transl Med* 2016;4:451.
- Bansal S, Dhingra S, Ghai B, Gupta AK. Metallic stents for proximal tracheal stenosis: Is it worth the risk? *Case Rep Otolaryngol* 2012;2012:450304.
- Eyles C, Leydon GM, Lewith GT, Brien S. A grounded theory study of homeopathic practitioners' perceptions and experiences of the homeopathic consultation. *Evid Based Complement Alternat Med*

- 2011;2011:957506.
9. Oberbaum M, Singer SR, Friehs H, Frass M. Homeopathy in emergency medicine. *Wien Med Wochenschr* 2005;155:491-7.
  10. Teixeira MZ, Leal SM, Ceschin VM. Homeopathic practice in Intensive Care Units: Objective semiology, symptom selection and a series of sepsis cases. *Homeopathy* 2008;97:206-13.
  11. Vithoulkas SG. Homeopathic Treatment for Prolonged Postoperative coma: A Case Report. *PubMed Central (PMC)*; 2018. Available from: <https://www.ncbi.nlm.nih.gov/pmc/articles/PMC5467251/>. [Last accessed on 2020 Nov 21].
  12. Frass M, Linkesch M, Banyai S, Resch G, Dielacher C, Löbl T, *et al.* Adjunctive homeopathic treatment in patients with severe sepsis: A randomized, double-blind, placebo-controlled trial in an intensive care unit. *Homeopathy* 2005;94:75-80.
  13. Mahesh S, Mallappa M, Vithoulkas G. Gangrene: Five case studies of gangrene, preventing amputation through homeopathic therapy. *Indian J Res Homoeopathy* 2015;9:114.
  14. Beiderlinden M, Adamzik M, Peters J. Conservative treatment of tracheal injuries. *Anesth Analg* 2005;100:210-4.
  15. Chhabra SK, Gupta AK, Khuma MZ. Evaluation of three scales of dyspnea in chronic obstructive pulmonary disease. *Ann Thorac Med* 2009;4:128-32.
  16. Tenzera L, Djindjic B, Mihajlovic-Elez O, Pulparampil BJ, Mahesh S, Vithoulkas G. Improvements in long standing cardiac pathologies by individualized homeopathic remedies: A case series. *SAGE Open Med Case Rep* 2018;6:2050313X18792813.
  17. Mahesh S, Mallappa M, Vithoulkas G. Embryonal carcinoma with immature teratoma: A homeopathic case report. *Complement Med Res* 2018;25:117-21.
  18. Denisova TG, Gerasimova LI, Pakhmutova NL, Mahesh S, Vithoulkas G. Individualized homeopathic therapy in a case of obesity, dysfunctional uterine bleeding, and autonomic dystonia. *Am J Case Rep* 2018;19:1474-9.
  19. Hahnemann S. *Hahnemann's organon of medicine*. 6<sup>th</sup> ed. Apph 7. New Delhi: B Jain Pub Pvt Ltd; 1994.
  20. Bellavite P, Ortolani R, Pontarollo F, Pitari G, Conforti A. Immunology and homeopathy. 5. The rationale of the 'Simile'. *Evidence-Based Complementary and Alternative Medicine*. 2007;4:634864.
  21. Bellavite P. Homeopathy and integrative medicine: Keeping an open mind. *J Med Person* 2015;13:1-6.
  22. Boericke W. *Pocket manual of homeopathic materia medica and repertory*. New Delhi, India: B. Jain; 2002.
  23. Trayner E Jr, Celli BR. Postoperative pulmonary complications. *Med Clin North Am* 2001;85:1129-39.

### व्यक्तिकृत सहायक होम्योपैथिक उपचार प्रणाली के साथ, पोस्ट-ट्यूबेशन सबग्लोटिक स्टेनोसिस का प्रबंधन

**परिचय:** सबग्लोटिक स्टेनोसिस, वोकल कॉर्ड्स (स्वर-रज्जु) के ठीक नीचे स्थित वायुमार्ग का संकीर्ण हो जाने की एक प्रक्रिया है। इस संकीर्णता के कारण श्वसन क्रिया में गंभीर कठिनाई आ सकती है। सबग्लोटिक स्टेनोसिस जन्मजात या अभिगृहीत हो सकती है। **सारांश:** इस केस रिपोर्ट में, सहायक होम्योपैथिक उपचार ने ट्रैकिअल स्टेंट इम्प्लांटेशन सर्जरी को रोकने में सहायता प्रदान की, अन्यथा ऐसी स्थिति में ऐसा किया जाना आवश्यक प्रतीत होता था और इस उपचार ने कुल मिलाकर सामान्य स्थिति में सुधार किया। यह केस रिपोर्ट उस सीमा तक आगे की जांच-पड़ताल करने के लिए आधार प्रदान करती है जिसमें व्यक्तिकृत होम्योपैथी का उपयोग पोस्ट-ट्यूबेशन सबग्लोटिक स्टेनोसिस में किया जा सकता है।

### Prise en charge de la sténose sous-glottique post-intubation par traitement homéopathique adjuvant individualisé

**Introduction:** La sténose sous-glottique est un rétrécissement des voies respiratoires juste en dessous des cordes vocales. Ce rétrécissement peut entraîner de graves difficultés respiratoires. La sténose sous-glottique peut être congénitale ou acquise. L'intubation fréquente ou à long terme est la cause la plus fréquente de sténose sous-glottique acquise. **Résumé de cas:** Dans ce rapport de cas, le traitement homéopathique adjuvant a permis d'éviter la chirurgie d'implantation d'endoprothèse trachéale, autrement jugée nécessaire dans un tel état et a amélioré l'état général global. Ce rapport de cas donne une raison à une étude plus approfondie de la mesure dans laquelle l'homéopathie individualisée peut être appliquée dans la sténose sous-glottique post-intubation.

### Manejo de la estenosis subglotótica postintubación con terapia de tratamiento homeopático adyuvante individualizada

**Introducción:** La estenosis subglotótica es un estrechamiento de las vías respiratorias justo debajo de las cuerdas vocales. Este estrechamiento puede causar serias dificultades respiratorias. La estenosis subglotótica puede ser congénita o adquirida. La intubación frecuente o a largo plazo es la causa más común de estenosis subglotótica adquirida. **Resumen del caso:** En este informe de caso, el tratamiento homeopático adyuvante ayudó a prevenir la cirugía de implantación de stent traqueal, que de lo contrario se consideró necesario en tal estado y mejoró el estado general general. Este informe de caso da terreno para investigar más a fondo en qué medida se puede aplicar la Homeopatía individualizada en la estenosis subglotótica posterior a la intubación.

## Management der subglottischen Stenose nach der Intubation mit individualisierter adjuvanter homöopathischer Behandlungstherapie

**Einleitung:** Subglottische Stenose ist eine Verengung der Atemwege unterhalb der Stimmbänder. Diese Verengung kann zu ernsthaften Atembeschwerden führen. Subglottische Stenose kann angeboren oder erworben werden. Häufige oder langfristige Intubation ist die häufigste Ursache für eine erworbene subglottische Stenose. **Fallzusammenfassung:** In diesem Fallbericht, adjuvante homöopathische Behandlung half, Trachealstent- Implantat Chirurgie zu verhindern, andernfalls in einem solchen Zustand als notwendig erachtet und den allgemeinen Gesamtzustand verbessert. Dieser Fallbericht gibt Aufsehen, um weiter zu untersuchen, inwieweit individualisierte Homöopathie bei der subglottischen Stenose der Postintubation angewendet werden kann.

### 通过个性化辅助同源治疗治疗，对后插管亚体狭窄进行管理

介绍: 亚格洛特狭窄是声带正下方的气道的变窄。这种变窄会导致严重的呼吸困难。亚格洛蒂莫氏症可以是先天性或后天性。频繁或长期插管是后天狭窄最常见的原因。案例摘要: 在本次案例报告中，辅助同源治疗有助于防止气管支架植入手术，否则认为在这样的状态下是必要的，并改善了整体状态。本案例报告为进一步研究个体性同性病变在后植入性亚格肌狭窄中应用的程度提供了理由。