

# Evidence-based Homoeopathy: A case report of nodular episcleritis

Sandeep Sudhakar Sathye\*

Department of Homoeopathy, Sathye Eye Research Institute for Alternative Medicines, Pune, Maharashtra, India

## Abstract

**Introduction:** Nodular episcleritis (NE) is a variety of episcleritis characterised by inflammation of subconjunctival connective tissue leading to development of a localised raised congested nodule with mild pain and tenderness. It can last for weeks with a tendency to recur and is often considered as an allergic reaction to endogenous toxins. Conventional treatment includes the use of topical steroids and non-steroidal anti-inflammatory drugs which give a temporary relief. **Case Summary:** The case of a 62-year-old male patient suffering from NE in the right eye for 15 days not responding to conventional treatment is reported here. Homoeopathic *Mercurius solubilis* 30C prescribed on the basis of totality of symptoms resolved NE within a week with no recurrence for 1 year and 4 months. This case report with photographic evidence shows the effectiveness of *Mercurius solubilis* 30C in non-rheumatoid nodular episcleritis.

**Keywords:** Eye, Homoeopathy, Inflammation, *Mercurius solubilis*, Modified Naranjo criteria, Nodular episcleritis

## INTRODUCTION

Episcleritis is an acute, mostly unilateral inflammatory condition involving deep subconjunctival connective tissue and is common in adults and in females.<sup>[1]</sup> Most cases of episcleritis are idiopathic, but a few are associated with connective tissue diseases.<sup>[2]</sup> However, it is often regarded as an allergic reaction to an endogenous toxin.<sup>[3]</sup> Clinically, episcleritis is associated with ocular congestion, mild pain and tenderness. The course of episcleritis is long, usually lasting for weeks with a tendency to recur.<sup>[4]</sup> Resolution takes a longer time in elderly patients.<sup>[5]</sup> Watson and Hayreh classified episcleritis into simple and nodular variety.<sup>[6]</sup> Simple (diffuse) variety is common, affecting any sector of the eye and usually resolves spontaneously within 1–2 weeks,<sup>[7]</sup> whereas nodular episcleritis (NE) is relatively less common and characterised by development of a localised, raised congested nodule. It involves one sector of the eye usually temporal, with little or no pain but tenderness.<sup>[3]</sup> It lasts longer than the simple variety, and spontaneous resolution occurs in 5–6 weeks.<sup>[8]</sup> However, it has a strong tendency to recur.<sup>[3]</sup> In cases of episcleritis, investigations are not usually required unless there is persistent inflammation or a history suggestive of systemic disease.<sup>[8]</sup> Conventional treatment for NE includes the use of topical steroids and non-steroidal

anti-inflammatory drugs, but they give temporary relief and are associated with complications if steroids are used for long duration.<sup>[3]</sup> Symptomatic relief can be achieved with the use of hot compresses.

Homoeopathic literature has mentioned different medicines for episcleritis, and these are as follows, with their gradation:

- Eye – Inflammation – Episclera and sclera – *Acon.*, *Aur.*, *Cinnb.*, *Cocc.*, *Kalm.*, *Merc.*, *Nux-m.*, *Puls.*, *Sep.*, *Spig.*, *Sulph.*, *Ter.* *Thuja*<sup>[9]</sup>
- Episcleritis and Scleritis – *Kalm.*, *Merc.*, *Sep.*, *Thu.*, *Aco.*, *Aur.*, *Cinnab.*, *Coccul.*, *Nux. m.*, *Puls.*, *Spig.*, *Tereb.* and *Sulph*<sup>[10]</sup>
- Eye – Sclerotica – Inflammation – Superficial (episcleritis) – *Acon.*, *Bell.*, *Bry.*, *Kali-i.*, *Merc-c.*, *Rhus-t.*, *Ter.* and *Thuja*<sup>[11]</sup>
- Eye – Sclerotica – Episcleritis – *Merc.*, *Nux-m.* and *Thuja*<sup>[12]</sup>

**\*Address for correspondence:** Dr. Sandeep Sudhakar Sathye, Plot No. 4, S. No. 28/4A, Sadanand Nagar, Anand Nagar, Hingne (Khurd), Sinhagad Road, Pune - 411 051, Maharashtra, India. E-mail: sandeepsathye@gmail.com

**Received:** 11.01.2020; **Accepted:** 28.07.2020; **Published:** 28.09.2020

### Access this article online

#### Quick Response Code:



**Website:**  
[www.ijrh.org](http://www.ijrh.org)

**DOI:**  
10.4103/ijrh.ijrh\_101\_19

This is an open access journal, and articles are distributed under the terms of the Creative Commons Attribution-NonCommercial-ShareAlike 4.0 License, which allows others to remix, tweak, and build upon the work non-commercially, as long as appropriate credit is given and the new creations are licensed under the identical terms.

**For reprints contact:** [reprints@medknow.com](mailto:reprints@medknow.com)

**How to cite this article:** Sathye SS. Evidence-based Homoeopathy: A case report of nodular episcleritis. *Indian J Res Homoeopathy* 2020;14:218-24.

- Eye – Inflammation – Sclerotic: *Aco.*, *Ars.*, *Aur.*, *Bar-c.*, *Bell.*, *Bry.*, *Hep.*, *Kali-i.*, *Kalm.*, *Merc.*, *Plb.*, *Rhus-t.*, *Sep.*, *Spi.*, *Tereb.* and *Thu*<sup>[13]</sup>
- Eye – Inflammation – Sclerotic: *Aco.*, *Cocc.*, *Kalm.*, *Merc.*, *Psor.*, *Rhus-t.*, *Spig.* and *Thuj.*<sup>[14]</sup>

## CASE REPORT

### Patient history

A male patient aged 62 years reported on 12 July 2018 to Sathye Eye Research Institute for Alternative Medicines, Pune, India, Outpatient Department with complaints of redness, swelling and occasional foreign body sensation in the right eye for the last 15 days. He was previously evaluated by an ophthalmologist as NE and treated with topical anti-inflammatory drugs without much relief. So the patient approached for homeopathic treatment. The patient was also a known case of hypertension and diabetes mellitus, controlled with conventional treatment. He had no associated complaints of joints or fever or weight loss, etc. There was no past history of similar ocular complaint, ocular trauma or surgery, general illness, etc.

### Clinical examination

On general examination, there was no fever or lymphadenopathy. Systemic examination, including respiratory and musculoskeletal system, was reported normal. Oral examination revealed no dental caries. On eye examination, the patient's vision was 6/6 on Snellen chart in both eyes with hypermetropic glasses. On slit-lamp examination, there was congestion on the temporal side with a localised raised area of about 4–5 mm from the limbus in the right eye [Figures 1 and 2]. There was mild localised tenderness, and conjunctiva was moving freely over the nodule. There was no abnormality either on cornea, iris or lens.

### Case analysis

In this case, local signs and symptoms were considered for repertorisation such as inflammation of the sclera and episcleral tissue, affection of the right eyeball, localised pain on pressure and foreign body sensation in the eye. Repertorisation was done with the help of homeopathic software, Hompath Vital® (Mind Technologies Pvt. Ltd.; Mumbai, India: 2000), and repertorisation chart is presented in Figure 3.

The first six medicines with higher score are as follows in their descending order: *Belladonna*, *Mercurius solubilis (Merc.)*, *Aconite*, *Thuja*, *Rhus toxicodendron*. and *Bryonia*.

In *Belladonna*, inflammation is severe in intensity with throbbing pain, heat and dry sensation in the eye. *Aconite* is useful in acute stage when there are violent, burning and shooting pains with dryness and sensitiveness of the eyeball to touch. *Thuja* has an affinity for the left eyeball, while *Rhus-t* and *Bryonia* are indicated in rheumatic inflammation. Knerr<sup>[12]</sup> has mentioned *Merc*, *Nux moschata* and *Thuja* as the chief medicines for episcleritis, but *Nux-m* is indicated in NE if the nodule is very large and painful, and the patient is drowsy

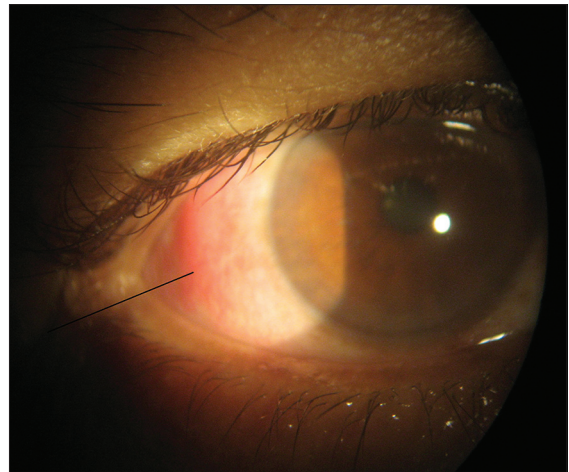


Figure 1: Nodular episcleritis before treatment (dated: 12 July 2018)

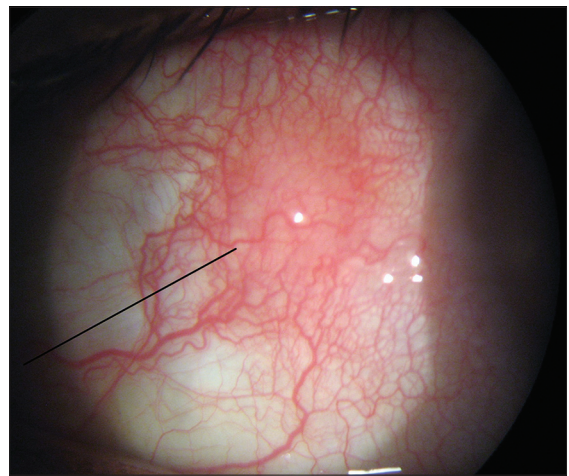


Figure 2: Magnified view of nodular episcleritis before treatment

Repertorisation: Normal												
Remedy Name	Bell	Merc	Acon	Thuja	Rhus-t	Bry	Cala	Hep	Nat-m	Nux-m	Sep	Psor
Totality	10	10	9	8	8	7	6	5	5	5	4	4
Symptom Covered	5	5	5	4	4	5	2	3	2	2	4	3
[BN] [Eyes]Inflammation:Sclerotic, of:	1	1	1	1	1	1		1				
[KT] [Eye]Inflammation:Sclerotics:		2	1	2	1						1	2
[BR] [Eyes]Sclerotic:Inflammation:Sc:	2		3	3	2	2						
[BN] [Eyes]Eyeball:Right:	4	2	1		4	1	4	1	4	4	1	1
[KT] [Eye]Pain:Touch,agg:	2	2		1	2	2	3					1
[BN] [Eyes]Foreign body in:As of:	1	3	3	1		1	2		1	1	1	1

Figure 3: Repertorisation chart

with sleepy expression of the eyes,<sup>[4]</sup> so these medicines were eliminated. Hence, *Mercurius solubilis* was selected for this case, and Knerr has also mentioned it for episcleritis if there is a scleral congestion, especially between insertion of recti muscle where the sclera is slightly bulged and thinner.<sup>[12]</sup>

### Intervention

Homeopathic *Mercurius solubilis* 30C-medicated globules of size no. 35 were dispensed with a dose of two pills, to be taken four times a day for 2 days; on the basis



of totality of local signs and symptoms. The patient was not advised any local treatment or any alteration in their diet and regimen.

### Follow-up and outcome

On 14 July 2018, there was a mild reduction of redness and foreign body-like sensation in the eye. On eye examination, a reduction of congestion, tenderness and size of nodule was observed. Hence, the same medicine was continued in BD dose for 4 days.

On 19 July 2018, there was a further reduction of redness of the eye with no foreign body sensation. On eye examination, congestion was much reduced with no tenderness and nodule has resolved completely, so medicine was stopped [Figures 4 and 5].

On 1 October 2018, the patient was contacted on phone and he reported that there were no ocular complaints thereafter, so did not come for follow-up.

On 7 December 2019, he came for check-up after telephonic contact and reported no recurrence of eye complaints. Eye examination showed no abnormal findings, especially related to the sclera. The timeline of the patient including first and follow-up visits is mentioned in Table 1.

The modified Naranjo criteria were used in this case for assessing causal attribution to the medicine prescribed,<sup>[15]</sup> and the total score was 9 [Table 2]. It suggests a 'definite' association between the medicine prescribed and the final outcome (definite:  $\geq 9$ , probable 5–8, possible 1–4 and doubtful  $\leq 0$ ).<sup>[16]</sup>

### DISCUSSION

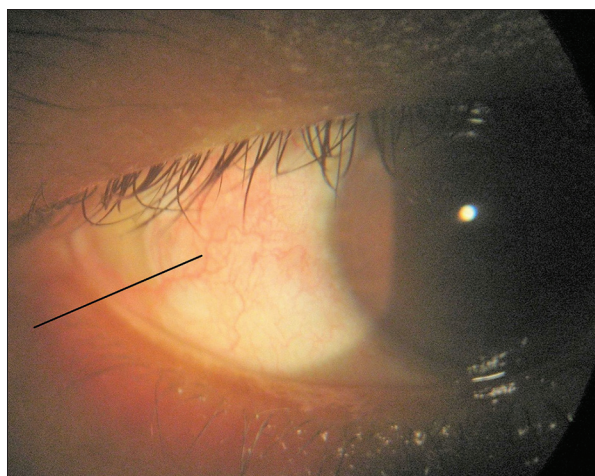
NE is considered to be associated with rheumatic conditions and foci of infection principally in teeth and tonsils.<sup>[17]</sup> In the case presented here, there were no rheumatic or other complaints related to systemic diseases, however, perhaps was a known diabetic, and since diabetics are prone to infection, so the probable cause of NE could be a low-grade endogenous

infection. Materia Medica books mention the use of *Mercurius solubilis* for suppurative processes in the body, and medicine has probably acted on endogenous septic focus leading to a rapid resolution of NE in this case.

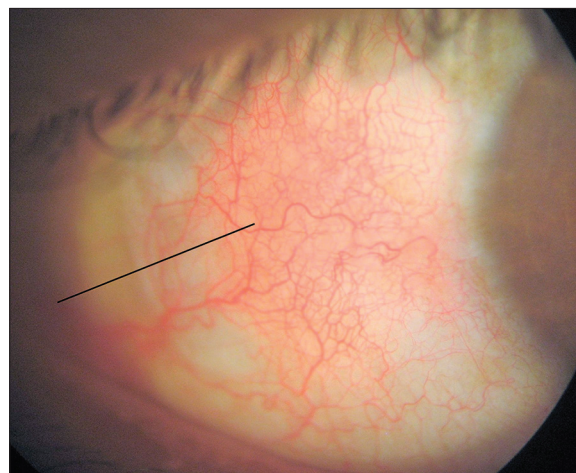
*Mercurius solubilis* was used in medium (30C) potency because the patient was of old age and on allopathic treatment for diabetes and hypertension, and NE had a moderate intensity of symptoms, which showed a moderate susceptibility of the patient. Similarly, pathology was reversible in nature, and prescription was based on local, rather than on general symptoms of the patient. NE has resolved within a week with no untoward effects and without recurrence. This justifies the correct selection of remedy, its potency and repetition.

There is a least possibility of natural resolution of NE in this case, as it usually lasts for weeks with a strong tendency to recur; similarly, the duration of inflammation is more in non-rheumatoid NE patients<sup>[11]</sup> and in aged patients.<sup>[5]</sup> Thus, NE is not a benign and self-limiting variety of episcleritis but an allergic reaction to endogenous toxin, so unless treated with systemic medication, it is bound to recur again and again. In the case reported, the patient was of old age group and suffering from non-rheumatoid NE. After starting homeopathic treatment, there was a reduction of all ocular complaints along with size of nodule within 2 days and with a complete resolution of NE within the next 5 days. As patient's complaints were not severe, no supportive treatment was given. No alteration in diet/regimen was suggested, and no recurrence was reported in for the last 1 year and 4 months. After assessing the case with modified Naranjo criteria, a 'definite' association between the medicine and the outcome was found. Thus, all the above points go in favour of medicinal effect in resolution of NE.

Modern literature states that most cases of episcleritis are idiopathic. Investigations are not usually required unless there is persistent inflammation or a history suggestive of systemic disease.<sup>[8]</sup> In the case reported, it was the first episode of



**Figure 4:** Nodular episcleritis resolved after treatment (dated: 19 July 2018)



**Figure 5:** Magnified view of resolved nodular episcleritis after treatment

**Table 1: Timeline of the patient including first and follow-up visits**

Date	Response	Treatment with dosage
12 July 2018 (1 <sup>st</sup> visit)	Redness, mild foreign body-like sensation in the right eye for 15 days Ocular congestion and nodular appearance on the temporal side of the right eye with tenderness	<i>Mercurius solubilis</i> 30C, QID × 2 days
14 July 2018	Reduction of redness and foreign body sensation Reduction of nodule size and tenderness	<i>Mercurius solubilis</i> 30C, BD × 4 days
19 July 2018	Further reduction of redness, no foreign body sensation in the eye Ocular nodule resolved completely with no tenderness	Medicine discontinued
1 October 2018	No recurrence as per telephonic contact	-
7 December 2019	No recurrence for the last 1 year and 4 months	-

**Table 2: Assessment of outcome with modified Naranjo criteria**

Scoring parameters	Yes	No	Not sure or N/A
1. Was there an improvement in the main symptom or condition for which the homeopathic medicine was prescribed?	+2		
2. Did the clinical improvement occur within a plausible timeframe relative to the drug intake?	+1		
3. Was there an initial aggravation of symptoms?		0	
4. Did the effect encompass more than the main symptom or condition (i.e. were other symptoms ultimately improved or changed)?			0
5. Did overall well-being improve?			0
6 (A). Direction of cure: did some symptoms improve in the opposite order of the development of symptoms of the disease?	+1		
6 (B). Direction of cure: did at least two of the following aspects apply to the order of improvement of symptoms From organs of more importance to those of less importance From deeper to more superficial aspects of the individual From the top downwards			0
7. Did 'old symptoms' (defined as non-seasonal and non-cyclical symptoms that were previously thought to have resolved) reappear temporarily during the course of improvement?		0	
8. Are there alternate causes (other than the medicine) that with a high probability could have caused the improvement? (consider known course of disease, other forms of treatment and other clinically relevant interventions)		+2	
9. Was the health improvement confirmed by any objective evidence? (e.g., laboratory test, clinical observation, etc.)	+2		
10. Did repeat dosing, if conducted, create similar clinical improvement?	+1		
Total score=9			

N/A: Not available

episcleritis, and there were no obvious signs or symptoms of systemic disease, especially related to the respiratory tract, skin, joints or abdomen, so detailed investigations were not done before or during homeopathic treatment.

NE is a less common condition, and it was treated successfully with a single systemic homeopathic medicine within a week. Such case with photographic documentary evidence was not published so far in Homeopathy as per internet search, so this case was considered for presentation.

Limitation of this study was less number of total follow-ups (i.e. 3), but as the patient had no ocular complaints after receiving homeopathic treatment, he did not come for regular follow-up.

## CONCLUSION

This case presentation with ocular photographic evidence shows effectiveness of homeopathic *Mercurius solubilis* 30C in NE of non-rheumatoid origin, however, a case series or controlled clinical trials with detailed investigations are required to validate the results.

## Declaration of patient consent

The author declares that he has obtained a written informed consent from the patient. In the form, the patient has given written consent for his clinical information and images to be reported in the journal. The patient understands that his name will not be published and due efforts will be made to conceal his identity.

## Financial support and sponsorship

Nil.

## Conflicts of interest

None declared.

## REFERENCES

- McGavin DD, Williamson J, Forrester JV, Foulds WS, Buchanan WW, Dick WC, *et al.* Episcleritis and scleritis. A study of their clinical manifestations and association with rheumatoid arthritis. *Br J Ophthalmol* 1976;60:192-226.
- Salama A, Elsheikh A, Alweis R. Is this a worrisome red eye? Episcleritis in the primary care setting. *J Community Hosp Intern Med Perspect* 2018;8:46-48.
- Sihota R, Tandon R, editors. *Parsons' Diseases of the Eye*. 20<sup>th</sup> ed. New Delhi: Elsevier; 1984. p. 210-11.
- Norton AB. *Ophthalmic Diseases and Therapeutics*. 3<sup>rd</sup> ed. New Delhi:

Sathye: A case of nodular episcleritis

- B. Jain Publishers (P) Ltd.; 1987. p. 277-82.
5. Lyle TK, Cross AG. May and Worth's Manual of Diseases of the Eye. 12<sup>th</sup> ed. London: Bailliere, Tindall and Cox.; 1959. p. 212-6.
6. Watson PG, Hayreh SS. Scleritis and episcleritis. *Br J Ophthalmol* 1976;60:163-91.
7. Kanski JJ. *Clinical Ophthalmology: A Systematic Approach*. 5<sup>th</sup> ed. Edinburgh: Butterworth Heinemann, Elsevier science.; 2003. p. 154-5.
8. Tsai JC, Denniston AK, Murray PI, Huang JJ, editors. *Oxford American Handbook of Ophthalmology*. Oxford, UK: Oxford University Press; 2011. p. 220.
9. Schroyens F. *Synthesis, Repertorium Homeopathicum Syntheticum*. 8.1 ed. London: Homoeopathic Book Publishers; 2001. p. 437.
10. Moffat JL. *Homoeopathic Therapeutics in Ophthalmology*. New Delhi: B. Jain Publishers (P) Ltd.; 1995. p. 129.
11. Boericke W. *Boericke's New Manual of Homoeopathic Materia Medica with Repertory*. 3<sup>rd</sup> Revised and Augmented ed. New Delhi: B. Jain Publishers (P) Ltd.; 2007. p. 383-6, 646.
12. Knerr CB. *Repertory of Hering's Guiding Symptoms of our Materia Medica*. Reprinted. New Delhi: Jain Publishing Co.; 1982. p. 322.
13. Boger CM. *Boenninghausen's Characteristic and Repertory*. New Delhi: B. Jain Publishers (P) Ltd; 1987. p. 309-13.
14. Kent JT. *Repertory of Homoeopathic Materia Medica*. New Delhi: B. Jain Publishers (P) Ltd.; 1989. p. 244.
15. Rutten L. Prognostic factor research in Homoeopathy. *Indian J Res Homoeopathy* 2016;10:59-65.
16. Van Haselen RA. Homoeopathic clinical case reports : Development of a supplement (HOM-CASE) to the care clinical case reporting guideline. *Complement Ther Med*. 2016;25:78-85.
17. Tassman IS. *The Eye Manifestations of Internal Diseases (Medical Ophthalmology)*. 3<sup>rd</sup> ed. St. Louis: CV Mosby Co.; 1951. p. 137.

### साक्ष्य आधारित होम्योपैथी: नॉड्युलर एपिस्क्लैराइटिस का एक केस रिपोर्ट

**परिचय:** नॉड्युलर एपिस्क्लैराइटिस (एनई) एक प्रकार का एपिस्क्लैराइटिस है जिसे सब-कंजक्टिवल कनेक्टिव ऊतक के प्रदाह द्वारा चिह्नित किया जा सकता है जिसके परिणामस्वरूप, हल्के दर्द और संवेदनशीलता के साथ एक स्थानिक, उठी हुई, संकुलित ग्रंथिका विकसित होती है। पुनरावृत्ति की प्रवृत्ति के साथ, यह कई सप्ताहों तक कायम रह सकता है और इसे प्रायः ही एन्डोजेनस टॉक्सिन के प्रति एक एलर्जिक प्रतिक्रिया के रूप में जाना जाता है। पारम्परिक उपचार में टॉपिकल स्टेरॉइड्स और नॉन-स्टेरॉइडल एन्टी-इंफ्लामेटरी औषधियों का उपयोग सम्मिलित है जो एक अस्थायी राहत प्रदान करता है। **सारांश:** पिछले 15 दिनों से अपने दांयी आँख में नॉड्युलर एपिस्क्लैराइटिस (एनई) से पीड़ित एक 62 वर्षीय पुरुष के केस की जिसे पारम्परिक उपचार से कोई लाभ नहीं मिला, की यहाँ पर रिपोर्ट की गयी। लक्षणों की सम्पूर्णता के आधार पर लिखी गई होम्योपैथिक औषधि, मर्क्युरियस सॉल्युबिलिस 30सी ने एक सप्ताह के अंदर नॉड्युलर एपिस्क्लैराइटिस (एनई) का समाधान कर दिया जिसकी 1 वर्ष और 4 माह तक कोई पुनरावृत्ति नहीं हुई। फोटोग्राफिक साक्ष्य के साथ, यह केस रिपोर्ट नॉन-रियुमाटॉइड एपिस्क्लैराइटिस में मर्क्युरियस सॉल्युबिलिस 30सी की प्रभावशीलता को प्रदर्शित करता है।

### Homéopathie factuelle: Un rapport de cas d'épisclérite nodulaire

**Introduction:** L'épisclérite nodulaire (NE) est un type d'épisclérite caractérisé par une inflammation du tissu conjonctif sous-conjonctival conduisant au développement d'un nodule localisé, surélevé et congestionné avec une douleur et une sensibilité légères. Elle peut durer des semaines avec une tendance à se reproduire et est souvent considérée comme une réaction allergique aux toxines endogènes. Le traitement conventionnel comprend l'utilisation de stéroïdes topiques et d'anti-inflammatoires non stéroïdiens qui procurent un soulagement temporaire. **Résumé de cas:** Le cas d'un patient de sexe masculin de 62 ans souffrant de NE dans l'œil droit pendant 15 jours ne répondant pas au traitement conventionnel est rapporté ici. Médecine homéopathique Mercurius solubilis 30C prescrit sur la base de la totalité des symptômes résolus NE en une semaine, sans récurrence pendant 1 an et 4 mois. Ce rapport de cas accompagné de preuves photographiques montre l'efficacité de Mercurius solubilis 30C dans l'épisclérite nodulaire non rhumatoïde.

### Título: Homoeopatía basada en evidencia: Un informe de caso de episcleritis nodular

**Introducción:** La episcleritis nodular (NE) es un tipo de episcleritis caracterizada por la inflamación del tejido conectivo subconjuntival que conduce al desarrollo de un nódulo localizado, elevado y congestionado con dolor leve y sensibilidad. Puede durar semanas con una tendencia a reaparecer y a menudo se considera como una reacción alérgica a las toxinas endógenas. El tratamiento convencional incluye el uso de esteroides tópicos y antiinflamatorios no esteroideos que dan un alivio temporal. **Resumen del caso:** Aquí se informa el caso de un paciente varón de 62 años que sufre de NE en el ojo derecho durante 15 días sin responder al tratamiento convencional. Medicina homoeopática Mercurius solubilis 30C prescrito sobre la base de la totalidad de los síntomas resueltos NE dentro de una semana, sin recurrencia durante 1 año y 4 meses. Este informe del caso con evidencia fotográfica muestra la eficacia de Mercurius solubilis 30C en episcleritis nodular no reumatoide.

## Evidenzbasierte Homöopathie: Ein Fallbericht über noduläre Episkleritis

**Einleitung:** Nodular episcleritis (NE) ist eine Art von Episcleritis, die durch eine Entzündung des subkonjunktivalen Bindegewebes gekennzeichnet ist, die zur Entwicklung eines lokalisierten, erhöhten, verstopften Knötchens mit leichten Schmerzen und Zärtlichkeit führt. Es kann wochenlang mit einer Tendenz zur Wiederholung dauern und wird oft als allergische Reaktion auf endogene Toxine betrachtet. Die konventionelle Behandlung umfasst die Verwendung von topischen Steroiden und nicht-steroidalen entzündungshemmenden Medikamenten, die eine vorübergehende Linderung geben. **Fallzusammenfassung:** Der Fall eines 62-jährigen männlichen Patienten, der 15 Tage lang am rechten Auge an NE litt und nicht auf eine konventionelle Behandlung reagierte, wird hier berichtet. Homöopathische Medizin Mercurius solubilis 30C wurde auf der Grundlage der Gesamtheit der Symptome gelöst. NE innerhalb einer Woche, ohne Wiederholung für 1 Jahr und 4 Monate. Dieser Fallbericht mit fotografischen Beweisen zeigt die Wirksamkeit von Mercurius solubilis 30C bei nicht-rheumatoider nodulärer Episkleritis.

### 循证同性恋：结节性表皮皮炎病例报告

**介绍:** 结节性巩膜炎 (NE) 是一种癫痫，其特征是亚结缔组织发炎，导致局部性发育，引起充血、疼痛和瘙痒。它可以持续数周，有复发的倾向，并经常被认为是内源性毒素的过敏反应。常规治疗包括使用局部类固醇和非类固醇抗炎药物，暂时缓解。 **案例摘要:** 这里报道了一名62岁的男性患者右眼患NE 15天，对常规治疗没有反应。同源药物默丘里鲁斯 30C 处方的基础上，症状在一个星期内解决 NE，1年4个月无复发。这份带照片证据的案例报告显示了默丘里鲁斯 30C 在非类风湿性结节性癫痫中的有效性。