

Chronic Cholelithiasis treated with Homoeopathic medicine in 50th millesimal potency: A case report

Amulya Ratna Sahoo, Madhusmita Patnaik*, Nilima Khamari, Somyaranjan Sahoo

Drug Proving Unit of Central Council for Research in Homoeopathy, Dr. Abhin Chandra Homoeopathic Medical College and Hospital, Unit-3, Bhubaneswar, Odisha, India

Abstract

Introduction: Cholelithiasis or gallstone disease is a very common problem worldwide. The prevalence is more in females than males. Although cholecystectomy is considered the gold standard treatment for symptomatic cholelithiasis, it has its own limitations, risks and post-operative complications. Here, an alternative system of medicine, especially Homoeopathy, plays an important role in treating cholelithiasis. **Case Summary:** A 32-year-old female patient presented with the symptoms of dull pain in the right hypochondrium, sour eructations and regurgitation of food. The ultrasonography (USG) report confirmed the presence of multiple stones in the gallbladder of varying sizes, from 3 mm to 11 mm. Although she was advised for cholecystectomy, she was reluctant to undergo any surgery. Detailed case was taken, case was analysed, totality was formed, repertorization was done and *Lycopodium* was prescribed in fifty millesimal potency. Her symptoms were alleviated within a short span of time, and USG reports revealed that there were no stones after 3 months of treatment. Homoeopathic medicine *Lycopodium*, selected on the basis of totality of symptoms, was found effective in this case.

Keywords: Cholecystitis, Cholelithiasis, Gall bladder, Homoeopathy, *Lycopodium*

INTRODUCTION

Gallstone disease refers to the presence of stones in the gall bladder (GB) (cholelithiasis) or common bile duct (choledocholithiasis) and the symptoms and complications they cause.^[1] Cholelithiasis and its associated complications such as cholecystitis, pancreatitis and cholangitis are one of the major health problems worldwide.^[2] Chronic cholecystitis is almost invariably associated with gallstones.^[3] The imbalance of the chemical constituents of bile results in precipitation of one or more of the components and ultimately forms gall stones. Nearly 37%–86% of gallstones are cholesterol-rich stones, 2%–27% are pigment stones and 4%–16% are mixed stones.^[4,5] Different epidemiological studies have suggested a wide variation in the overall prevalence between different populations. The prevalence of gallstones increases with age, rising markedly after the age of 40 years. Older people are 4–10 times more likely to have gall stones than younger people.^[5,6] Gallstones are frequently found in people of high socioeconomic status and in multiparous females.^[7] In addition, patients with cholelithiasis have significantly higher BMI in comparison to the common population.^[8] Female gender is

one of the major risk factors of cholelithiasis. In comparison to men, women have two to three times higher prevalence of gallstones.^[4,9] Pregnancy is also a major risk factor for cholelithiasis. Sex hormones are mostly responsible for the increased risk as oestrogen increases biliary cholesterol secretion, causing cholesterol supersaturation in the bile.^[9] Chronic calculus cholecystitis commonly presents with recurrent attacks of upper abdominal pain.^[3]

Liver function tests and abdominal ultrasound are the suggested investigational procedures in suspected gallstone disease.^[4] Cholecystectomy is the main choice of treatment in symptomatic gallstone cases, and laparoscopic cholecystectomy (LC) is the widely accepted operative management of gallstone disease

***Address for correspondence:** Dr. Madhusmita Patnaik, Drug Proving Unit of Central Council for Research in Homoeopathy, At- Dr. Abhin Chandra Homoeopathic Medical College and Hospital, Unit-3, Bhubaneswar - 751 001, Odisha, India. E-mail: dr.madhusmita.patnaik@gmail.com

Received: 02.03.2019; **Accepted:** 18.02.2020; **Published:** 09.04.2020.

Access this article online

Quick Response Code:



Website:
www.ijrh.org

DOI:
10.4103/ijrh.ijrh_15_19

This is an open access journal, and articles are distributed under the terms of the Creative Commons Attribution-NonCommercial-ShareAlike 4.0 License, which allows others to remix, tweak, and build upon the work non-commercially, as long as appropriate credit is given and the new creations are licensed under the identical terms.

For reprints contact: reprints@medknow.com

How to cite this article: Sahoo AR, Patnaik M, Khamari N, Sahoo S. Chronic Cholelithiasis treated with Homoeopathic medicine in 50th millesimal potency: A case report. *Indian J Res Homoeopathy* 2020;14:57-63.

worldwide. However, there are patients who are either reluctant to undergo surgery or are at high surgical risk.^[10] In addition, LC has some disadvantages as it may lead to common bile duct and bowel injury (2.6%), post-operative bile leak (2.3%), stone spillage (2%), post-operative colonic fistula (0.3%), post-operative biliary fistula (0.3%) or post-operative haemorrhage (0.3%) in some cases.^[11]

Here, Homoeopathy plays an important role in combating the sufferings due to gallstone disease. There are several medicines in the homoeopathic Materia medica which can be considered for gall stone disease; some prominent medicines are *Berberis vulgaris*, *Calcarea carbonica*, *Carduus marianus*, *China*, *Chamomilla*, *Chionanthus*, *Lycopodium*, *Veratrum album*, etc.^[12] However, there are very few studies found in literature, which show positive result of well-selected individualised homoeopathic medicines in these conditions.^[13,14] In this context, the main objective of this case report is to show the effectiveness of individualised homoeopathic medicine in the treatment of this often dreaded condition, usually or considered surgical, with further stress on the necessity of more research in this field.

CASE REPORT

A female of moderate built, aged about 32 years, came to the outpatient department of Dr. A. C. Homoeopathic Medical College and Hospital on 24 September 2018.

She complained of dull pain in the right hypochondriac region which was aggravated about 30 min after lunch. She also complained of eructations, which were sour and were associated with regurgitation of food. The complaints started gradually about 3 months back. At first, the patient had consulted an allopathic physician who advised her for ultrasonography (USG) of the whole abdomen. On USG, multiple calculi of about 3–9 mm were seen in the GB lumen, with increased thickness of GB wall (3–5 mm) [Table 1 and Figure 1]. The doctor advised her to undergo cholecystectomy, but the patient was reluctant to undergo any surgery and came for homoeopathic treatment, as the discomfort gradually increased. In the past, she had suffered from typhoid 1 year back. She had a family history of hypertension (father). The patient was married, had two kids and belonged to good socioeconomic background. No addictions were reported. In the physical generals, her appetite was good. She had a desire for warm and salty food. Thirst was normal. She reported profuse sour perspiration especially on the head, palms and

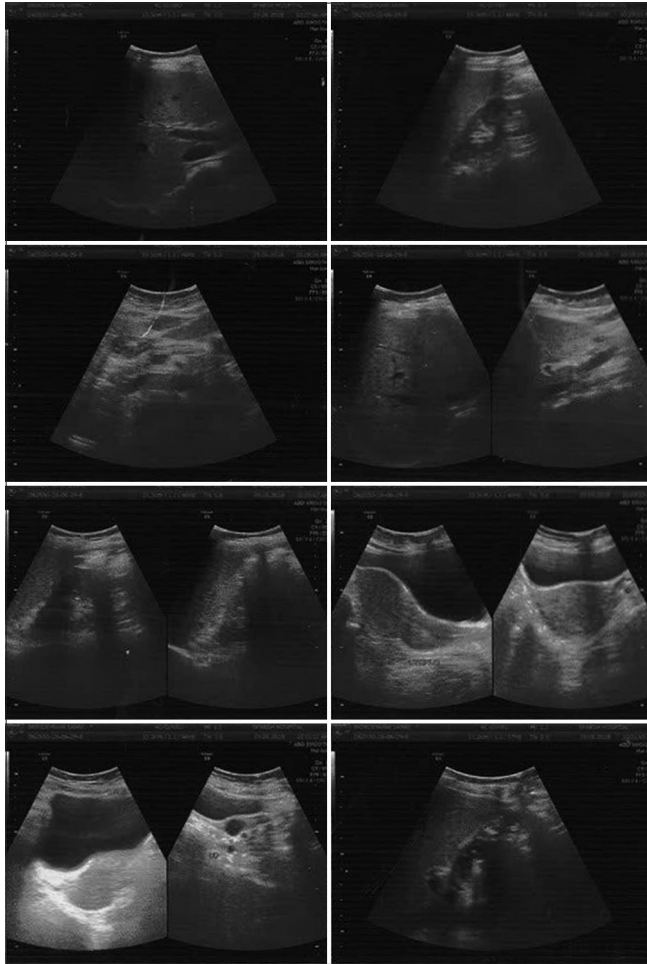


Figure 1: Ultrasonography film before treatment

Normal		Repertorisation														
		Lyc	Nat-m	Phos	Ars	Bry	Calc	Carb-v	Puls	Sulph	Caus	Nit-ac	Verat	Sep	Sil	Arg-n
Symptoms Covered		25	21	21	20	20	20	20	19	19	18	18	18	18	17	17
Totally		10	9	8	9	9	9	9	8	8	9	9	9	8	10	8
[C] [Mind]Irritability:		3	3	3	3	3	3	3	3	3	3	3	2	3	3	2
[C] [Mind]Fear:Alone, of being:		3	1	3	3	1	1	1	2		1	1	1	2	1	3
[C] [Mind]Weeping, tearful mood:Tendency:		3	3	2	1	2	3	2	3	3	3	2	3	3	1	2
[C] [Generalities]Cold:Amel.:		2	2	2	1	2	1	1	3	2	1	1	1	1	1	2
[C] [Generalities]Food and drinks:Warm:Food:Desires:		2			3	2										1
[C] [Generalities]Food and drinks:Salt or salty food:Desires:			3	3			2	3		1	2	3	3		1	3
[C] [Perspiration]Profuse:		3	3	2	3	3	3	3	2	2	2	2	3	3	3	1
[C] [Perspiration]Odor:Sour:		3	1		3	3	2	2	1	3	2	3	3	3	3	
[C] [Abdomen]Pain:Dull:Hypochondria:Right:																
[C] [Stomach]Eructations:General:Gall stones, with:		1														
[C] [Stomach]Eructations:Sour:		3	3	3	2	2	3	3	2	3	2	2	1	2	2	2
[C] [Stomach]Eructations:Food, of, regurgitation:		2	2	3	1	2	2	2	3	2	2	1	1	1	1	2

Figure 2: Repertorisation chart

Table 1: Ultrasonography report before treatment

Organs	Findings
Liver	Normal in size (13.7 cm) and shape. Normal parenchymal echo seen. Intrahepatic biliary channels normal in calibre and contains no echogenic structure. Portal hepatic vascular systems within normal limits. P.V measures 8.6 mm
Gall bladder	Normal in size, shape and position. Wall thickness increased (3.5 mm). Multiple calculi seen in gall bladder lumen of about 3-9 mm, casting posterior acoustic shadows. No pericholecystic collection is noted
CBD	Common duct is normal in calibre (3.1 mm). Lumen is clear
Spleen	Normal in size, shape and parenchymal echotexture. Spleen measures 9.8 cm. Splenic vein is normal
Pancreas	Normal in size, shape and parenchymal echotexture. Pancreatic duct not dilated
Kidney	Both the kidneys are normal in size, shape and position. Renal cortical echotexture is normal with prominent pyramids. Corticomedullary differentiation maintained. No evidence of any calculus or hydronephrosis. Pelvi-calyceal systems appear normal. RK is 10.0 cm×3.8 cm LK is 10.1 cm×5.1 cm
Urinary bladder	Symmetrical and normal in outline. Lumen is clear. Walls are normal in thickness
Uterus	Bulky in size - 10.0 cm×6.0 cm×4.7 cm. Myometrial echopatten is normal. Endometrium is normal in size and echopattern (6.2 mm). Cx normal. No fluid POD/lymphadenopathy
Ovaries	Right ovary is not visualised. Left ovary is normal in size and echopattern LO - 4.0 cm×1.4 cm No retroperitoneal adenopathy or ascitis seen
Impression	R.I.F:- No mass/collection are noted. Appendix is not visualized Chronic calculus cholecystitis Bulky uterus

Table 2: Symptoms forming the totality

Symptoms

- Irritability
- Fear of being alone
- Tendency to weep easily
- Hot patient, generally ameliorated from cold
- Desire for warm food and salty food
- Profuse, sour perspiration
- Dull pain in the right hypochondrium
- Eruclatations sour with regurgitation of food
- Eruclatations in gall stone disease

soles. She was found to be a hot patient and generally got relief from cold. Mentally, she was irritable, afraid of being alone and had a tendency to weep easily. On local and systemic examination, no significant abnormalities were found, except mild tenderness in the right hypochondrium.

While analysing the case, the general and particular symptoms were classified as per the intensity and evaluated as per their merit. Characteristic mental generals, physical generals, particulars and a few diagnostic symptoms were considered for erecting the totality of symptoms [Table 2]. Considering the totality, complete repertory was selected and repertorisation was done with HOMPAT software.^[15] After repertorisation, from the list of drugs [Figure 2], *Lycopodium* was selected after further confirmation from Materia medica. It was prescribed in fifty millesimal potency; 0/3, followed by 0/4, 16 doses each, one dose daily in the morning on empty stomach, and the patient was asked to report after 1 month.

The patient reported next on 1 December 2018, almost about 2 months after the first visit, and narrated that there was a gradual reduction of symptoms during this while and even after the medicine was finished, so she did not turn up for follow-up

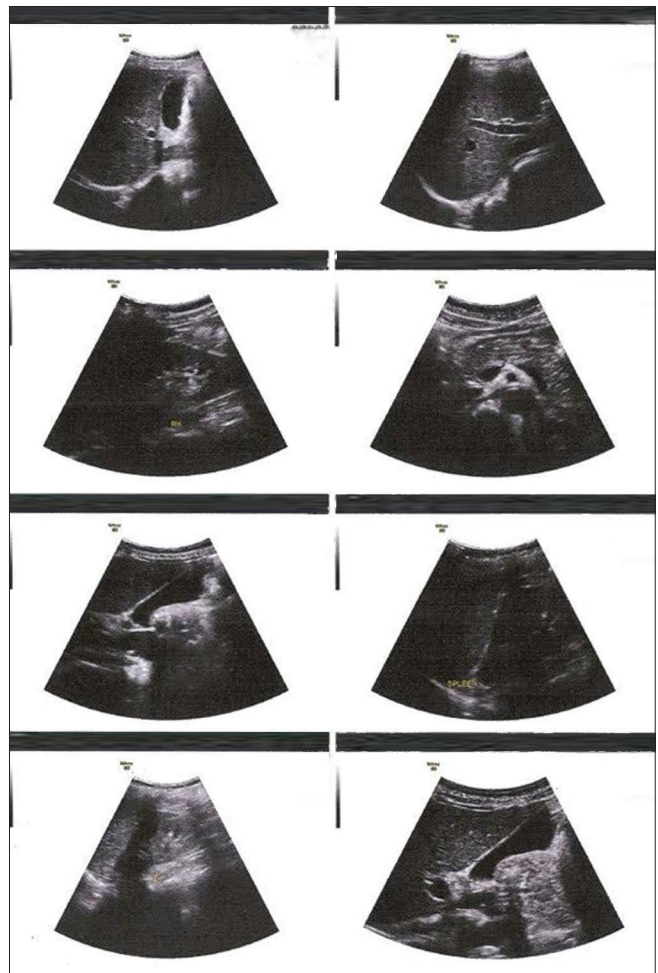


Figure 3: Ultrasonography film after treatment

the last month. However, the pain and eruclatations increased recently after attending a family feast and taking fat-rich diet,

but the intensity was much less than before. *Lycopodium* was prescribed again in 0/5 and 0/6 potency, 16 doses each, one dose daily. The patient reported next time on 4 January 2019, and at that time, she had no signs or symptoms [Table 3]. She was advised USG of the abdomen, which showed normal GB without any stones [Table 4 and Figure 3]. She was very elated as she was completely cured. She said that she had heard that Homoeopathy cures gall stones, but had never expected complete recovery in such a short span of time and hence, she was very grateful.

DISCUSSION

This is the case of a 32-year-old female. As per the literature, multiparous women are more susceptible to gall stone disease

and this case also substantiates it. The socioeconomic status of the patient was good, which also corroborates with the risk factors mentioned in the literature. While the moderate built of the patient contradicts the fact that cholelithiasis is mostly found in people with high BMI, there is very limited scope for conservative treatment of cholelithiasis in conventional system of medicine, and it has its own limitations. In this case, the patient was apprehensive about any surgical procedure. Hence, she opted for an alternative system of medicine, though advised for cholecystectomy by the allopathic physician.

Homoeopathy is a system of therapeutics which treats the patient, not the disease. It also aims at a rapid, gentle and permanent restoration of health.^[6] Homoeopathic medicines can be selected on the basis of causation, prominent modality, organopathy, miasm, constitution, totality of the symptoms, etc.^[7] In this case, there were significant mental, physical, particular and pathological symptoms. Hence, the case was approached with importance to totality of symptoms. The clarity of the symptoms in this case facilitated easy selection of the medicine. In this case, after repertorisation, *Lycopodium*, *Natrum Muriaticum*, *Phosphorus*, *Arsenic album*, *Bryonia*, *Calcarea carbonica* and *Carbo Vegetabilis* emerged as the leading remedies. *Lycopodium* was selected as it covered more number of symptoms and also was in accordance with *Materia medica*, which suggests its efficacy in relieving gall stone colic and in dissolving gall stones.^[8] The swift relief of symptoms indicates the efficacy of Homoeopathy in the treatment of gall stone disease, without draining the patient physically, mentally and financially. Disappearance of gall stones on USG is definitely a documentary evidence of cure. Here, *Lycopodium* was selected on the basis of totality of symptoms. The modified Naranjo criteria score of the patient after treatment was '9', which indicates there is a definite relationship between the result observed and the prescribed

Table 3: Follow up

Date	Symptoms	Investigation report	Medicine prescribed
24 th September 2018	Dull pain in the right hypochondrium Sour eructations Eructations with regurgitation of food	USG of the abdomen showed multiple calculi in GB lumen of about 3-9 mm with increased thickness of walls (3-5 mm)	<i>Lycopodium</i> 0/3, 0/4, 16 doses each, One dose daily in the morning, on empty stomach
1 st December 2018	Pain and eructations reduced		<i>Lycopodium</i> 0/5, 0/6, 16 doses each, One dose daily in the morning, on empty stomach
4 th January 2019	No symptoms	USG abdomen showed normal shape, size and position of gallbladder without any calculi	

USG: Ultrasonography, GB: Gall bladder

Table 4: Ultrasonography report after treatment

Organs	Findings
Liver	Normal in size (12.0 cm) and shape. Normal parenchymal echo seen. Intrahepatic biliary channels normal in caliber and contains no echogenic structure. Portal hepatic vascular systems within normal limits. P.V measures 8.8 mm
Gall bladder	Normal in size, shape and position. Walls smooth, regular and normal in thickness (1-2 mm). Lumen is clear. No pericholecystic collection is noted
CBD	Common duct is normal in caliber (7.0 mm). Lumen is clear
Spleen	Normal in size, shape and parenchymal echotexture. Spleen measures 8.2 cm. Splenic vein is normal
Pancreas	Normal in size, shape and parenchymal echotexture. Pancreatic duct not dilated.
Kidney	Both the kidneys are normal in size, shape and position. Renal cortical echotexture is normal with prominent pyramids. Corticomedullary differentiation maintained. No evidence of any calculus or Hydronephrosis. Pelvicalyceal systems appear normal. RK is 9.8 cm×4.4 cm LK is 8.9 cm×4.4 cm
Urinary bladder	Symmetrical and normal in outline. Lumen is clear. Wall are normal in thickness
Uterus	Bulky in size - 9.7 cm×4.4 cm×4.0 cm. Myometrial echopatten is normal. Endometrium is normal in size and echo pattern (6.7 mm). Cx normal. No fluid POD/lymphadenopathy
Ovaries	Right ovary is not visualised. Left ovary is normal in size and echo pattern. LO - 3.6 cm×1.8 cm No retroperitoneal adenopathy or ascitis seen R.I.F:- No mass/collection are noted. Appendix is not visualised
Impression	Bulky uterus No other significant abnormality detected

Table 5: Modified Naranjo Criteria scores of the patient after treatment

Serial number	Modified Naranjo criteria	Answers of the patient	Scores
1	Was there an improvement in the main symptom or condition for which the homoeopathic medicine was prescribed?	Yes	+2
2	Did the clinical improvement occur within a plausible timeframe relative to the medicine intake?	Yes	+1
3	Was there an initial aggravation of symptoms?	No	0
4	Did the effect encompass more than the main symptom or condition (i.e. were other symptoms ultimately improved or changed)?	Yes	+1
5	Did overall well-being improve?	Yes	+1
6a	<i>Direction of cure:</i> did some symptoms improve in the opposite order of the development of symptoms of the disease?	Not Sure	0
6b	<i>Direction of cure:</i> did at least two of the following aspects apply to the order of improvement of symptoms: From organs of more importance to those of less importance From deeper to more superficial aspects of the individual From the top downwards	Not sure	0
7	Did “old symptoms” (defined as non-seasonal and non-cyclical symptoms that were previously thought to have resolved) reappear temporarily during the course of improvement?	No	0
8	Are there alternative causes (other than the medicine) that -with a high probability - could have caused the improvement? (consider known course of disease, other forms of treatment and other clinically relevant interventions)	No	+1
9	Was the health improvement confirmed by any objective evidence? (e.g., lab test, clinical observation, etc.)	Yes	+2
10	Did repeat dosing, if conducted, create similar clinical improvement?	Yes	+1
Total			+9

medication [Table 5].^[19,20] A case report published earlier had also showed that well-selected individualised homoeopathic medicine prescribed on the basis of totality of symptoms was effective in treating gall stone disease.^[14] This report resonates with the previous one.

CONCLUSION

This case shows that individualised homoeopathic treatment based on the totality of symptoms is effective in the treatment of gall stone disease. Disappearance of the signs and symptoms within a short span of time along with USG evidence of absence of stone definitely demonstrates the positive effect of Homoeopathy in the treatment of gall stone. However, this is just a single case report and research evidence in this regard is very poor. Hence, clinical trials to evaluate the efficacy of homoeopathic medicine in gall stone disease are suggested.

Declaration of patient consent

The authors certify that they have obtained all appropriate patient consent forms. In the form, the patient has given her consent for her images and other clinical information to be reported in the journal. The patient understands that her name and initial will not be published, and due efforts will be made to conceal identity, but anonymity cannot be guaranteed.

Financial support and sponsorship

Nil.

Conflicts of interest

None declared.

REFERENCES

1. Team IC. Gallstone Disease: Diagnosis and Management of Cholelithiasis, Cholecystitis and Choledocholithiasis. UK: National Institute for Health and Care Excellence; 2014.
2. Shaffer EA. Gallstone disease: Epidemiology of gallbladder stone disease. *Best Pract Res Clin Gastroenterol* 2006;20:981-96.
3. Innes JA, editor. Liver and biliary tract disease. In: Davidson's Essentials of Medicine. Edinburgh: Elsevier Limited; 2009.
4. Lee JY, Keane MG, Pereira S. Diagnosis and treatment of gallstone disease. *Practitioner* 2015;259:15-9, 2.
5. Njeze GE. Gallstones. *Niger J Surg* 2013;19:49-55.
6. Stinton LM, Shaffer EA. Epidemiology of gallbladder disease: Cholelithiasis and cancer. *Gut Liver* 2012;6:172-87.
7. Singh V, Trikha B, Nain C, Singh K, Bose S. Epidemiology of gallstone disease in Chandigarh: A community-based study. *J Gastroenterol Hepatol* 2001;16:560-3.
8. Frybova B, Drabek J, Lochmannova J, Douda L, Hlava S, Zemkova D, *et al.* Cholelithiasis and choledocholithiasis in children; risk factors for development. *PLoS One* 2018;13:e0196475.
9. Novacek G. Gender and gallstone disease. *Wien Med Wochenschr* 2006;156:527-33.
10. Pruthi HS, Varadarajulu R. Treatment of gallstones – What is the right choice. *Med J Armed Forces India* 1999;55:1-2.
11. Kapoor M, Yasir M, Umar A, Suri A. Complications of laparoscopic cholecystectomy, an analysis of 300 patients. *JK Pract* 2013;18:7-11.
12. Boericke W. *New Manual of Homoeopathic Materia Medica with Repertory*. 3rd ed. New Delhi: B. Jain Publishers (P) Ltd.; 2011.
13. Pathak R. A cured case of cholelithiasis with homeopathic medicines. *Clin Exp Homoeopath* 2018;5:27-9.
14. Ghosh MS, Shil RC, Chakma A. A case of gallstone with prostatomegaly. *Indian J Res Homoeopath* 2014;8:231-5.
15. Shah JJ. *Homopath Classic- Homeopathic Software*. Version 8.0 Premium. Mumbai: Mind technologies private limited; 2005.
16. Hahnemann S, Boericke W, Dudgeon RE. *Organon of Medicine*. 5th, 6th ed. New Delhi: B. Jain Publishers Pvt. Ltd.; 2011.
17. Mathur KN, Wadia SR. *Principles of Prescribing*. New Delhi: B. Jain Publishers Pvt. Ltd.; 1998.
18. Kent JT. *Lectures on Homoeopathic Materia Medica*. New Delhi: B.

- Jain Publishers Pvt. Ltd.; 1971.
19. Rutten L. Prognostic factor research in Homoeopathy. *Indian J Res Homoeopath* 2016;10:59-65.
20. van Haselen RA. Homeopathic clinical case reports: Development of a supplement (HOM-CASE) to the CARE clinical case reporting guideline. *Complement Ther Med* 2016;25:78-85.

पुरानी कोलेलिथियासिस का इलाज होम्योपैथिक दवा (50 वीं मिलिसिमल) से उपचारित : एक केस विवरण

परिचय: दुनिया भर में कोलेलिथियासिस या पित्ताशय की बीमारी एक बहुत ही आम समस्या है। पुरुषों की तुलना में महिलाओं में इसका प्रचलन अधिक है। यद्यपि कोलेलिथिस्टेक्टोमी को रोगसूचक कोलेलिथियासिस के लिए स्वर्णमानक उपचार के रूप में माना जाता है, इसकी अपनी सीमाएं, जोखिम और पश्चात की जटिलताएं हैं। यहां, दवा की एक वैकल्पिक प्रणाली, विशेष रूप से होम्योपैथी, कोलेलिथियासिस के इलाज में एक महत्वपूर्ण भूमिका निभाती है।

मामले का सारांश: एक 32 वर्षीय महिला रोगी के दाहिने हाइपोकोण्ड्रियम में हल्के दर्द, खट्टी उकारें आना और भोजन का पुनरुत्थान जैसे लक्षणों के साथ उपचार के लिये आई। अल्ट्रासोनोग्राफी रिपोर्ट ने पित्ताशय में विभिन्न आकारों जैसे 3 मिमी से 11 मिमी तक की पथरियों की उपस्थिति की पुष्टि की। यद्यपि उसे कोलेलिथिस्टेक्टोमी के लिए सलाह दी गई थी, वह कोई भी शल्यचिकित्सा करवाने के लिए अनिच्छुक थी। विस्तार से रोगी के लक्षणों को विस्तृत रूप से लेकर विश्लेषण, समग्रता का गठन और, पुनर्मूल्यांकन किया गया व *लाइकोपोडियम* को पचास मिलिसिमल शक्ति में निर्धारित किया गया। थोड़े समय के भीतर उसके लक्षणों में कमी पाई गई और अल्ट्रासोनोग्राफी रिपोर्ट से पता चला कि 3 महीने के उपचार के बाद कोई पथरी पाई गई। लक्षणों की समग्रता के आधार पर चुनी गई होम्योपैथिक दवा *लाइकोपोडियम* इस मामले में प्रभावी पाई गई।

Cholélithiase chronique traitée avec un médicament homéopathique du 50^e millénaire: un rapport de cas

Introduction: La cholélithiase ou maladie de lithiase biliaire est un problème très courant dans le monde. La prévalence est plus élevée chez les femmes que chez les hommes. Bien que la cholécystectomie soit considérée comme le traitement de référence pour la cholélithiase symptomatique, elle a ses propres limites, risques et complications postopératoires. Ici, le système alternatif de médecine, en particulier l'homéopathie, joue un rôle important dans le traitement de la cholélithiase.

Résumé du cas: Une patiente de 32 ans a présenté des symptômes de douleur sourde dans l'hypochondre droit, des éructations acides et une régurgitation des aliments. Le rapport d'échographie a confirmé la présence de plusieurs calculs dans la vésicule biliaire de tailles variables; de 3 mm à 11 mm. Bien qu'elle ait été conseillée pour une cholécystectomie, elle hésitait à subir une intervention chirurgicale. Un cas détaillé a été pris, le cas a été analysé, la totalité a été formée, la repertorisation a été effectuée et *Lycopodium* a été prescrit en cinquante millièmes de puissance. Ses symptômes ont été atténués en peu de temps et les rapports d'échographie ont révélé qu'il n'y avait pas de calculs après 3 mois de traitement. Le médicament homéopathique *Lycopodium*, sélectionné sur la base de la totalité des symptômes, s'est révélé efficace dans ce cas.

Colelitiasis crónica tratada con un medicamento homeopático en potencia Q (50 milesimal): Informe de caso clínico

Introducción: La colelitiasis olitiasis biliar es un problema muy común en todo el mundo. La prevalencia es mayor en mujeres que en hombres. Si bien la colestectomía se considera como tratamiento de referencia en la colelitiasis sintomática, esta intervención presentasus propias limitaciones, sus riesgos y sus complicaciones posoperatorias. En este contexto, la medicina alternativa, en especial la homeopatía, desempeña un papel importante en el tratamiento de la colelitiasis.

Resumen del caso: Una mujer de 32 años presentaba síntomas de dolor sordo en el hipocondrio derecho, eructos ácidos y regurgitación de alimentos. Por ecografía, se confirmó la presencia de múltiples piedras en la vesícula biliar de varios tamaños desde 3 mm a 11 mm. Pese a que se indicara una colestectomía, la paciente era reacia a someterse a una intervención quirúrgica. El caso se tomó y analizó detenidamente y, a partir de la totalidad de los síntomas, se efectuó una repertorización que llevó a la prescripción de *Lycopodium* en potencia Q (50 milesimal). Sus síntomas se aliviaron en poco tiempo y el informe ecográfico reveló que, tras 3 meses de tratamiento, ya no había piedras. El medicamento homeopático *Lycopodium*, seleccionado sobre la base de la totalidad de los síntomas, fue eficaz en este caso.

Chronische Cholelithiasis, die mithomöopathischer 50. Jahrtausend-Medizin behandelt wird: Ein Fallbericht

Einführung: Die Cholelithiasis oder Gallensteinerkrankung ist ein weltweit sehr häufiges Problem. Die Prävalenz ist bei Frauen stärker ausgeprägt als bei Männern. Obwohl die Cholezystektomie als Goldstandard für die Behandlung der symptomatischen Cholelithiasis gilt, hat sie ihre eigenen Grenzen, Risiken und postoperativen Komplikationen. Hier spielt die alternative Medizin, insbesondere die Homöopathie, eine wichtige Rolle bei der Behandlung der Cholelithiasis.

Fallzusammenfassung: Eine 32-jährige Patientin stellte sich mit den Symptomen von dumpfen Schmerzen im rechten Hypochondrium, sauren Eructationen und Regurgitation von Nahrung vor. Der Ultraschallbericht bestätigte das Vorhandensein mehrerer Steine in der Gallenblase unterschiedlicher Größe; von 3 mm bis 11 mm. Obwohl eine Cholezystektomie empfohlen wurde, zögerte sie, sich einer Operation zu unterziehen. Es wurde ein detaillierter Fall genommen, der analysiert, die Totalität wurde gebildet, die Repertorisation wurde durchgeführt und *Lycopodium* in f fünfzig Millesimal Potenz verschrieben. Ihre Symptome wurden innerhalb kurzer Zeit gelindert, und die Ultraschallberichte zeigten, dass nach 3 Monaten Behandlung keine Steine mehr vorhanden waren. Das homöopathische Medikament *Lycopodium*, das auf der Grundlage der Gesamtheit der Symptome ausgewählt wurde, erwies sich in diesem Fall als wirksam.

順勢療法LM層級藥物治療慢性膽石：個案報告

引言：膽石症或膽石疾病是全世界非常普遍的問題，女性患病率高於男性。儘管膽囊切除術被認為是症狀性膽石症的黃金標準治療，但它有其自身的限制、風險和手術後併發症。在這一點上，另類醫學體系，特別是順勢療法，在治療膽石症方面發揮著重要作用。

個案總結：一名32歲女性患者呈現右側季肋部隱隱作痛、噯酸及食物反流症狀。超聲報告證實膽囊內有多處大小不一的結石，從3毫米到11毫米不等。儘管有人建議她做膽囊切除術，但她不願意做任何手術。詳細問症後分析個案，得到整體性，進行療劑彙集分析，以LM層級處方石松。她的症狀在短時間內得到緩解，超聲波報告顯示治療3個月後沒有結石。根據整體症狀選擇的順勢療法藥物石松，在本個案中是有效的。