

Case Report

Diabetic foot

Dr. Mohd. Shahid Ali*

53 years old, male. (Reg. No. 1169/2004-05)

Diagnosis: Diabetic foot

Presenting complaints

27.7.2004

The patient came with complaints of:

1. Ulcer in the left foot.
2. Drawing pain in calves > pressure, < morning and ambulating

The complaint of the Ulcer started after a shoe-scratch following abrasion.

It was followed by swelling and watery discharge.

Past treatment

For about six months- Antibiotics/Ayurvedic treatment was taken.

Physical

Prefers cold bathing, hot food, seasonal fanning, and chilled drinks

Great desire for sweets.

Appetite good; easy satiety.

Bowels: regular satisfactory.

Perspiration: generalized and only upon exertion.

Mind

Great anxiety for health,

Has constant job stress

Worry about family (because he is staying away from family)

Family history

Two sisters and one brother are having Diabetes

Examination

Slightly Anaemic; BP – 130/80; Pulse- 74 per minute, regular.

Investigation

Lung sounds and heart sounds were clear.

Higher mental function- normal

Signs of bilateral neuropathy of lower limbs - present.

Repertorial totality (Kent)

1. Anxiety about health (Mind)
2. Desire sweets (Stomach)
3. Appetite easy satiety (Stomach)
4. Ulcer foot sole (Extremities)
5. Ulcer lower limb, painless (Extremities)
6. Ulcer lower limb, running and oozing (Extremities)
7. Pain drawing leg, calf < walking (Extremities)

* Assistant Research Officer (H), Extension Clinical Research Unit of D.S.U., Hyderabad.

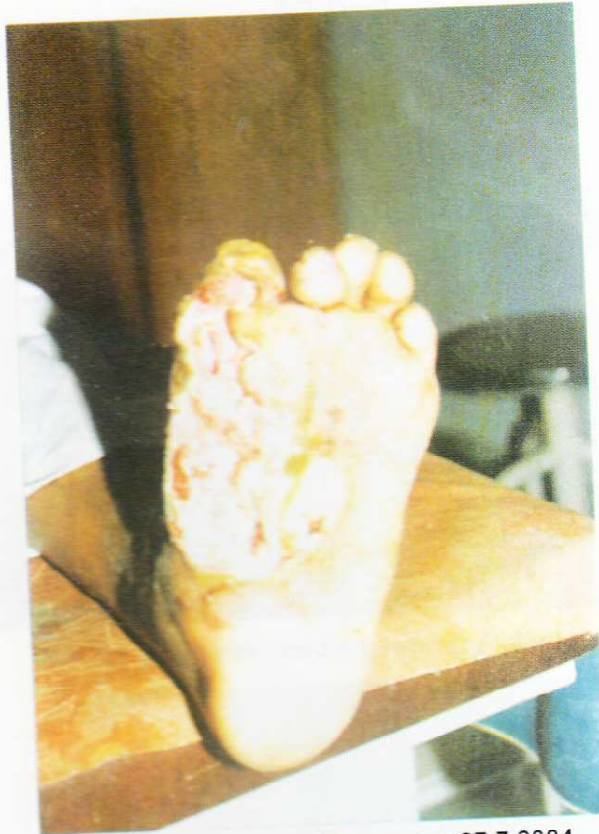


Fig. 1. A view of the Ulcer as on 27.7.2004
(Before treatment)

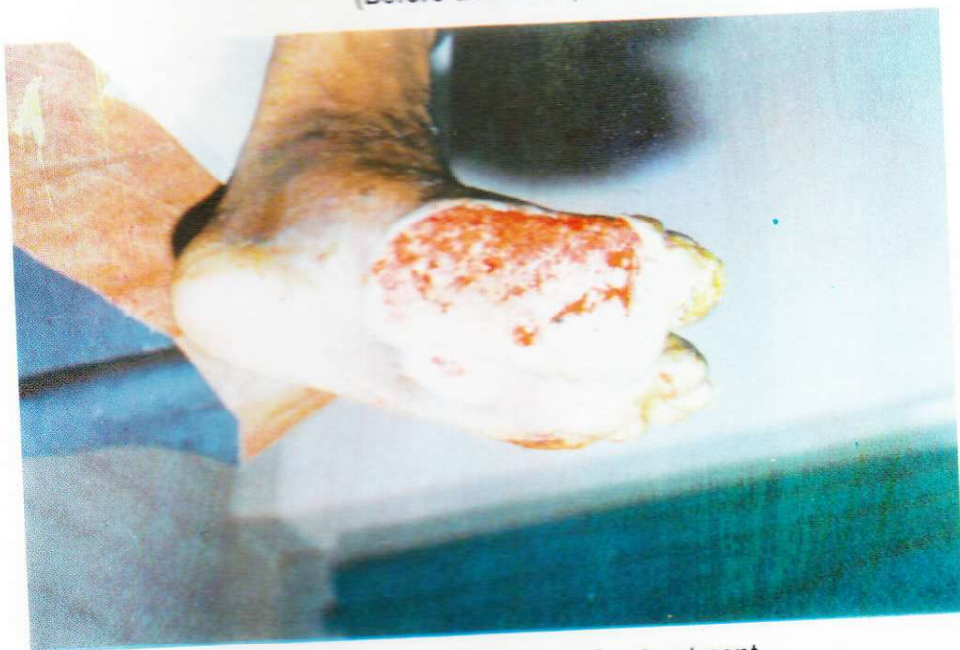

Fig. 2. A view of the Ulcer during treatment

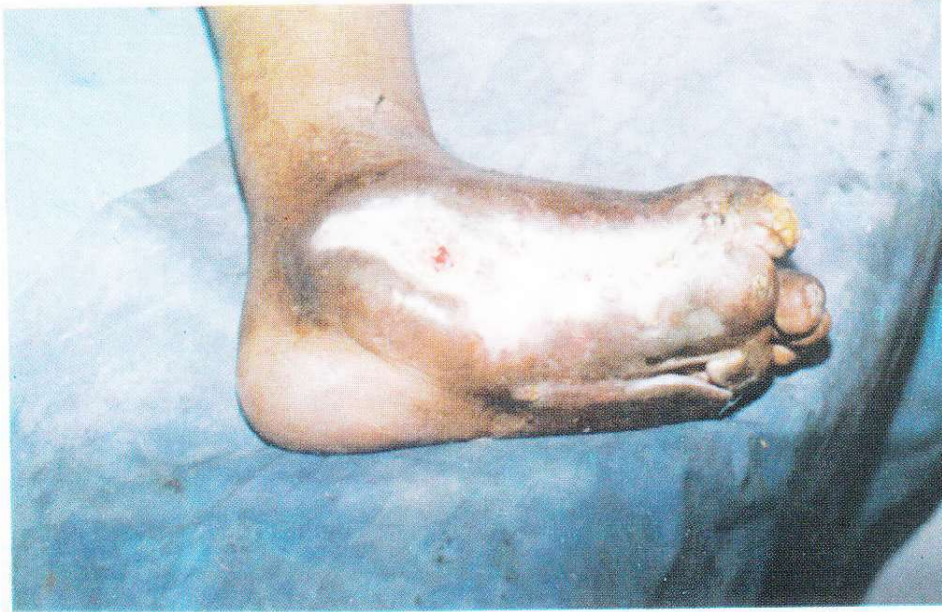

Fig. 3. A view of the Ulcer during treatment

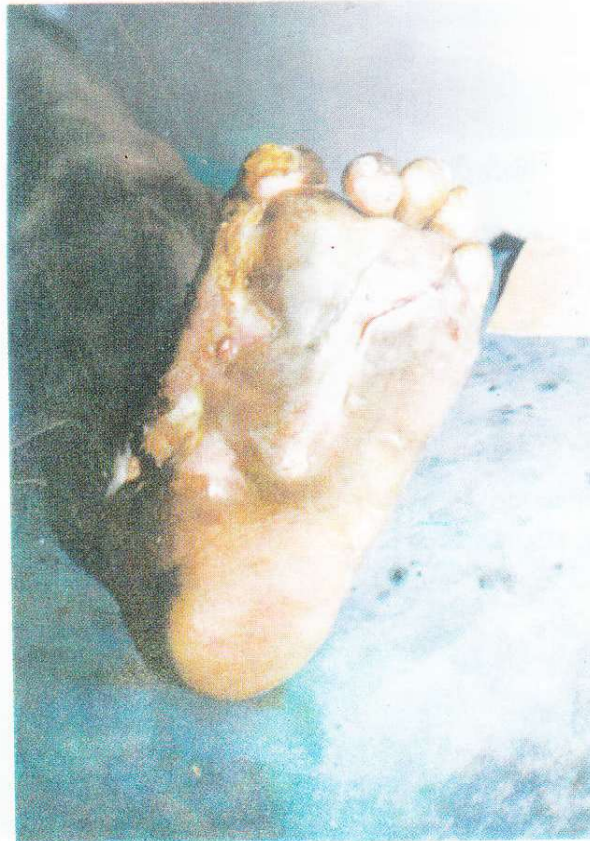

Fig. 4. A view of the Ulcer after two months of treatment

Prescription

Sulphur 30- frequent doses

Follow up

10.8.2004

Feeling better in respect of local/general symptoms

Rx Sulphur 30- three doses

Placebo

17.8.2004

Feeling better in respect of local/general symptoms

Rx Placebo for three weeks

8.9.2004

Enormous improvement reported with clear healing

Rx Sulphur 200

Placebo for three weeks

29.9.2004

Ulcer was totally healed.

Rx Sulphur IM one dose was given

Conclusion

The patient was kept on oral hypoglycemic drugs from allopathic side and regular wound dressing was done with Calendula external under strict aseptic conditions with the able guidance of a Surgeon.

The patient is still under the Surgeon's observation and regular homoeopathic follow up.