

CASE REPORT

An evidence-based case of acoustic/ vestibular schwannoma

Girish Gupta, Naveen Gupta, Dileep Pandey

ABSTRACT

A vestibular schwannoma, often called an acoustic neuroma/schwannoma, is a benign primary intracranial tumor of the myelin-forming cells of the vestibulo-cochlear nerve (8th cranial nerve). This tumor arises from the Schwann cells responsible for the myelin sheath that helps keep peripheral nerves insulated.^[1] Approximately, 3000 cases are diagnosed each year in the United States with a prevalence of about 1 in 100,000 worldwide. It comprises 5–10% of all intracranial neoplasms in adults. Incidence peaks in the fifth and sixth decades and both sexes are affected equally. Studies in Denmark published in 2004 show the incidence of 17.4/million. Most acoustic neuromas are diagnosed in patients between the ages of 30 and 60, and men and women appear to be affected equally.^[2] The case illustrated here is a rare one of acoustic/vestibular schwannoma a surgical conditions, treated with *Lycopodium*, which produced improvement on both subjective and objective parameters.

Keywords: Acoustic neuroma/schwannoma, Homoeopathic medicine, *Lycopodium*, Intra cranial tumour

INTRODUCTION

Acoustic/vestibular schwannoma develops gradually over a period of years, growing at a rate of roughly 1–2 mm each year. Most often, it may not manifest any obvious symptoms in the earlier stages. As a result, many patients with this tumor often fail to recognize any symptom in the initial stage. The earliest symptoms of acoustic neuromas include ipsilateral sensorineural hearing loss/deafness (i.e. impairment or loss of hearing on the same side in relation to the side of occurrence of schwannoma), disturbed sense of balance and altered gait, vertigo with associated nausea and vomiting and pressure in the ear, all of which can be attributed to the disruption of normal vestibulo-cochlear nerve function. Often impaired hearing is than 80% of patients have reported tinnitus.

Pathogenesis

Acoustic neuromas may be idiopathic,^[3] or in some cases occur as part of von Recklinghausen neurofibromatosis, in which case, the neuroma may take on one of the two forms.

- In neurofibromatosis type I: A schwannoma may sporadically involve the 8th nerve, usually in adult life, but may involve any other cranial nerve or the spinal root. Bilateral acoustic neuromas are rare in this type.^[4]
- In neurofibromatosis type II: Bilateral acoustic neuromas are the hallmark and typically present before the age of 21. These tumors tend to involve the entire extent of the nerve and show a strong autosomal dominant inheritance. Incidence is about 5–10%.

Diagnosis

Contrast-enhanced Computed Tomography (CT) will detect almost all acoustic neuromas that

Access this article online

Website:

www.ijrh.org

DOI:

10.4103/0974-7168.154349

Quick Response Code:



Gaurang Clinic and Centre for Homoeopathic Research, Lucknow, Uttar Pradesh, India

Address for correspondence:

Dr. Girish Gupta,

Gaurang Clinic and Centre for Homoeopathic Research, B-1/41, Sector A, Near Novelty (Aliganj), Kapoorthala, Aliganj, Lucknow - 226024, Uttar Pradesh, India.

E-mail: girishguptadr@gmail.com

Received: 19-12-2014

Accepted: 13-03-2015

are >2.0 cm in diameter and project further than 1.5 cm into the cerebello-pontine angle. Those tumors that are smaller may be detected by Magnetic Resonance Imaging (MRI) with gadolinium enhancement. Audiology and vestibular tests should be concurrently evaluated using air conduction and bone conduction threshold testing to assess for sensorineural versus conduction hearing loss.

Treatment in Modern Medicine

Indicated treatments for acoustic neuroma include conservative, surgical removal and radiotherapy. About 25% of all acoustic neuromas are treated with medical management consisting of a periodic monitoring of the patient's neurological status, serial imaging studies and the use of hearing aids when appropriate.^[5]

CASE REPORT

A 68-year-old retired Principal consulted us on 13-1-13 for sudden of severe headache with vomiting in the night of December 31, 2012. He gave a history of hearing trouble with tinnitus and headache with disturbed sleep for the last 3 years. He was also suffering from hypertension since last 10 years, Grade I Benign Prostatic Hypertrophy and fungal infection in groins suppressed by betnovate and quadriderm. Patient had been taking Allopathic and Ayurvedic treatment.

Life Space

The patient was a 68 year old retired Principal of Government College. Being the Principal, dictatorship came naturally to him as he had to maintain discipline in the college but at the same time he had also to cope up with the situations arising while working in a Government setup. Thus diplomacy was a part of his work. He had tendency to contradict others even though the person in front of him may be correct because every time his logical mind was overpowered by his basic nature of dictatorship. As a routine he had to attend meetings with his seniors and address his colleagues, subordinates and students. Not being a good orator, he had severe anticipatory anxiety and these meetings were like an ordeal for him. His personality clearly depicts the anxiety in his nature, may it be about public appearance, work related or about himself. He was also very particular about his personal appearance, cleanliness in

surroundings, punctuality and perfection in work making him systematic and fastidious.

Despite being strong personality, the fear element associated with his anxiety is reflected when he is in closed or narrow place like lift, air conditioned coach in train etc., The same fear and anxiety was about the well-being of his relatives, family members, near and dear ones. It was irony of fate that in the last 4 years he had undergone tremendous grief due to untimely demise of his brother in 2009. By the time he could overcome the trauma another episode of death of his young nephew in 2012 added to his woes. The persistent grief led to episodes of headache with tinnitus and hypertension with sleep disturbances.

Investigations

Computed Tomography Head (4/1/2013)

Well-defined heterogeneously enhancing lobulated space occupying lesion is seen involving left cerebello-pontine angle region measuring 2.24 cm × 2.61 cm with evidence of intralesional calcification – suggestive of vestibular schwannoma [Figures 1 and 2].

Magnetic resonance imaging brain (11/1/2013)

Moderate sized well-defined heterogeneously enhancing extra-axial space occupying lesion in left cerebello-pontine angle region measuring 2.5 cm × 2.4 cm × 2.4 cm-likely acoustic schwannoma [Figure 3].

Repertorization

The repertorization was done using complete repertory with the help of Hompath Classic software (version 8.0)^[6] after selecting the following rubrics.

- [Mind] Contradict, disposition to:
- [Mind] Optimism:
- [Mind] Fear: Narrow place, in, claustrophobia:
- [Mind] Anxiety: Anticipating:
- [Mind] Consolation: Agg.:
- [Mind] Dictatorial, domineering, dogmatic, despotic:
- [Mind] Egotism, self-esteem:
- [Mind] Cowardice:
- [Mind] Impatience:
- [Mind] Fastidious:
- [Mind] Anger, irascibility: Tendency: Contradiction, from:
- [Mind] Ailment from: Anger, vexation: Suppressed, from:
- [Mind] Grief:

Result of Repertorization

Remedies	<i>Lyc</i>	<i>Ignatia</i>	<i>Aurum</i>	<i>Nux vom</i>
Totality	25	18	17	17
Symptoms covered	12/13	8/13	11/13	11/13

Thermals

Ambithermal patient.

Selection of Remedy

The rubrics—disposition to contradict, claustrophobia, anticipatory anxiety, dictatorial, cowardice, grief, anger from contradiction and ailment from suppressed anger strongly favored the selection of *Lycopodium* Figure 4.

Follow-up:

- 1st Prescription: (13/1/2013): *Lycopodium* 30C once a week followed by Placebo for 4 weeks.

Follow-up 1 (18/2/2013)

Headache reduced, but tinnitus remained as such. No relief in urinary symptoms. *Lycopodium* 30C was repeated once a week followed by placebo for 4 weeks.

Follow-up 2 (20/3/2013)

Heaviness head reduced, but tinnitus remained as such. *Lycopodium* 30C was repeated once a week

followed by placebo for 4 weeks.

Follow-up 3 (23/4/2013)

Heaviness head and tinnitus remained as such. *Chininum sulph.* 30C was prescribed twice daily for 4 weeks as short-acting intercurrent remedy for tinnitus and heaviness head.^[7] Patient had fracture tibia due to fall, was operated and fixation was done with a nail *in situ*.

Follow-up 4 (26/5/2013)

Heaviness head reduced, but tinnitus remained as such. *Chininum sulph.* 30C was repeated twice daily for 4 weeks.

Follow-up 5 (27/6/2013)

Patient overall as such. *Lycopodium* 200C was prescribed once followed by placebo for 4 weeks.

Follow-up 6 (2/8/2013)

Headache and tinnitus remained as such. *Lycopodium* 200C was repeated followed by placebo for 4 weeks.

Follow-up 7 (10/9/2013)

Headache and tinnitus better but hearing impairment remained as such. *Lycopodium* 200C was repeated once followed by placebo for 4 weeks. CT scan head dated 9/9/13 revealed moderate symmetrical atrophy both cerebral hemispheres and mild dilatation of both lateral ventricles with no evidence of acoustic/vestibular schwannoma [Figure 5 and 6].

Follow-up 8: (8/10/2013)

Headache and tinnitus much better but hearing impairment remained as such. Only *Chininum sulph.* 30C was repeated twice daily for 4 weeks

Follow-up 9: (20/11/2013)

Headache and tinnitus almost subsided but hearing

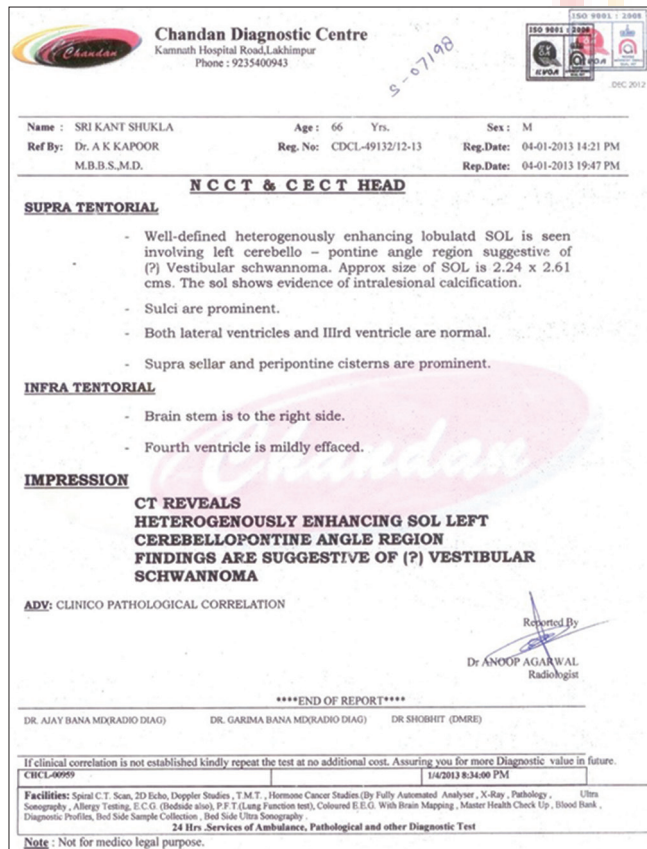

Figure 1: Initial Computed Tomography head report

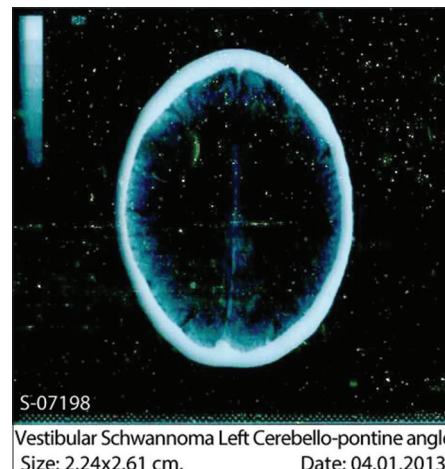


Figure 2: Initial computed tomography head film

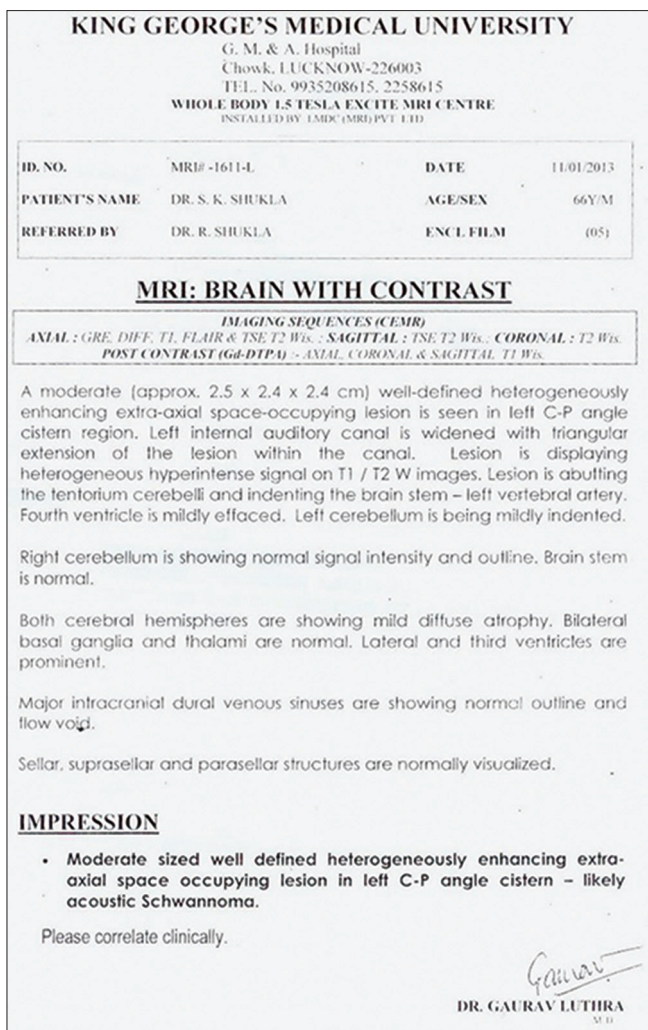


Figure 3: Initial Magnetic Resonance Imaging brain report

impairment remained as such. *Lycopodium* 200C was repeated weekly followed by placebo for 4 weeks. Patient consulted neurosurgeon who did not agree with the last CT scan report and advised to undergo MRI, which was deferred due to nail *in situ* in the fractured bone. A repeat CT head, therefore, was advised to confirm the status.

Follow-up 10: (24/12/2013)

Scan of head dated 24/12/13 was again normal with no evidence suggestive of any focal/diffuse parenchymal disease or any space occupying lesion [Figure 7 and 8].

DISCUSSION

The patient was diagnosed to be suffering from acoustic/vestibular schwannoma left

Repertorisation Table																	
Patient Name :	Dr. SHRI KANT SHUKLA											Reg. No. :	9542		Rep. Date :	13/01/2013	
Normal Repertorisation																	
	Lyc	Ign	Aur	Nux-v	Sep	Sulph	Sil	Nat-m	Ans	Puls	Staph	Anac	Carc	Lach	Merc		
Totally Symptoms Covered	25	18	17	17	17	16	16	16	14	14	12	12	12	12	11		
[C] [Mind]Contradict, disposition to :	2	1	2	1	1	1	1										
[C] [Mind]Optimism :	1		1	1		2	1			1							
[C] [Mind]Fear:Narrow place, in, claustrophobia :	3	2		1	1	1		1	1	3	1		1	1			
[C] [Mind]Anxiety:Anticipating :	1		1				1	1	1					2			
[C] [Mind]Consolation:Agg. :	1	3	1	1	4	2	3	4	2		1			3	1		
[C] [Mind]Pustular, domineering, dogmatic, despotic :	2			1	1				1						1		
[C] [Mind]Egotism, self-esteem :	2		1	1		2	2				1	1			2		
[C] [Mind]Cowardice :	3	1	1	2	1	1	2	1		2	1			1	1		
[C] [Mind]Impatience :	2	3	1	3	3	3	3	2	2	2	1	1	1	2	1		
[C] [Mind]Fastidious :	1		1	2	1	1	1	2	2	3		2	3				
[C] [Mind]Anger, irascibility:Tendency:Contradiction, from :	3	3	3	2	3		2		1						1		
[C] [Mind]Aliments from:Anger, vexation:Suppressed, from :	3	2	2		1					3			1				
[C] [Mind]Grief :	2	3	3	2	2	2	1	3	2	3	3	2	1	2	2		
Symptoms 1 to 13 Total Symptoms : 13 Remedies 1 to 15 Total Remedies : 270																	

Figure 4: Repertorization table

cerebello-pontine angle. On enquiring, he gave a history of hearing trouble and tinnitus left ear with headache and disturbed sleep. Sensorineural hearing ability is mediated by the inner ear composed of the cochlea with its internal basilar membrane and attached cochlear nerve. The outer ear consisting of the pinna, ear canal, and ear drum or tympanic membrane transmits sounds to the middle ear but does not contribute to the conduction or sensorineural hearing ability. The patient did not undergo any other therapy like radiotherapy/radio surgery during the whole course of treatment because it could not be carried out without biopsy which he did not want to undergo. Hence he resorted to Homoeopathy which radically eliminated the disease. This rare case of acoustic schwannoma which required surgical removal but was cured by homoeopathic medicine *Lycopodium* while *Chininum sulph.* 30C was prescribed as short-acting intercurrent remedy for tinnitus and heaviness head. Since the main concern of the patient was acoustic/vestibular schwannoma hence regular monitoring for hypertension and benign prostatic hyperplasia (BPH) was not done. However, the patient reported symptomatic relief in BPH and his blood pressure remained within normal range due to constitutional treatment. The prescription was based purely on mental symptoms because as per principles of Homoeopathy one physical general can rule out several particulars and one mental general can rule out several physical generals. This particular patient was treated as a

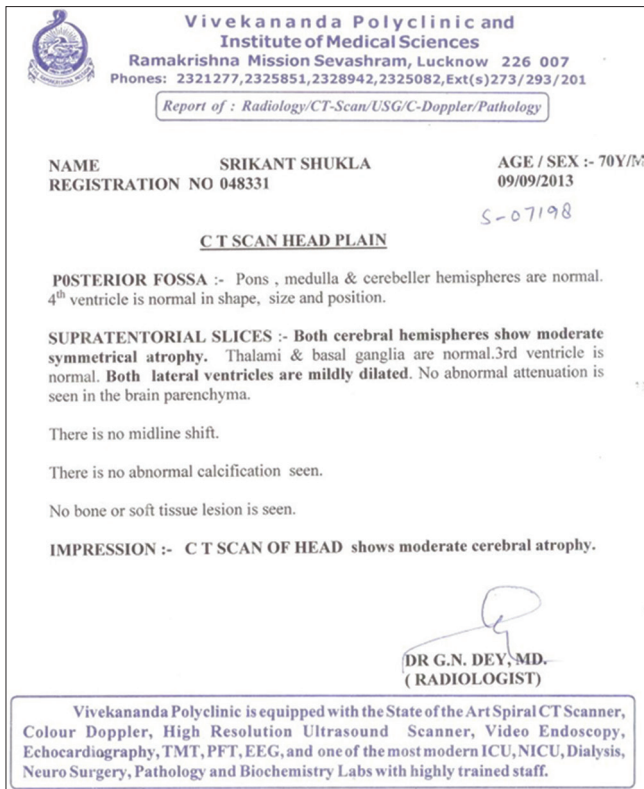


Figure 5: Follow-up computed tomography head report

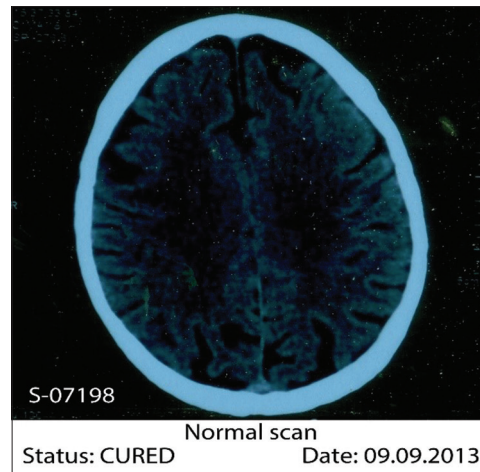


Figure 6: Follow-up computed tomography head film

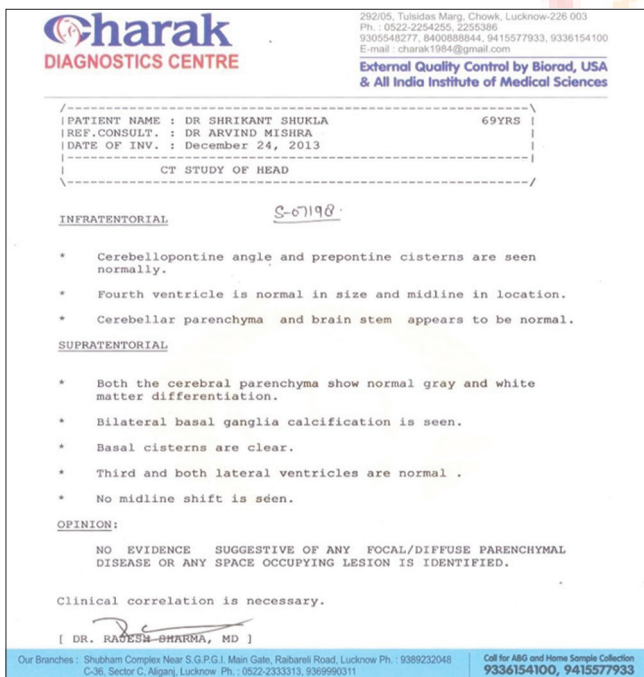


Figure 7: Final computed tomography head report

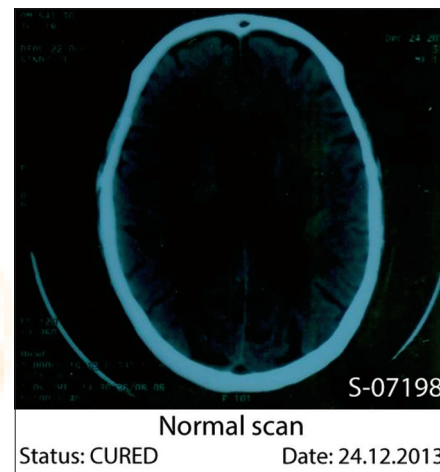


Figure 8: Final computed tomography head film

REFERENCES

1. Acoustic Neuroma. NHS Choices. Available from: <http://www.nhs.uk/conditions/Acoustic-neuroma/Pages/Introduction.aspx>. [Last accessed 2013 Aug 30].
2. Acoustic Neuroma – Diagnosis and Treatment-UPMC, Pittsburgh, PA, USA.
3. Acoustic Neuroma-at American Hearing Research Foundation, Chicago, IL, USA. Available from: http://american-hearing.org/disorders/tumors/acoustic_neuroma.html#treated. [Last accessed on 2015 Mar 20]
4. Complete Repertory of Homopath Classic (version 8.0), 2006, (CD ROM).
5. Boericke W. Pocket Manual of Homoeopathic Materia Medica. 9th ed. Fourth reprint. Boericke and Runyon, INC, New York; 1975. p. 195-6.
6. Acoustic Neuroma Association (November 2013). Acoustic Neuroma Basic Overview. ANA Patient Information Booklets: 3.
7. Hearing disorders-Acoustic neuromas (also called Acoustic Tumors and Vestibular Schwannomas): Causes of Acoustic neuroma. House Ear Clinic.

How to cite this article: Gupta G, Gupta N, Pandey D. An evidence-based case of acoustic/vestibular schwannoma. Indian J Res Homoeopathy 2015;9:49-54.

Source of Support: Nil, **Conflict of Interest:** None declared.

whole on the basis of totality of symptoms giving more emphasis to mental symptoms to indicate the remedy instead of clinical and pathological symptoms.

श्रवण / प्रघाण श्वान अर्बुद का एक साक्ष्य आधारित मामला

सार:

प्रघाण श्वान अर्बुद, जिसे प्रायः श्रवण तंत्रिकाबुद/श्वान अर्बुद (श्वानोमा) कहते हैं, प्रघाण-कर्णावर्त तंत्रिका (8वीं कपाल तंत्रिका) की माइलिन-उत्पादक कोशिकाओं का एक सुदम्य प्राथमिक अंतःकरोटि अर्बुद है। यह श्वान अर्बुद का एक प्रकार है। यह अर्बुद माइलिन आच्छद हेतु उत्तरदायी श्वान कोशिकाओं से उत्पन्न होता है। माइलिन आच्छद परिधीय तंत्रिकाओं को विद्युतरोधी रखने में सहायक होता है।[1] संयुक्त राज्य अमेरिका में प्रति वर्ष लगभग 3,000 मामले सामने आते हैं। विश्व भर में इस रोग के पाए जाने की दर एक लाख में 1 के आस-पास है। यह वयस्कों के सभी अंतःकरोटि अर्बुद मामलों का 5-10% है। इसके सर्वाधिक मामले पाँचवे व छठे दशकों में देखे जाते हैं और स्त्री-पुरुष इससे समान रूप से प्रभावित होते हैं। 2004 में डेनमार्क में प्रकाशित अध्ययन दर्शाते हैं कि रोग व्याप्ति प्रति एक लाख जनसंख्या में 1.74 है। श्रवण तंत्रिकाबुद के अधिकांश मामले 30 से 60 के बीच की आयु में देखे जाते हैं और ऐसा प्रतीत होता है कि स्त्री व पुरुष इससे समान रूप से प्रभावित होते हैं।[7]

वनस्पति जगत से प्राप्त होम्योपैथिक दवा लाइकोपोडियम द्वारा श्रवण / प्रघाण श्वान अर्बुद की चिकित्सा का यहाँ वर्णित मामला एक दुर्लभ मामला है। यह व्यक्तिनिष्ठ व वस्तुनिष्ठ, दोनों मानदंडों पर इस दवा प्रभावकारिता का दर्शाता है। सामान्य स्थितियों में इस मामले में शल्यचिकित्सा की आवश्यकता पड़ती है।

मुख्य शब्द: प्रघाण श्वान अर्बुद, श्रवण तंत्रिकाबुद/ श्वान अर्बुद, लाइकोपोडियम, होम्योपैथिक दवा।

