

## CASE RECORD

### A case of Colloidal Nodular Goiter

Bindu Sharma\*

Most thyroid nodules are asymptomatic. Visible nodules are of great concern to the patient because of the cosmetic embarrassment they cause. Affected patients are euthyroid i.e. serum T<sub>3</sub>, T<sub>4</sub> & TSH are normal. A case of colloidal nodular goiter presented at Regional Research Institute (RRI) (H), Shimla. Her thyroid profile was within normal range and Fine Needle Aspiration Cytology was clearly suggestive of colloidal nodular goiter. Partial thyroidectomy was advised due to cosmetic reasons. The fear of surgery brought the patient to RRI (H), Shimla for treatment. She was treated with homoeopathic medicines following holistic concepts of Homoeopathy and the result was complete disappearance of Thyroid nodule. Sulphur initiated the action and Lycopodium completed the cure.

**Keywords:** colloidal nodular goiter; partial thyroidectomy; sulphur; lycopodium; euthyroid

#### Introduction

Goiter is an enlargement of thyroid gland caused by compensatory hyperplasia & hypertrophy of the follicular epithelium which occurs sporadically and usually of unknown etiology. Nodular goiter presents rarely before middle age and female preponderance is established<sup>1</sup>. It is a clinical entity characterized by subsequent growth, structural or functional transformation of one or more areas within the normal thyroid tissue. Multi-nodular goiter is benign, whereas solitary nodules may be malignant. So in patients presenting with a solitary nodule, malignancy must be ruled out. In all patients with solitary nodule it is important to measure serum T<sub>3</sub>, T<sub>4</sub>, and TSH<sup>2</sup> though most useful is fine needle aspiration of the nodule. If a colloid goiter is small, and is causing no obvious symptoms, surgery is not really necessary, and the indications for its removal are only cosmetic. If there is dyspnoea or dysphagia, or the gland is large, subtotal thyroidectomy is indicated, but is seldom urgent.

We find sufficient homoeopathic literature for the treatment of goiter but there is a lack of evidence based documented case records for therapeutic management of thyroid nodules.

---

#### Address for Correspondence:

Dr. Bindu Sharma  
Asstt. Director (H)  
Central Council for Research in Homoeopathy  
61-65, Institutional Area, Janakpuri,  
New Delhi -110058  
Email: drbinduhomoeo@gmail.com

The present case shows the scope of homoeopathic intervention in this surgical disease.

#### Case Summary

A perimenopausal patient, 42 years of age, with visible swelling of the thyroid gland (Right lobe) for the last 4 years presented at RRI (H), Shimla in Feb. 2007. She was suffering from hot flushes, night sweats, anxiety, depression, pruritus vulvae, vaginal discharge and decreased sexual desire. But her main concern was the swelling of Thyroid gland. There was no H/O dysphagia, dyspnoea, hoarseness, loss of weight, diarrhea etc. She was admitted to a Govt. hospital for surgery but she backed out at the last moment and decided to take homoeopathic treatment. She had under gone Thyroid Function Tests (TFT), Fine Needle Aspiration Cytology (FNAC) and USG of Thyroid gland. All her investigations pointed to the diagnosis of Colloidal Nodular Goiter. Her symptoms included:

- Anxiety: worried about minor matters, slightest noise, even quarrel amongst her children aggravated her complaints and made her irritable.
- Depression: sad, morose, shy, timid, doesn't talk much, irritable, mood despondent, she seldom laughed. Weeping on being thanked.
- Flushes of heat surging up from chest and neck with mild redness of face and desire to throw off covering.
- Irregular scanty menses, for more than 6 months.
- Fullness in right breast with thin milky discharge from right nipple.

- Anal itching worse at night.
- Dry heat in palms and soles.
- Reduced sexual desire.

Her vasomotor symptoms, anxiety, irritability and depression were suggestive of climacteric distress (TFT were normal). She was recommended certain investigations which included "hormonal assay" (FSH), complete haemogram, and lipid profile. P/V and P/S examination and PAP smear were done to rule out Cervical Intraepithelial Neoplasia (CIN) & USG pelvis to rule out any pelvic pathology. Keeping in view the milk like discharge from nipple, she was advised serum prolactin to rule out prolactinoma. All her reports were within normal range except FSH which was raised as she was in perimenopausal age group.

**PAST HISTORY:** H/O recurrent folliculitis

### TREATMENT HISTORY

Though she had Euthyroid status, she had been prescribed Eltroxin 50mg ODx15 days and thereafter 100mg ODx15 days but no subsequent change was seen in her complaints.

### FAMILY HISTORY

Father - expired at the age of 64 years, as he suffered from CA lungs (was a chronic smoker).

Mother-had been diagnosed with OA knee joints and oesophageal varices.

Sister- suffering from hypotension.

### PERSONAL HISTORY

Not significant.

### MENSTRUAL HISTORY

Onset of menarche was at the age of 15yrs. Earlier her menses were irregular, scanty and delayed with dark brown color. Each menstrual cycle was preceded by fullness and heaviness of breasts.

### OBSTETRIC HISTORY

Nothing significant

### ASSOCIATED COMPLAINTS

Enterobiasis, anal itching<night.

### PHYSICAL MAKE-UP

Thin, short stature with dark, unclean dirty looking complexion.

### GENERALS

Mental: weeping++, irritability++, frightened+ trifles at, fear of being alone+, sensitivity +++ (even to door bell or bang of door), sluggish+, reserve+ Physical: Burning heat of palm & soles, desire for sweets+++, warm drinks etc., offensive discharges, sweat stains the clothes yellow and weakness+++ Thermal reactions: Chilly patient but burning heat in palms & soles.

### GENERAL EXAMINATION

Pallor: Mild  
Oedema- Nil  
Pulse-72/min  
B.P-110/70 mm of Hg  
Hirsutism- Nil  
Weight-51.5 kg

**Table 1:** Investigations

	TESTS	RESULTS	REFERENCE RANGE
1	FSH	19.59mIU/mL	2.50-10.20 mIU/mL
2	HAEMOGRAM Haemoglobin TLC DLC	10 gm% 8600 P75,L22,E2,M1	12-14gm% 4000-11000
3	BLOOD SUGAR (FASTING)	84mg/dL	70-110 mg/dl
4	LIPID PROFILE Cholesterol Triglycerides HDL LDL VLDL	129mg/dL 80mg/dL 37mg/dL 16mg/dL 76mg/dL	(147-200mg/dL) (<150mg/dL) (45-70)mg/dL (10-32mg/dL) (<100mg/dL)

USG (Pelvis): suggestive of normal study

F N A C (Thyroid):

**GYNAECOLOGICAL EXAMINATION:** Within normal range.

**INVESTIGATIONS :**

SNAC - Microscopic Examination of thyroid shows abundant colloid (thin & thick), follicular epithelial cells in the form of sheets, papillae & clusters with stromal fragments, involuntary & hyperplastic follicular epithelial cells, free flare appearance, scattered base nuclei, macrophages, hurter's cells, lymphocytes & haemorrhagic background.

**USG (Thyroid):** Dated: 28/06/06 Rt. Lobe of thyroid shows a cystic lesion of size 20mm showing a nodule inside. It is well defined, shows echogenic calcification of its walls. Lt. lobe of thyroid as well as isthmus are normal. No cervical Lymphadenopathy.

**Treatment Plan**

Her complaints were recorded after taking thorough history as per the principles of Homoeopathy. After analysis and evaluation, her symptoms were converted to relevant rubrics for repertorization as given under:

1. Heat flushes, climacteric during
2. Heat, hand, palm, dry heat

3. Heat, foot, sole night
4. Itching, around anus, warmth of bed
5. Irritability, alone when
6. Company, desire for
7. Thread worms
8. Desires, sweets
9. Sweat stains the clothes yellow
10. Swelling thyroid gland

The case was repertorized using Synthesis repertory in RADAR 7.1 software.<sup>3</sup> (Fig.1) On repertorization, Arsenic covered 5 rubrics while Lachesis, Sulphur, Lycopodium, Phosphorus, Sepia, Calc. carb., Merc. and Petroleum covered 4 rubrics each. Considering the physical make-up of the patient and past history of the patient, Sulphur was selected as the First prescription. The follow up visits are shown in Table-2

USG (thyroid): Dated 12/3/08

Rt lobe of thyroid measures 3.4x1.2cm

Lt. Lobe measures 3.2x1.2cm

There is small well defined hypoechoic nodular lesion in right lobe of thyroid gland of the size 1.0x 1.0 cm. (Fig.2)

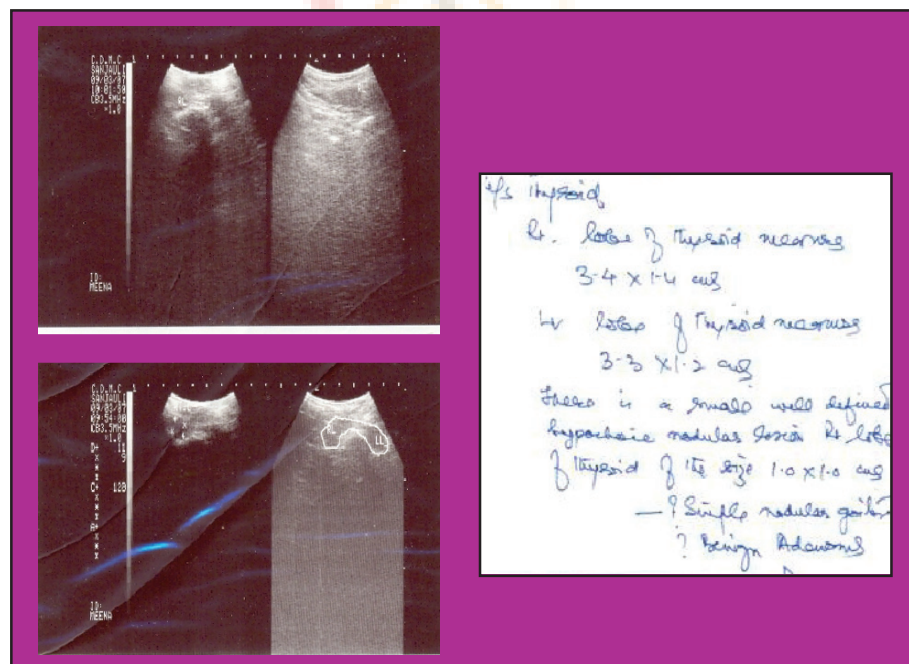
The screenshot shows the RADAR 7.1 software interface. The main window displays an analysis titled 'Analysis (1 Clipboards) - SOS'. Below the title, it states 'Sum of symptoms (sort.deg)' and 'This analysis contains 224 remedies and 10 symptoms. Intensity is considered'. A table lists 10 symptoms and their corresponding intensity scores for 20 different remedies. The remedies are abbreviated as: 1. ars, 2. lach, 3. sulph, 4. lyc, 5. phos, 6. sep, 7. calc, 8. merc, 9. petr, 10. petro, 11. petr, 12. argn, 13. chin, 14. calc-c, 15. bar-c, 16. bell, 17. nat-c, 18. pub, 19. bry, 20. cub-v.

	1	2	3	4	5	6	7	8	9	10	11	12	13	14	15	16	17	18	19	20
	ars	lach	sulph	lyc	phos	sep	calc	merc	petr	petro	petr	argn	chin	calc-c	bar-c	bell	nat-c	pub	bry	cub-v
1. GENERALS - HEAT - flushes of - menopause, duri	1	-	3	3	1	-	2	1	-	1	-	2	-	1	-	2	-	1	-	-
2. EXTREMITIES - HEAT - Hand - palm - dry heat	1	-	-	-	-	-	-	-	-	-	-	-	-	-	-	-	-	-	-	-
3. EXTREMITIES - HEAT - Foot - sole - night	1	-	3	-	-	-	-	-	-	-	-	1	-	-	-	1	-	-	-	-
4. RECTUM - ITCHING - Anus, around - warm bed	1	-	-	-	-	-	-	-	-	-	2	-	-	-	-	-	-	-	-	-
5. MIND - IRRITABILITY - alone - when	1	-	-	-	1	-	-	-	-	-	-	-	-	-	-	-	-	-	-	-
6. MIND - COMPANY - desire for	1	3	1	1	3	4	2	2	1	-	2	-	3	-	3	-	1	2	2	1
7. PERSPIRATION - STAINING the linen - yellow	1	1	3	-	-	-	-	-	3	2	-	-	2	-	-	2	-	2	-	1
8. EXTERNAL THROAT - SWELLING - Thyroid Gland	1	1	-	-	-	-	-	-	-	-	-	-	-	-	-	-	-	1	-	-
9. RECTUM - WORMS - complaints of worms - pinwo	1	2	-	2	1	1	2	2	1	2	1	1	-	1	-	3	-	-	-	1
10. GENERALS - FOOD and DRINKS - sweets - desir	1	-	3	3	2	2	2	2	1	1	1	3	3	2	1	-	2	2	2	2

Fig.1

**Table 2:** Follow up visits

Date	Medicines	Doses	Remarks
8.03.07	Sulphur 30 Placebo	Single dose & BD	1st prescription
21.03.07	Sulphur 30	Single dose	No change noticed in any of the symptoms
20.04.07	Sulphur 200 Placebo	Single dose BD	No change noticed in any of the symptoms
17.05.07	Sulphur 1M	Single dose	No change noticed in any of the symptoms
05.06.07	Sulphur 1M	Single dose	Anal itching persists, burning palms & soles no change, milk in breast present
03.07.07	Sabadilla 6	9 Doses	Burning palms & soles no change, milk in breast present, hot flushes & night sweat better, <b>swelling in neck reduced in size</b> . However, the patient complains of sneezing, watery nasal discharge and pain in throat ameliorated by swallowing warm water.
27.08.07	Nuxvomica 6	9 Doses	Having diarrhea with colicky pain in abdomen with ineffectual urge for stool.
19.10.07	Placebo	BD	Discharge from nipple present, burning heat in palms soles better, no anal itching. Size of swelling in neck not reducing further.
15.12.07	Rhus tox 6	9 Doses	Complaining of fever, generalized body pain, chill and dry cough. Tongue shows red triangular tip.
10.01.08	Sulphur 1M	1 dose	Discharge from right nipple present, burning heat in palms soles better, no anal itching. Anxiety and hot flushes better. Size of swelling in neck not reducing further
12.03.08	Placebo	BD	Though there is symptomatic improvement, the patient is getting restless as there is no further reduction in size of the swelling of the neck which is her major concern. Patient is advised to get USG of thyroid gland.



**Fig. 2**

Report – Simple nodular goiter or Benign adenoma.

She was re-interrogated and following rubrics were taken into consideration for repertorization of her case.

1. Weeping, thanked, when
2. Irritability, menses, before
3. Frightened, trifles, at
4. Fear, alone, of being
5. Food, sweets, desire
6. Heat, hand, palm, dry heat
7. Heat, foot sole
8. Milk, Non pregnant women in
9. Discoloration, dirty looking

The case was repertorized using combined repertory in CARA Professional v.1.4.4 (Fig. 3)

	Lyc	Arg-n	Kali-c	Phos	Sep	Sulph	Merc	Puls	ATS	Calc	Nux-y
Weighted	20	9	9	9	9	9	8	8	7	7	7
Rubrics covered	8	3	4	5	5	3	5	4	3	5	5
Rubric grades	20	9	9	9	9	9	8	8	7	7	7
WEEPING, THANKED, WHEN	3										
IRRITABILITY, MENSES, BEFORE	2		1		2			1		1	2
FRIGHTENED, TRIFLES, AT	2		3	2	1		1			1	1
FEAR, ALONE, OF BEING	3	3	3	3	2		1	2	3	1	1
FOOD, SWEETS DESIRE	3	3	2		2	3	2		3	2	1
HEAT, HAND, PALM, DRY HEAT											
HEAT, FOOT, SOLE	3			2	2	3		2		2	2
MILK, NON-PREGNANT WOMEN	1			1			2	3	1		
DISCOLORATION, DIRTY LOOKING	3	3		1		3	2				

(Fig. 3)

Lycopodium was prescribed as per the follow-up schedule given in Table 3

**Table 3:** Follow up visits

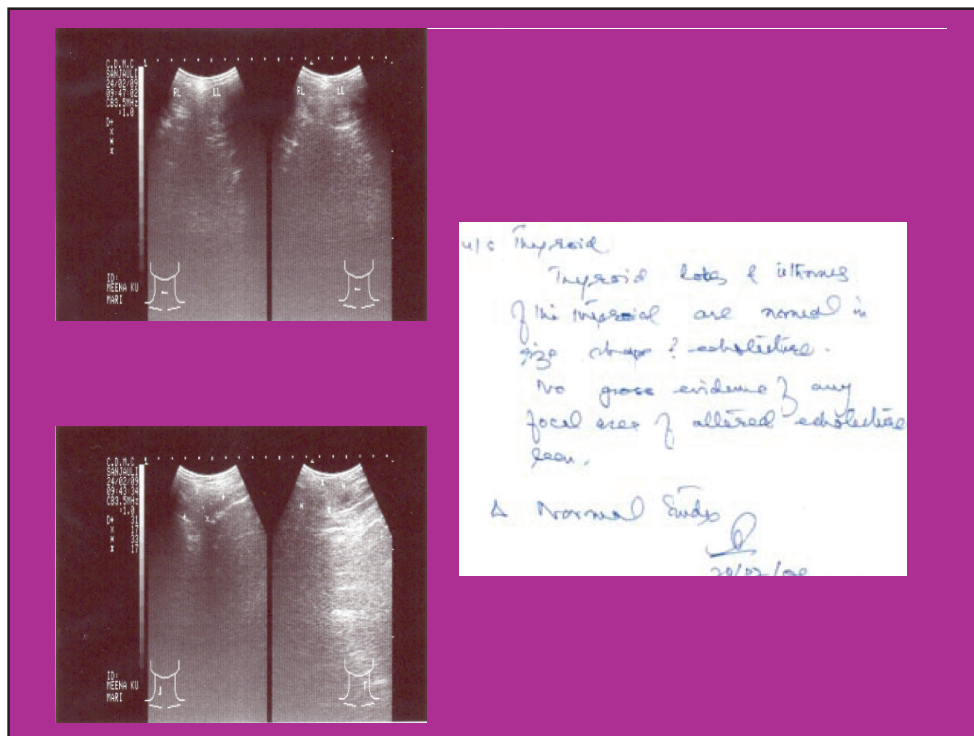
Date	Medicines	Doses	Remarks
15.03.2008	Lycopodium 30 Placebo	Single Dose BD	
26.04.2008	Lycopodium 30 Placebo	Single Dose BD	No apparent change was observed on any parameter
05.06.2008	Lycopodium 30 Placebo	Single Dose BD	There is some reduction in the milky secretion from the right nipple. The patient reports mild change in the size of thyroid swelling too.
07.07.2008	Placebo	BD	Patient reports improvement in anxiety, irritability, burning heat in palms and soles. Nodular swelling of neck reducing.
12.08.2008	Placebo	BD	Status same as on last visit
29.09.2008	Lycopodium 200 Placebo	Single Dose BD	The patient reports no further reduction in the size of thyroid swelling. Discharge from nipple also same.
31.10.2008	Lycopodium 200 Placebo	Single Dose BD	The patient says, "It appears I will have to go for surgery only". Everyone at home also is advising me not to waste any more time.
02.12.2008	Lycopodium 1M	3 doses at five minutes interval	She was advised not to discontinue treatment and to be patient for some more time
31.12.2008	Placebo	BD	Patient reports marked improvement in the swelling of thyroid. Discharge from the right nipple has lessened.
06.02.2009	Placebo	BD	Improvement continues on symptomatological as well as pathological parameters. Skin appears more clear.
12.02.2009	Placebo	BD	No visible swelling of Thyroid gland. No burning in palms and soles. No anal itching. Discharges from right nipple disappeared. The patient was advised to get USG of thyroid gland done.



**USG (thyroid):** Dated:12/2/09

Thyroid lobes and isthmus of the thyroid are normal in size, shape and echo texture.

No gross evidence of any focal area of altered echo texture seen. Report shows normal study. (Fig. 4)



(Fig. 4)

**DISCUSSION**

In modern medicine, colloidal nodular goiter patients are often advised partial thyroidectomy which was advised in this case too, since there is no specific treatment for such a disorder. In Homoeopathy, a prescription is always based on holistic approach which implies a totality of symptoms constituted by Mental Generals, Physical Generals and Characteristic symptoms of the patient. For building up this totality, judicious case taking by thorough interrogation of emotional and psychological factors like fears, grief, shock, anger, suppressed emotions etc. must be taken into account.

Reference to literature revealed that in one case of Adenomatous goiter the size of the swelling reduced in a short span of four months with *Calcarea carb.*<sup>5</sup> Similarly 2 cases of goiter were reported successfully treated with *Aurum muriaticum natronatum*.<sup>6</sup>

In this case, Sulphur was primarily selected as first prescription. Based on the totality of symptoms drawn from initial case taking, the medicine (Sulphur), acted partially giving only some relief to the patient and not curing her despite having given sufficient time to act.

On re interrogation it was found that an important rubric 'Weeping when thanked' was left out in the earlier repertorisation, although the symptom was present in the patient since beginning. Also the rubric 'Irritability' was qualified by the patient as 'Irritability, menses before', so it appears that in the initial repertorisation, incomplete totality led to selection of partial simillimum which brought partial relief to the patient.

Dr. Hahnemann advises us in § 213 Organon that "We shall, therefore, never be able to cure conformably to nature – that is to say, homeopathically – if we do not, in every case of disease, even in such as are acute, observe, along with the other symptoms, those relating to the changes in the state of the mind and disposition, and if we do not select, for the patient's relief, from among the medicines a disease-force which, in addition to the similarity of its other symptoms to those of the disease, is also capable of producing a similar state of the disposition and mind".<sup>7</sup>

If we retrospect the case we find that *Lycopodium* was the simillimum right from the beginning and when it was prescribed in rising potencies from 30 to 1M the result was total removal of Colloidal nodular goiter along with accompanying symptoms like Itching in

anus, burning of palms and soles, anxiety, milky discharge from the right nipple etc.

The case also reflects relevance of analysis and evaluation of the symptoms and teaches us how repertory as a tool can lead us to a similimum or partially similar medicine. Sulphur played some role in the patient and Lycopodium completed the cure. The pivot on which homoeopathic cures stand is the art of case taking and the evaluation and analysis of symptoms. It proved to be a classical cure, a rapid gentle and permanent restoration of health, the removal of disease in its whole extent in the gentle, harmless way on the principle of similia.

## CONCLUSION

The similimum is the remedy that individualizes the patient and such a remedy works at the deeper levels and leads to permanent restoration of health which is evident from this case. The patient improved on all psychosomatic and pathological parameters. The thyroid nodule disappeared, milky discharge from right nipple also stopped. There was not only improvement in her anxiety, weeping tendency and irritability but general appearance of the patient changed altogether.

The correct approach for analysis and evaluation of symptoms needs to be followed to avoid errors in arriving at the correct remedy. This case again proves beyond doubt the importance of mental symptoms in evolving the individualized picture of the disease

person thus paving the way to correct repertorization and final selection of the similimum.

## ACKNOWLEDGEMENT

The author is grateful to Dr. S. R. Sharma, former Asstt. Director, In charge, RRI (H) Shimla, for extending all the technical and administrative support and editing this case report. The author acknowledges Dr. P. S. Chakravarty, Asstt. Director, CCRH, for his valuable suggestions. I am also thankful to Dr. Pritha Mehra, Research Officer (H), CCRH Hqrs, for helping in conducting literature review for this case report.

## REFERENCES

1. Paul A. Fitzgerald. Endocrine Disorders. Current Medical Diagnosis and Treatment 2009, 48th Edition. Mc Graw Hill. p.992.
2. B. R. Walker, A.D. Toft. Endocrine disease. Davidson's Principles and Practice of Medicine, 19<sup>th</sup> Edition. Churchill Livingstone, p.703.
3. Synthesis repertory. Radar 7.1
4. Combined repertory. CARA Professional v.1.4
5. Gupta Girish. A case of Adenomatous goiter. Homoeo Times. Vol.4 (11), November 2007:25-27.
6. Sevar Raymond. Aurum muriaticum natronatum – four case reports. Homeopathy. (2007) 96:258-269.
7. Hahnemann S. Aphorism 213. Organon of Medicine 5<sup>th</sup> edition. Swaran Publishing House, New Delhi. p.157.