

27-6-2024

## Homoeopathic treatment of oral leucoplakia: A case report

Suraia Parveen

*Dr. Anjali Chatterji Regional Research Institute for Homoeopathy, Kolkata, West Bengal, India, drsuraia@gmail.com*

Zeeshan Ahmed

*Regional Research Institute (H), Guwahati, Assam, India*

Author(s) ORCID Identifier:

<https://orcid.org/0000-0002-7198-9667>

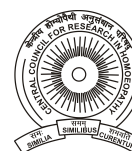
Follow this and additional works at: <https://www.ijrh.org/journal>

 Part of the [Homeopathy Commons](#)

### How to cite this article

Parveen S, Ahmed Z. Homoeopathic treatment of oral leucoplakia: A case report. Indian J Res Homoeopathy 2024;18:61-68

This Case Report is brought to you for free and open access by Indian Journal of Research in Homoeopathy. It has been accepted for inclusion in Indian Journal of Research in Homoeopathy by an authorized editor of Indian Journal of Research in Homoeopathy. For more information, please contact [ijrhonline@gmail.com](mailto:ijrhonline@gmail.com).



---

## Homoeopathic treatment of oral leucoplakia: A case report

### Abstract

**Introduction:** Oral leucoplakia (OL), a premalignant lesion which is more frequently encountered in elderly people, is defined as a white lesion of the oral mucosa. Smoking is one of the most common risk factors. Conventionally, surgical excision is the most recommended treatment option for OL. **Case Summary:** A 55-year-old male presented with the complaint of a whitish lesion inside the left angle of the mouth (buccal mucosa) for the past 1½ years. The case was clinically diagnosed as OL. He was advised for surgical excision, but he preferred to go for homoeopathic treatment. Based on characteristic symptoms, repertorial analysis and individualisation, homoeopathic medicine *Kali iodatum* (200C and 1M) followed by *Syphilinum* 200C was prescribed. Over 14 months of treatment, the patient initially improved with *Kali iodatum* followed by total remission of the lesion by *Syphilinum*. Modified Naranjo Criteria for Homoeopathy (MONARCH) was used to evaluate the attribution of recovery to homoeopathic treatment. The MONARCH score was (+8 on a '-6 to +13' scale), which is indicative of the possibility of patient's improvement resulting from the homoeopathic treatment. This clinical case report demonstrates the beneficial effects of individualised homoeopathic treatment for the management of premalignant lesions like OL.

### Acknowledgments and Source of Funding

The authors declare that they have not received any financial support or sponsorship for publishing the case report.

# Homoeopathic treatment of oral leucoplakia: A case report

Suraia Parveen<sup>1\*</sup>, Zeeshan Ahmed<sup>2</sup>

<sup>1</sup>Dr. Anjali Chatterji Regional Research Institute for Homoeopathy, Kolkata, West Bengal, India

<sup>2</sup>Regional Research Institute (H), Guwahati, Assam, India

## Abstract

**Introduction:** Oral leucoplakia (OL), a premalignant lesion which is more frequently encountered in elderly people, is defined as a white lesion of the oral mucosa. Smoking is one of the most common risk factors. Conventionally, surgical excision is the most recommended treatment option for OL. **Case Summary:** A 55-year-old male presented with the complaint of a whitish lesion inside the left angle of the mouth (buccal mucosa) for the past 1½ years. The case was clinically diagnosed as OL. He was advised for surgical excision, but he preferred to go for homoeopathic treatment. Based on characteristic symptoms, repertorial analysis and individualisation, homoeopathic medicine *Kali iodatum* (200C and 1M) followed by *Syphilinum* 200C was prescribed. Over 14 months of treatment, the patient initially improved with *Kali iodatum* followed by total remission of the lesion by *Syphilinum*. Modified Naranjo Criteria for Homoeopathy (MONARCH) was used to evaluate the attribution of recovery to homoeopathic treatment. The MONARCH score was (+8 on a ‘-6 to +13’ scale), which is indicative of the possibility of patient’s improvement resulting from the homoeopathic treatment. This clinical case report demonstrates the beneficial effects of individualised homoeopathic treatment for the management of premalignant lesions like OL.

**Keywords:** Homoeopathy, Individualisation, Modified Naranjo Criteria for Homoeopathy, Oral leucoplakia, Premalignant lesion

## INTRODUCTION

Oral leucoplakia (OL) is a potentially malignant disorder recognized as a white lesion of the oral mucosa that cannot be characterised as any other definable lesion.<sup>[1,2]</sup> The elderly men are more likely to have OL, and the likelihood of developing it rises with age. Less than 1% of the affected males are thought to be under the age of 30, and the frequency rises to 8% in male patients over the age of 70 and to 2% in female patients over the age of 70. Epithelial atrophy to hyperplasia, which can be related to various levels of epithelial dysplasia, is the two possible histopathologic features of OL.<sup>[3,4]</sup> OL lesions on the tongue, soft palate and floor of the mouth are regarded as high-risk lesions, but they may be of low malignancy risk in other locations.<sup>[4,5]</sup> The yearly malignant transformation rate of OL ranges from 0.1% to 17%, with several conditions potentially raising this risk.<sup>[3-6]</sup> Patients who are females often have a higher chance of getting the malignant type.<sup>[7-9]</sup> Treatment-resistant OL that has persisted for a long time may have poor prognosis. It has been shown that OL in non-smokers has a higher risk of malignant transformation than OL in smokers.<sup>[10,11]</sup>

The authors could not find any study reported for the homoeopathic treatment of OL while searching different databases.

This case of OL, which manifested as a whitish lesion in the left buccal mucosa, has been reported according to the HOM-CASE guidelines. This case adds to the evidence that homoeopathic treatment can relieve the symptoms of a probable premalignant condition such as OL. Furthermore, it can enhance the quality of life of the patient.<sup>[12]</sup>

## PATIENT INFORMATION

A 55-year-old male presented at the outpatient department (OPD) of Dr. Anjali Chatterji Regional Research Institute of Homoeopathy, Kolkata, on 27, October, 2018 with the complaint of a whitish lesion inside the left angle of the mouth (buccal mucosa) for the past 1½ years. There was pain and burning

**\*Address for correspondence:** Suraia Parveen,  
Dr. Anjali Chatterji Regional Research Institute of Homoeopathy,  
Kolkata - 700 035, West Bengal, India.  
E-mail: drsuraia@gmail.com  
Received: 18 January 2023; Accepted: 5 June 2024

### Access this article online

#### Quick Response Code:



Website:  
www.ijrh.org

DOI:  
10.53945/2320-7094.1342

This is an open access journal, and articles are distributed under the terms of the Creative Commons Attribution-NonCommercial-ShareAlike 4.0 License, which allows others to remix, tweak, and build upon the work non-commercially, as long as appropriate credit is given and the new creations are licensed under the identical terms.

**How to cite this article:** Parveen S, Ahmed Z. Homoeopathic treatment of oral leucoplakia: A case report. Indian J Res Homoeopathy 2024;18:61-68.

sensation over the lesion along with excessive salivation, which aggravated in a warm room and after eating rich and spicy food. The case was already diagnosed as OL by an allopathic physician.

The patient's complaints started 1½ years back when he observed the gradually increasing size of a white patchy lesion inside the left angle of the mouth. There was no discomfort earlier, but for the past 2–3 months, he had started feeling pain and burning sensation after eating anything spicy, along with excessive salivation. He was also suffering from low back pain, which aggravated during walking. He reported to have taken allopathic treatment for OL without much improvement and was then advised surgery.

He had suffered from chicken pox at the age of 16 years and typhoid at the age of 23 years and recovered well from both after taking conventional treatment. His father was hypertensive, and mother suffered from osteoarthritis.

The patient used to work in a jute mill and belonged to a low socioeconomic background. He had a habit of smoking tobacco in the form of cigarettes/*bidi* (15–16/day) since 20 years of age. After developing the white patch, he was advised to stop smoking by his allopathic physician. Although he could not stop it altogether, he reduced the quantity of smoking to 7–8 times/day. However, for the past 6–7 months, following the appearance of this lesion, the patient reported to have stopped smoking completely. He also consumed alcohol occasionally for 10–15 years.

### Clinical findings

The patient weighed 70 kg and was 5 feet 5 inches tall, with a body mass index of 25.7. He was dark-complexioned and borderline overweight. No pallor, oedema, jaundice, cyanosis or abnormal pigmentation was observed.

Oral examination (including lips, buccal mucosa, floor of mouth, tongue, hard and soft palate, gums and teeth) did not reveal anything significant, except for the white patches inside the left angle of the mouth.

### Generalities

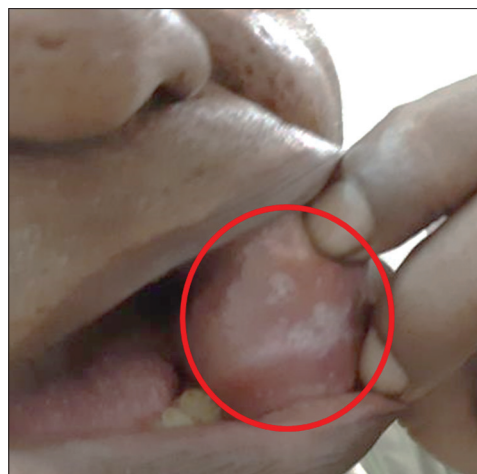The patient was very talkative, anxious and reported to have a marked fear of death. His thermal reaction was hot, with an increased appetite and profuse thirst. He had a craving for milk and preferred spicy and rich food. His bowel movement was regular, but the urge for urination was increased and he described his urine to be offensive. The patient also occasionally complained of disturbed and unrefreshing sleep.

### Diagnostic assessment

This was a diagnosed case of OL inside the left angle of the mouth (buccal mucosa) [Figure 1] verified clinically in the OPD. For further confirmation, a biopsy could not be done as the patient refused to undergo any invasive investigation, despite counselling him for the same.

### Case analysis and repertorisation

Following complete case taking in accordance with homoeopathic principles, the following characteristic



**Figure 1:** Oral leucoplakia-before treatment (27 October 2018)

symptoms were taken into consideration for repertorisation after analysis and evaluation:

- Fear of death
- Very talkative
- Hot; aggravated in a warm room
- Appetite increased
- Profuse thirst, drinks 3–4 litres of water/day
- Craving for milk
- Whitish lesion inside the left angle of the mouth (buccal mucosa)
- Pain and burning sensation over the lesion; aggravated from warm food and after eating rich and spicy food.
- Soreness on the affected buccal mucosa
- Excessive salivation
- Low back pain aggravated by walking
- Frequent urination with offensive odour.

The above symptoms were converted into rubrics and the case was repertorised using Hompath Classic M.D. Software, version 10, and Repertory of J.T. Kent<sup>[13,14]</sup> [Figure 2].

After repertorisation, *Kali iodatum* covered the maximum number of symptoms (14), with a total score of 26. *Sulphur* covered 13 symptoms, while *Calcarea carbonica* and *Natrum muriaticum* covered 12 symptoms each. The characteristic symptoms were assessed for the miasmatic background and the case was found to be psoro-syphilitic.

### Therapeutic intervention

#### Basis of prescription

Following repertorial analysis, miasmatic analysis and consultation with materia medica, considering the individualised characteristics of the patient, homoeopathic medicine *Kali iodatum* was selected as the initial prescription.<sup>[15]</sup>

#### First prescription

Four doses of potentised homoeopathic medicine, *Kali iodatum* 200C were prescribed. The medicine was manufactured by a good manufacturing practice certified pharmaceutical company and prescribed in globules sized 30. The patient was advised to take four globules of medicine twice daily on an empty

Repertorisation		Sulph	Kali-I	Calc	Nat-m	Phos	Apis	Nux-v	Merc	Nit-ac	Puls	Caust	Verat	Lyc	Als	Sep
Symptoms Covered		30	26	26	25	25	24	24	23	23	23	22	22	22	21	20
[KT] [Mind]Fear:Death,of:	Totally	13	14	12	12	11	11	11	11	11	10	12	11	10	11	9
[KT] [Mind]Loquacity:		1	2	3	1	3	2	2		3	2	2	2	2	3	1
[KT] [Generalities]Heat:Sensation of:		1	2	1	1	2	1	1				1	2		1	
[KT] [Generalities]Warm:Room agg:		3	2	2	3	2	3	2	2		3	1	2	3	1	
[KT] [Stomach]Appetite:Increased:		3	3	1	1	1	3		1	1	3	1	2	3		
[KT] [Stomach]Thirst:Extreme:		3	1	3	3		3	2	2	3	2	3	2	3	3	2
[KT] [Stomach]Desires:Milk:		3	2	3	3	3	2	2	3	2	1	3	3	2	3	2
[KT] [Mouth]Patches,syphilitic:		1	1	2	2		2	2	2						2	
[KT] [Mouth]Discoloration:White patches:			2						2	2						
[KT] [Mouth]Pain:Burning,raw and smarting:		2	1	1	2	2	2	1	2	2		2	2	1	3	2
[KT] [Mouth]Pain:Burning,raw and smarting:Eating,after:																
[KT] [Mouth]Pain:Sore:Inside of cheek:																
[KT] [Mouth]Salivation:		2	2	2	3	2	1	3	3	3	2	2	3	2	1	2
[KT] [Back]Pain:Lumbar region:		3	2	3	2	3	2	3	1	2	3	2	1	1	1	3
[KT] [Back]Pain:Lumbar region:Walking:White:		2	2							1	1	1	1			3
[KT] [Bladder]Urging to urinate:Frequent:		3	2	2	3	2	3	3	3	2	3	3	1	3	1	2
[KT] [Urine]Odour:Offensive:		3	2	3	1	2	3	2	2	3	2	2		2	2	3
Symptoms 1 to 17		Total Symptoms : 17														
		Remedies 1 to 15														
		Total Remedies : 345														

Figure 2: Repertorisation chart

stomach for 2 consecutive days. He was advised to take an adequate amount of water and to maintain proper oral hygiene.

**Follow-up and outcomes**

The patient was followed up every month or as per requirement for more than a year. During follow-ups, the change of medicine, potency and repetition of doses were done as per the guidelines of the homoeopathic philosophy. The medicines were prescribed for a limited duration as per the need and were followed by placebo pills for rest of the period. The changes in signs and symptoms, as well as medicines prescribed in every follow-up, are provided in Table 1.

The patient was questioned on the timely consumption of medication in the prescribed dose and compliance with other behavioural restrictions at every follow-up visit. During the course of homoeopathic treatment, no adverse or unanticipated events were noted.

The Modified Naranjo Criteria for Homoeopathy (MONARCH), a causal attribution inventory tool, was used to determine if there was a causal relationship between the homoeopathic intervention and the treatment outcome.<sup>[16]</sup> The MONARCH score was +8 on a scale from ‘-6 to +13’ which is indicative of possibility of the patient’s improvement resulting from the homoeopathic treatment (Table 2).

The photographs taken during the initial appointment and subsequent visits served as an objective evidence of the treatment’s outcome. These were taken during the initial visit, at 6 months and after 14 months (Figures 1, 3 and 4, respectively).

**DISCUSSION**

The development of OL, a white patch or plaque, is closely linked to smoking. The use of tobacco in any form, including

cigars, cigarettes, *bidis* and pipes, is one of the additional risk factors. Consumption of alcohol, chronic irritation, fungal infections like candidiasis and other conditions are synergistic risk factors. The preferred therapy for lesions with moderate-to-severe dysplasia is surgical excision or laser surgery.<sup>[1]</sup>

An invasive and unpleasant procedure known as biopsy from the lesion’s location is the gold standard for diagnosing leucoplakia. However, a lesser invasive procedure of brush biopsy has been introduced, of late.<sup>[17]</sup> However, in this case, the patient was diagnosed only clinically as he was not willing to go for any invasive investigation. Eliminating the underlying causes is the first step in treatment. These patients should be encouraged and supported to quit smoking.

While exploring online medical databases, we could not find any case studies related to homoeopathic treatment of OL. A case report<sup>[18]</sup> for the premalignant condition of the oesophagus, barret oesophagus and another one<sup>[19]</sup> on acute pseudomembranous candidiasis in the oral cavity was found to be treated successfully with Homoeopathy. This particular case report has the potential to inspire homoeopaths to handle this type of pre-malignant lesion such as OL and can be the stepping stone for further large-scale studies.

Based on characteristic symptoms, repertorial analysis and individualisation, homoeopathic medicine *Kali iodatum* (200C and 1M) followed by *Syphilinum* 200C were prescribed. Over the period of 14 months of treatment, the patient was better with *Kali iodatum*, while complete healing of the lesion was achieved by *Syphilinum*.

Both subjective and objective changes are included in this case report as proof of the patient’s improvement. The images taken serially clearly show the healing of the lesion inside the left angle of the mouth (buccal mucosa) [Figures 1, 3 and 4].

**Table 1: Treatment timeline including follow-ups**

Date with number of Follow-ups	Complaints/symptoms	Intervention	Justification of prescription
27 October, 2018 Baseline visit	Based on baseline symptoms	<i>Kali iodatum</i> 200C/4 doses BD×2 days	Based on the totality of symptoms, repertorial analysis and consultation with Materia Medica.
14 November 2018 First follow-up	<ul style="list-style-type: none"> <li>Whitish lesion inside the left angle of the mouth as earlier.</li> <li>Pain and burning sensation over the lesion slightly better than before.</li> <li>Excessive salivation persisting.</li> <li>Low back pain slightly improved.</li> <li>Fear of death persisting.</li> <li>Urine - frequent urging for urination persisting.</li> </ul>	No medicine was prescribed as improvement continued	The pain and burning sensation improved slightly.
05 December 2018 Second follow-up	<ul style="list-style-type: none"> <li>Whitish lesion – same as before.</li> <li>Pain and burning sensation better than before but persisting.</li> <li>Excessive salivation persisting.</li> <li>Low back pain slightly better than before.</li> <li>Mentally patient is improving.</li> <li>Urine - frequent urging for urination persisting.</li> </ul>	No medicine was prescribed as improvement continued	Patient’s condition improved further.
16 January 2019 Third follow-up	<ul style="list-style-type: none"> <li>Whitish lesion - same.</li> <li>Pain and burning -persisting.</li> <li>Excessive salivation -persisting.</li> <li>Low back pain - not further reduced.</li> <li>Fear of death- persisting.</li> <li>Urine - frequent urging for urination- persisting.</li> </ul>	<i>Kali iodatum</i> 200C/4 doses/BD×2 days	The patient’s condition came to a standstill.
23 February 2019 Fourth follow-up	<ul style="list-style-type: none"> <li>Whitish lesion slightly improved.</li> <li>Pain and burning better.</li> <li>Salivation slightly decreased.</li> <li>Low back pain better than before.</li> <li>Mentally patient is improving.</li> <li>Urine - frequent urging for urination - persisting.</li> </ul>	No medicine was prescribed as improvement continued	The patient’s condition improved than last time.
20 April 2019 Fifth follow-up	<ul style="list-style-type: none"> <li>Whitish lesion improving.</li> <li>Pain and burning better.</li> <li>Salivation decreased than before.</li> <li>Low back pain better than before.</li> <li>Mentally patient is improving.</li> <li>Urine - frequent urging for urination persisting.</li> </ul>	No medicine was prescribed as improvement continued	The patient’s condition continued to improve. The photograph of improving OL lesion was documented as Figure 3.
29 May 2019 Sixth follow-up	<ul style="list-style-type: none"> <li>Whitish lesion - improvement is standstill.</li> <li>Pain and burning sensation sometimes aggravated.</li> <li>Salivation decreased but persisting.</li> <li>Low back pain - same.</li> <li>Mentally patient is improving.</li> <li>Urine - frequent urging for urination persisting.</li> </ul>	<i>Kali iodatum</i> 1M/2doses/BD×2 days	Patient’s condition standstill.
17 July 2019 Seventh follow-up	<ul style="list-style-type: none"> <li>Whitish lesion and ulceration inside the left angle of mouth- no further improvement, standstill.</li> <li>Pain and burning sensation on lesion - aggravated &lt;at night.</li> <li>Salivation at night - not further reduced.</li> <li>Low back pain relapsed with &lt;at night.</li> <li>Urine - frequent urging for urination more at night.</li> <li>Patients have recently developed irritability and anger easily.</li> <li>No improvement from last time.</li> <li>Parallel crack on the dorsum of tongue.</li> </ul>	<i>Syphilinum</i> 200C/2 doses/OD×2 days	On the basis of the present totality of symptoms, prescription was changed.
16 August 2019 Eighth follow-up	<ul style="list-style-type: none"> <li>Whitish lesion and ulceration inside the left angle of mouth decreased than before.</li> <li>Pain and burning sensation better than before.</li> <li>Salivation slightly improved.</li> <li>Low back pain better than before.</li> <li>Urine - frequent urging for urination slightly improved.</li> </ul>	No medicine was prescribed as improvement continued	The patient as a whole better than last time.

(Contd...)

**Table 1: (Continued)**

Date with number of Follow-ups	Complaints/symptoms	Intervention	Justification of prescription
21 September 2019 Ninth follow-up	<ul style="list-style-type: none"> <li>Whitish lesion and ulceration inside the left angle of mouth decreased than before but persisting.</li> <li>Pain and burning sensation better than before but persisting.</li> <li>Salivation better than before.</li> <li>Low back pain better.</li> <li>Urine - frequent urging for urination slightly improved but persisting.</li> </ul>	<i>Syphilinum</i> 200C/2 doses/ OD×2 days	The patient's condition was improving. For complete cure <i>Syphilinum</i> was repeated.
16 November 2019 Tenth follow-up	<ul style="list-style-type: none"> <li>Whitish lesion and ulceration much decreased than before.</li> <li>Pain and burning sensation much better.</li> <li>Salivation better than before.</li> <li>Low back pain better.</li> <li>Urine - frequent urging for urination improved than before.</li> </ul>	No medicine was prescribed as improvement continued	The patient's condition was better.
04 December 2019 Eleventh follow-up	<ul style="list-style-type: none"> <li>Whitish lesion and ulceration better.</li> <li>Pain and burning sensation better.</li> <li>Salivation not present.</li> <li>Low back pain better.</li> <li>Urine - frequent urging for urination better.</li> </ul>	No medicine was prescribed as improvement continued	The patient's condition was improved as a whole. Photograph of improved OL lesions was documented in Figure 4.

The patient was contacted telephonically recently to enquire about the OL lesion. He informed that there was no recurrence of the lesion.

**Table 2: Assessment of outcome of treatment by Modified Naranjo Criteria for Homeopathy**

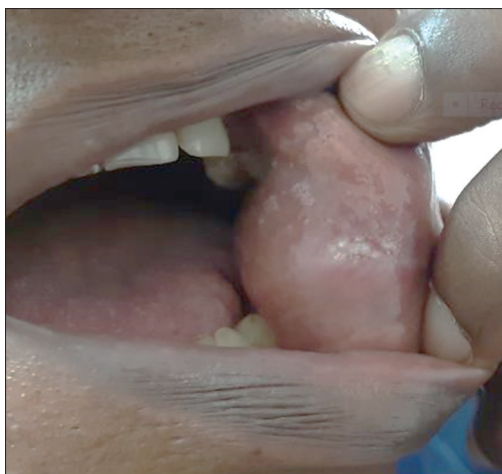S. No.	Domains	Yes	No	Not sure or N/A
1.	Was there an improvement in the main symptom or condition for which the homoeopathic medicine was prescribed?	+2		
2.	Did the clinical improvement occur within a plausible timeframe relative to the medicine intake?	+1		
3.	Was there a homeopathic aggravation of symptoms?		0	
4.	Did the effect encompass more than the main symptom or condition (i.e., were other symptoms, not related to the main presenting complaint, improved or changed)?	+1		
5.	Did overall well-being improve? (suggest using a validated scale or mention about changes in physical, emotional and behavioural elements)	+1		
6.	(A) Direction of cure: Did some symptoms improve in the opposite order of the development of symptoms of the disease?			0
	(B) Direction of cure: Did at least one of the following aspects apply to the order of improvement of symptoms: -from organs of more importance to those of less importance? -from deeper to more superficial aspects of the individual? -from the top downwards?			0
7.	Did 'old symptoms' (defined as non-seasonal and non-cyclical symptoms that were previously thought to have resolved) reappear temporarily during the course of improvement?			0
8.	Are there alternative causes (i.e., other than the medicine) that – with a high probability – could have produced the improvement? (consider known course of disease, other forms of treatment and other clinically relevant interventions)	+1		
9.	Was the health improvement confirmed by any objective evidence? (e.g., investigations, clinical examination, etc.)	+2		
10.	Did repeat dosing, if conducted, create similar clinical improvement?			0
	Total score= +8			
	Note: Maximum score= +13, minimum score= -6			

N/A=Not available

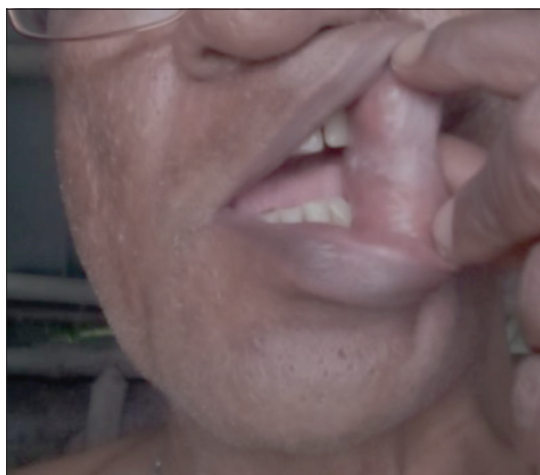In this case, the total outcome score as per Modified Naranjo Criteria was +8, close to the maximum score +13 [Table 2]. This clearly demonstrates the positive causal attribution of the individualised homoeopathic treatment towards this case of OL.

In several clinical conditions, Homoeopathy has been demonstrated to be a beneficial alternative to surgery.

Although Homoeopathy never claims to challenge the domain of true surgical diseases, it is true to argue that there are several occasions where surgery can be avoided with proper homoeopathic treatment.<sup>[20]</sup> The findings of this case report have the potential to inspire and advance clinical knowledge, which will assist patients who are dealing with OL, a potentially cancerous lesion, as well as the risks associated with surgical excision.



**Figure 3:** Oral leucoplakia-during treatment (20 April 2019)



**Figure 4:** Oral leucoplakia-after treatment (4 December 2019)

## CONCLUSION

This case report of OL, a premalignant lesion, demonstrated positive outcomes after homeopathic intervention. By adhering to the principle of individualisation in Homeopathy, the patient showed improvement in all physical, mental and pathological aspects. To scientifically confirm the result, similar case studies and clinical trials are needed with a bigger sample size.

## Declaration of patient consent

The authors have obtained written, informed consent from the concerned patient to publish his case records, with all possible attempt to not revealing his identity.

## Financial support and sponsorship

The authors declare that they have not received any financial support or sponsorship for publishing this case report.

## Conflict of interest

None declared.

## REFERENCES

1. Mohammed F, Fairozekhan AT. Oral leukoplakia. In: StatPearls. Treasure Island, FL: StatPearls Publishing; 2022. Available from: <https://www.ncbi.nlm.nih.gov/books/NBK442013> [Last accessed on 2024 May 12].
2. Van der Waal I, Axell T. Oral leukoplakia: A proposal for uniform reporting. *Oral Oncol* 2002;38:521-6.
3. Van der Waal I, Schepman KP, van der Meij EH, Smeele LE. Oral leukoplakia: A clinicopathological review. *Oral Oncol* 1997;33:291-301.
4. Neville BW, Day TA. Oral cancer and precancerous lesions. *CA Cancer J Clin* 2002;52:195-215.
5. Zhang L, Cheung KJ Jr, Lam WL, Cheng X, Poh C, Priddy R, *et al*. Increased genetic damage in oral leukoplakia from high risk sites: Potential impact on staging and clinical management. *Cancer* 2001;91:2148-55.
6. Schepman KP, van der Meij EH, Smeele LE, van der Waal I. Malignant transformation of oral leukoplakia: A follow-up study of a hospital-based population of 166 patients with oral leukoplakia from The Netherlands. *Oral Oncol* 1998;34:270-5.
7. Saito T, Sugiura C, Hirai A, Notani K, Totsuka Y, Shindoh M, *et al*. Development of squamous cell carcinoma from pre-existent oral leukoplakia: With respect to treatment modality. *Int J Oral Maxillofac Surg* 2001;30:49-53.
8. Reibel J. Prognosis of oral pre-malignant lesions: Significance of clinical, histopathological, and molecular biological characteristics. *Crit Rev Oral Biol Med* 2003;14:47-62.
9. Lodi G, Porter S. Management of potentially malignant disorders: Evidence and critique. *J Oral Pathol Med* 2008;37:63-9.
10. Napier SS, Speight PM. Natural history of potentially malignant oral lesions and conditions: An overview of the literature. *J Oral Pathol Med* 2008;37:1-10.
11. Van der Waal I. Potentially malignant disorders of the oral and oropharyngeal mucosa; Terminology, classification and present concepts of management. *Oral Oncol* 2009;45:317-23.
12. Van Haselen RA. Homeopathic clinical case reports: Development of a supplement (HOM-CASE) to the CARE clinical case reporting guideline. *Complement Ther Med* 2016;25:78-85.
13. Kent JT. *Repertory of the Homeopathic Materia Medica*. Reprint ed. New Delhi: B. Jain Publishers Pvt. Ltd; 1999.
14. Shah J. *Homopath Classic M.D Repertory*. Ver. 1.0. Mumbai, India: Mind Technologies Pvt. Ltd.; 2002.
15. Boericke W. *Pocket Manual of Homeopathic Materia Medica and Repertory*. 50<sup>th</sup> Impression. New Delhi: B. Jain Publisher (P) Ltd.; 2010.
16. Lamba CD, Gupta VK, Van Haselen RA, Rutten L, Mahajan N, Molla AM, *et al*. Evaluation of the modified Naranjo Criteria for assessing causal attribution of clinical outcome to homeopathic intervention as presented in case reports. *Homeopathy* 2020;109:191-7.
17. Goodson ML, Smith DR, Thomson PJ. Efficacy of oral brush biopsy in potentially malignant disorder management. *J Oral Pathol Med* 2017;46:896-901.
18. Gupta N. Homeopathic perspective in treating a case of Barrett's Oesophagus. *The Homeopathic Heritage* 2015;41:21-6.
19. Khanam H, Halder S. Acute pseudomembranous candidiasis is treated successfully with homeopathy-An evidence based homeopathic case report. *Int J Ayush Case Rep* 2023;7:320-6.
20. Parikh N. True surgical cases in homeopathy a different territory. *Homeopath Links* 2015;28:27-32.



## Traitement homéopathique de la leucoplasie buccale: un cas

**Introduction:** La leucoplasie buccale (OL), lésion précancéreuse plus fréquemment rencontrée chez les personnes âgées, est définie comme une lésion blanche de la muqueuse buccale. Le tabagisme est l'un des facteurs de risque les plus courants. Traditionnellement, l'excision chirurgicale est l'option de traitement la plus recommandée pour l'OL. **Résumé de cas:** Un homme de 55 ans s'est plaint d'une lésion blanchâtre à l'intérieur de l'angle gauche de la bouche (muqueuse buccale) depuis 1 an. Le cas a été diagnostiqué cliniquement comme OL. On lui conseilla l'excision chirurgicale, mais il préféra opter pour un traitement homéopathique. Sur la base des symptômes caractéristiques, de l'analyse du répertoire et de l'individualisation, un médicament homéopathique *Kali iodatum* (200C et 1M) suivi de *Syphilinum* 200C a été prescrit. Après 14 mois de traitement, l'état du patient s'est d'abord amélioré avec *Kali iodatum*, suivi d'une rémission totale de la lésion par *Syphilinum*. Les critères modifiés de Naranjo pour l'homéopathie (MONARCH) ont été utilisés pour évaluer l'attribution de la guérison au traitement homéopathique. Le score MONARCH était de (+8 sur une échelle de « -6 à +13 »), ce qui indique la possibilité d'amélioration du patient résultant du traitement homéopathique. Ce rapport de cas clinique démontre les effets bénéfiques d'un traitement homéopathique individualisé pour la prise en charge des lésions précancéreuses comme l'OL.

## Homöopathische Behandlung der oralen Leukoplakie: Ein Fallbericht

**Einleitung:** Orale Leukoplakie (OL), eine prämaligene Läsion, die häufiger bei älteren Menschen auftritt, ist definiert als eine weiße Läsion der Mundschleimhaut. Rauchen ist einer der häufigsten Risikofaktoren. Herkömmlicherweise ist die chirurgische Exzision die am meisten empfohlene Behandlungsoption für OL. **Fallzusammenfassung:** Ein 55-jähriger Mann klagte in den letzten 11/2 Jahren über eine weißliche Läsion im linken Mundwinkel (Wangenschleimhaut). Der Fall wurde klinisch als OL diagnostiziert. Ihm wurde eine chirurgische Exzision empfohlen, aber er zog es vor, sich homöopathisch behandeln zu lassen. Basierend auf charakteristischen Symptomen, Repertorialanalyse und Individualisierung wurde das homöopathische Arzneimittel *Kaliiodatum* (200C und 1M) gefolgt von *Syphilinum* 200C verschrieben. Während der 14-monatigen Behandlung verbesserte sich der Patient zunächst mit *Kali iodatum*, gefolgt von einer vollständigen Remission der Läsion durch *Syphilinum*. Modifizierte Naranjo-Kriterien für die Homöopathie (MONARCH) wurden verwendet, um die Zuordnung der Genesung zu einer homöopathischen Behandlung zu bewerten. Der MONARCH-Score betrug (+8 auf einer Skala von -6 bis +13), was auf die Möglichkeit einer Besserung des Patienten durch die homöopathische Behandlung hinweist. Dieser klinische Fallbericht zeigt die vorteilhaften Auswirkungen einer individualisierten homöopathischen Behandlung auf die Behandlung von prämaligen Läsionen wie OL.

## ओरल ल्यूकोप्लेकिया का होम्योपैथी उपचार: एक केस की रिपोर्ट

**परिचय:** ओरल ल्यूकोप्लेकिया (ओएल), एक कैंसरपूर्व विकृति है, जो बुजुर्ग लोगों में अधिकतर पाया जाता है। इसको मौखिक श्लेष्म के सफेद घाव के रूप में परिभाषित किया गया है। धूम्रपान सबसे सामान्य जोखिम कारकों में से एक है। परंपरागत रूप से, सर्जरी ओएल के लिए सबसे अनुशंसित उपचार विकल्प है। **केस सारांश:** एक 55 वर्षीय पुरुष को पिछले 1 वर्ष 06 महीने से मुंह के बाएँ कोण (मुख श्लेष्म) के अंदर एक सफेद घाव की शिकायत के साथ प्रस्तुत किया गया था। मामले को चिकित्सकीय रूप से ओरल ल्यूकोप्लेकिया के रूप में निदान किया गया था। उन्हें सर्जरी की सलाह दी गई थी, लेकिन उन्होंने होम्योपैथी उपचार के लिए जाना बेहतर समझा। विशिष्ट लक्षणों, प्रदर्शनों के विश्लेषण और वैयक्तिकरण के आधार पर, होम्योपैथी दवा काली आयोडेटम (200C और 1M) के बाद सिफिलिनम 200C विहित की गई। उपचार के 14 महीनों में, रोगी को आराम मिल गया। शुरू में काली आयोडेटम के साथ सुधार हुआ, इसके बाद सिफिलिनम द्वारा घाव का निवारण हुआ। होम्योपैथी के लिए संशोधित नारंजो मानदंड (एमओआरएएन) का उपयोग होम्योपैथी उपचार के पुनर्प्राप्ति का मूल्यांकन करने के लिए किया गया था। मोनार्क स्कोर ('-6 से +13' पैमाने पर +8) था, जो होम्योपैथी उपचार के परिणामस्वरूप रोगी के सुधार की संभावना का संकेत है। यह नैदानिक मामले की रिपोर्ट ओरल ल्यूकोप्लेकिया जैसे घावों के प्रबंधन के लिए व्यक्तिगत होम्योपैथी उपचार के लाभकारी प्रभावों को प्रदर्शित करती है।

## Tratamiento homeopático de la leucoplasia oral: reporte de un caso

**Introducción:** La leucoplasia oral (OL), una lesión premaligna que se encuentra con mayor frecuencia en personas de edad avanzada, se define como una lesión blanca de la mucosa oral. El tabaquismo es uno de los factores de riesgo más comunes. Convencionalmente, la escisión quirúrgica es la opción de tratamiento más recomendada para la OL. **Resumen del caso:** Varón de 55 años de edad que presentó la queja de una lesión blanquecina en el interior del ángulo izquierdo de la boca (mucosa bucal) de los últimos 1 años y medio. El caso fue diagnosticado clínicamente como OL. Se le aconsejó una extirpación quirúrgica, pero prefirió someterse a un tratamiento homeopático. Sobre la base de los síntomas característicos, el análisis del repertorio y la individualización, se prescribió la medicina homeopática *Kali iodatum* (200C y 1M) seguida de *Syphilinum* 200C. A lo largo de 14 meses de tratamiento, el paciente mejoró inicialmente con *Kali iodatum* seguido de una remisión total de la lesión por *Syphilinum*. Se utilizó el Criterio de Naranjo Modificado para la Homeopatía (MONARCH) para evaluar la atribución de la recuperación al tratamiento homeopático. La puntuación MONARCH fue de (+8 en una escala de -6 a +13), lo que es indicativo

de la posibilidad de mejoría del paciente como resultado del tratamiento homeopático. Este caso clínico demuestra los efectos beneficiosos del tratamiento homeopático individualizado para el manejo de lesiones premalignas como la OL.

### 口腔白斑的顺势疗法治疗：病例报告

**简介：**口腔白斑（OL）是一种在老年人中更常见的癌前病变，被定义为口腔粘膜的白色病变。吸烟是最常见的危险因素之一。传统上，手术切除是OL最推荐的治疗选择。**病例摘要：**一名 55 岁男性主诉口腔左角（颊黏膜）内白色病变，过去 1 年半。该病例临床诊断为OL。医生建议他进行手术切除，但他更愿意接受顺势疗法治疗。根据特征性症状、复述分析和个体化，开具顺势疗法药物 *Kali iodatum* (200C 和 1M)，然后是梅毒 200C。经过 14 个月的治疗，患者最初使用 *Kali iodatum* 改善，随后通过梅毒治疗病变完全缓解。改良的 Naranjo 顺势疗法标准（MONARCH）用于评估顺势疗法治疗的恢复归因于顺势疗法。MONARCH 评分为 (+8 在“-6 至 +13”范围内)，这表明顺势疗法治疗有可能改善患者。这份临床病例报告展示了个体化顺势疗法治疗对治疗 OL 等癌前病变的有益效果。