

Homoeopathic treatment of a diabetic COVID-19 patient with the complication of bronchitis and pleural effusion - A case report

Alok Ghosh, Sadia Kamal*

The Calcutta Homoeopathic Medical College and Hospital, Machuabazar, Kolkata, West Bengal, India

Abstract

Introduction: COVID-19 is a novel SARS-CoV-2 disease that has caused a worldwide pandemic. It is highly contagious and produces severe acute respiratory syndrome. Many homoeopathic medicines have been suggested for treatment of COVID cases and reports have also been published. **Case Summary:** The present case report is of a 61-year-old COVID-positive, male, presenting with complications such as bronchitis and pleural effusion. He was treated for COVID-19 with a suitable homoeopathic medicine, based on the totality of symptoms, while the patient continued his regular regime of conventional medicine for diabetes mellitus and hypertension. The indicated remedy led to immediate relief of the symptoms, especially chest pain, along with a marked improvement in the laboratory investigations. The Modified Naranjo Criteria score after treatment was 8, which explicitly shows the positive causal attribution of the individualised homoeopathic medicine, *Phosphorus*, in this case. Homoeopathic treatment has shown favourable results in this case and demonstrates the scope of Homoeopathy in infectious cases.

Key words: Bronchitis, COVID-19, Homoeopathy, Phosphorus, Pleural effusion, SARS CoV-2

INTRODUCTION

COVID-19 is a highly contagious viral illness caused by severe acute respiratory syndrome coronavirus 2 (SARS-CoV-2). Standard treatment is yet to be discovered by the conventional system for this illness. The most common pharmacological interventions used are antivirals, dexamethasone, monoclonal antibodies, etc. These therapies are highly targeted and focus on reducing viral load.^[1] Reverse transcription-polymerase chain reaction RT-PCR or computed tomography (CT) scan of the chest are done to diagnose this infection.^[2,3] Pneumonia and pleural effusion are among the recognised complications of COVID-19.^[4]

India reported its first case of COVID-19 on 30 January 2020. This rose to three cases by February 3, 2020. No further cases were reported in February 2020. However, by mid-March, the number of infected cases started to increase and many cases were reported from all over India. The first COVID-19-related death in India was reported on March 12, 2020. Till 22 February 2022, there have been

418,650,474 confirmed cases and 5,856,224 deaths globally and 42,838,524 cases and 512,141 deaths in India.^[5,6] Homoeopathic literature enlists many medicines for COVID 19 such as *Arsenicum album*, *Bryonia alba*, *Gelsemium sempervirens* and *Pulsatilla nigricans* from a prognostic factor research.^[7]

A case report of COVID-19 complicated with pleural effusion and bronchitis successfully treated with homoeopathic medicine *Phosphorus* is presented here. This case has been reported according to the Hom-Case extension to the CARE clinical case reporting guideline and highlights the effectiveness of homoeopathy for the treatment of COVID 19 and its associated conditions, following the basic principles of homoeopathy.^[8]

***Address for correspondence:** Dr. Sadia Kamal,
The Calcutta Homoeopathic Medical College and Hospital, 265-266, A.P.C.
Road, Kolkata - 700 009, West Bengal, India.
E-mail: sadiakamal206@gmail.com

Received: 18 March 2022; **Accepted:** 05 December 2022

Access this article online

Quick Response Code:

Available in print
version only

Website:
www.ijrh.org

DOI:
10.53945/2320-7094.1180

This is an open access journal, and articles are distributed under the terms of the Creative Commons Attribution-NonCommercial-ShareAlike 4.0 License, which allows others to remix, tweak, and build upon the work non-commercially, as long as appropriate credit is given and the new creations are licensed under the identical terms.

How to cite this article: Ghosh A, Kamal S. Homoeopathic treatment of a diabetic COVID-19 patient with the complication of bronchitis and pleural effusion - A case report. *Indian J Res Homoeopathy* 2022;16(4):301-307.

PATIENT INFORMATION

A 61-year-old diabetic male patient presented with cough and chest pain in the lower left lateral side, with shortness of breath for 4 days at the time of the visit. The patient could not sleep and had to sit up at night to breathe. Previously, the patient was admitted to a rural hospital but the chest pain and respiratory discomfort continued and the attendants decided to shift him to another super speciality hospital. However, that could not be done due to the non-availability of a bed, and ultimately, the patient returned home, where he took treatment in isolation and consulted us on 15 January 2022.

The patient reported pain on the left lower side of the chest since 9 January 2022, which aggravated on lying on the left side, on the back and at night. There was a catching pain on deep breathing with shortness of breath. His cough had rusty sputum. The patient was suffering from type 2 diabetes for 12 years and he was under medication for diabetes and hypertension and was taking conventional medicines for the same. As the patient party searched many hospitals for admission but there were no beds available in the hospitals, so the patient had to be treated at home in isolation.^[9,10]

The patient had a poor appetite and nausea, with loathing of food and normal thirst. He also complained of tastelessness and acuteness of smell with intolerance of the smell of cooking food. His sleep was disturbed due to chest pain and he could not breathe properly while lying. His stool was offensive. On enquiring, it was informed that when his complaints began, he had profuse sweat and episodes of bedwetting.

Mental generals

The patient was cooperative and very talkative. Although excess talking exhausted him, he narrated his complaints in detail. During illness, he was afraid of being alone and wanted his family members to be present by his side all the time. He was anxious about his illness. He was interpreted to be of jealous nature since he expressed his jealousy towards his brothers for property possessions. He said he was not satisfied with the distribution of family property by his father, which had occurred a long time ago.

The patient did not suffer from any other major illness in the past, except type 2 diabetes mellitus, for which he was under medication. Family history was not significant.

Clinical findings

There was a pain in the left lower side of the chest, which was aggravated by lying on the affected side and on the back. On examination, a catching pain in the chest during deep breathing was noted. His blood pressure was normal, pulse rate 86/min and respiratory rate was 22/min. The patient was afebrile at the time of the visit and weighed 68 kg. Oxygen saturation was also normal. ECG done for left-sided chest pain, just before discharge from the previous rural hospital, was found normal.

Diagnostic assessment

The patient was already diagnosed with COVID-19 infection through RT-PCR on 11 January 2022 and we advised some laboratory investigations to know the present status. The readings are summarised in Table 1. The SpO₂ was normal and so oxygen support was not required at the moment. The patient was, however, also advised to continue searching for a hospital bed and consult a conventional medicine practitioner. Meanwhile, though, the patient was kept under isolation along with the homoeopathic medication.^[11]

Therapeutic intervention

A detailed case-taking was done as per Hahnemannian guidelines laid out in the *Organon of Medicine*, followed by analysis and evaluation of the symptoms.^[12] The totality of symptoms was selected. The left-sided pain in the chest aggravated after sleeping and the patient was very loquacious and jealous in nature. Based on these symptoms, *Lachesis mutens* 0/1 BD was prescribed for 3 days on 15 January 2022. There was, however, no improvement after taking *Lachesis* in the next 3 days.

The case was then re-investigated and it was found that the chest pain was aggravated after lying in bed and not after sleep. The repertorisation was done taking into account only the most striking mental generals, physical generals and uncommon particulars using Dr James Tyler Kent's repertory. Repertorisation result is shown in Figure 1. The following symptoms were considered for repertorisation:

1. Company desire for
2. Acuteness of smell
3. Profuse sweat at night
4. Stool offensive
5. Pleural effusion left side
6. Chest pain left side
7. Chest pain aggravates on lying on the left side, on the painful side

Table 1: Summary of investigation reports

Investigations	Before treatment	After treatment
D-dimer	1151 ng FEU/mL (up to 500 ng FEU/mL)	2.09 ng FEU/mL (upto 500 ng FEU/mL)
CRP	83.74 mg/L (<5 mg/L)	17.64 mg/L (<5 mg/L)
Ferritin	692.5 ng/mL (22–322 ng/mL)	244 ng/mL (22–322 ng/mL)
TLC	10.69 × 10 ³ /uL (4–10)	8.3 × 10 ³ /uL (4–10)
LDH	307 U/L (120–246)	218 U/L (120–246)
HRCT Thorax	Focal consolidation seen in left lower lobe. Bronchitis. Left pleural effusion. Figure 3 (CT severity score was not mentioned in the report)	No pleural effusion. Very low CT severity score 3/40 Figure 4

8. Chest pain aggravates lying on back
9. Rusty expectoration.

After repertorisation, *Phosphorus* 30°C was prescribed upon final consultation with *Materia Medica*.^[13] As the case was acute and symptoms were very intense and striking, *Phosphorus* was selected as the best similimum to the case. One dose of the medicine was given for 2 days.

Follow-up and outcome

Following the remedy, there was a marked improvement on the very 1st day and the patient was able to sleep comfortably from the 2nd day onward, after a long time. Date-wise follow-ups with results of investigations are summarised in Tables 1 and 2. Figure 2 gives the timeline of the case.

In this case, the total score of outcomes, as per Modified Naranjo Criteria was 9, which is close to the total score of 13 and explicitly shows the positive causal attribution of the individualised homoeopathic medicine, phosphorus [Table 3].^[14]

Improvement started immediately after medicine of appropriate potency was given to the patient. The patient reported overall relief in signs and symptoms, such as chest pain, lying on the left side, the acuteness of smell and improved appetite.

Marked improvement in the laboratory investigation reports of 22 January 2022 and HRCT Chest done on 2 February 2022 also confirmed the same. No adverse event was reported during the course of treatment.

DISCUSSION

Homoeopathy is a system of medicine which embraces a holistic approach to the treatment of a diseased person. In homoeopathy, detailed case-taking is done to draw a totality of symptoms and a single remedy is selected on the basis of the totality of symptoms.

The spectrum of COVID-19 symptoms is broad, ranging from a mild, self-limiting respiratory tract illness to severe progressive pneumonia, multi-organ failure and possible death. Despite many efforts and multiple clinical trials, there are, to date, no specific therapeutic agents to treat or cure the coronavirus infection. A case series of five patients with moderate to severe COVID-19 infections, 2 of them hospitalised in the intensive care unit and successfully treated with homoeopathy, has been reported. All five patients responded to homoeopathic treatment in an unexpectedly short time span, improving both physically and mentally.^[15] A randomised, placebo-controlled trial of adjunct homoeopathy

Remedy Name	Phos	Sulph	Ars	Lyc	Bry	Arg-n	Kali-ar	Hep	Carb
Totally	22	16	14	14	13	11	11	10	10
Symptoms Covered	9	7	6	6	6	5	5	6	5
Kingdom									
[Kent] [Mind]Company:Desire for:	3		3	3	1	3	2	1	
[Kent] [Nose]Smell:Acute:	3	2	2	3	1		1	2	2
[Kent] [Perspiration]Profuse:Night:	3	3	2	2	2	1	3	3	2
[Kent] [Stool]Odour:Offensive:	2	3	3	1	3	3	3	1	3
[Kent] [Chest]Pain:Lying:Painful side,on:Left:	3								
[Kent] [Chest]Pain:Lying:Back:On agg:		1							
[Kent] [Chest]Pain:Sides:Left:	3	2				2		1	1
[Kent] [Chest]Inflammation:Pleura:	2	3	2		3	2	2	2	2
[Kent] [Chest]Hepatisation of lungs:Left:	1	2		2					
[Kent] [Expectoration]Rusty:	2		2	3	3				

Figure 1: Repertorial sheet

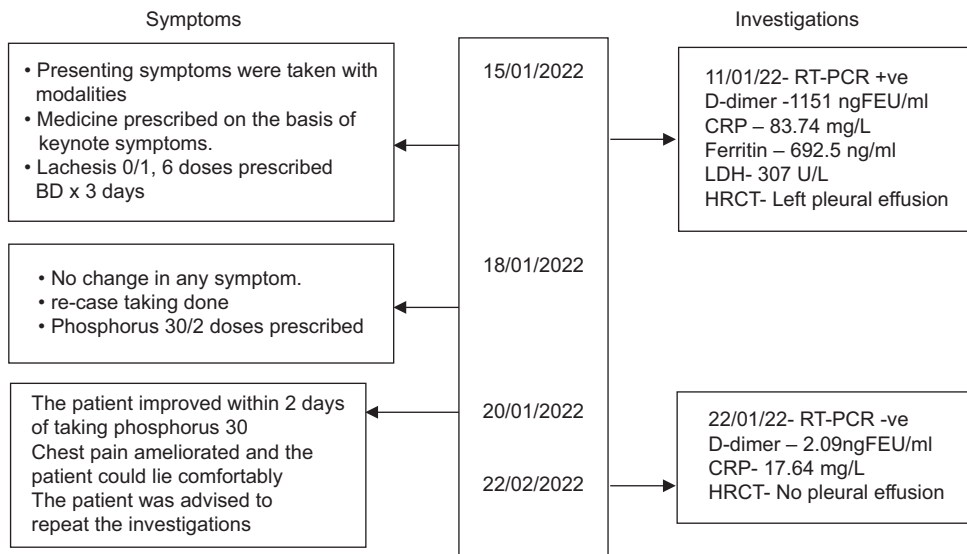


Figure 2: Timeline

Table 2: Follow-up and outcomes

Date	Indication for prescription	Medicine with dose and repetition	Justification
15 January 2022	Left-sided chest pain Chest pain aggravates on sleeping Loquacious, jealous.	<i>Lachesis</i> 0/1, 6 doses BD×3 days	Lt-sided chest affection Pt could not sleep at night Loquacity, jealous
18 January 2022	No relief. Left-sided chest pain <Lying on the painful side, left <Lying on back Rusty sputum	<i>Phosphorus</i> 30°C, 2 doses OD for 2 days	Left-sided pleural effusion Can't lie on the left [affected] side, as well as on the back. Company desire for, catching pain during deep breathing.
20 January 2022	The patient can lie comfortably	Placebo	Very rapid improvement noticed after <i>Phosphorus</i> 30
24 January 2022	The patient was much better	Placebo	The patient improved very much. The reports of 22 January 2022 within normal
04 February 2022	No more discomfort	Placebo	The patient is much better. HRCT report shows no effusion.

Table 3: Assessment by Modified Naranjo criteria score

Item	Yes	No	Not sure/NA
1. Was there an improvement in the main symptom or condition for which the homeopathic medicine was prescribed?	+2		
2. Did the clinical improvement occur within a plausible time frame relative to the medicine intake?	+1		
3. Was there a homeopathic aggravation of symptoms?		0	
4. Did the effect encompass more than the main symptom or condition (i.e., were other symptoms, not related to the main presenting complaint, improved or changed)?	+1		
5. Did overall well-being improve?	+2		
6. A. Direction of cure: Did some symptoms improve in the opposite order of the development of symptoms of the disease?			0
7. B. Direction of cure: Did at least one of the following aspects apply to the order of improvement of symptoms: • From organs of more importance to those of less importance? • From deeper to more superficial aspects of the individual? • From the top downwards?			0
8. Did old symptoms (defined as non-seasonal and non-cyclical that were previously thought to have resolved) reappear temporarily during the course of improvement?		0	
9. Are there alternative causes (i.e., other than the medicine) that with a high probability - could have caused the improvement? (consider known course of disease, other forms of treatment and other clinically relevant intervention)			0
10. Was the health improvement confirmed by any objective evidence? (e.g., investigations and clinical examination)	+2		
11. Did repeat dosing, if conducted, create similar clinical improvement?	0		
Total	8		

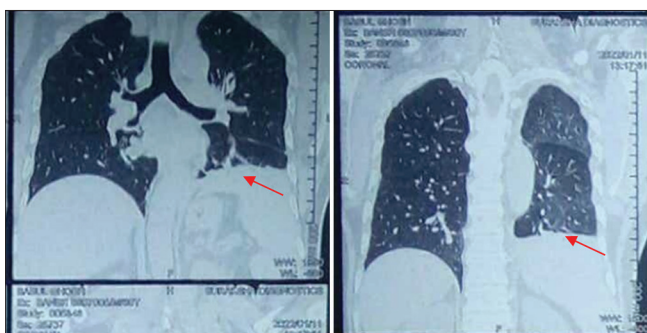


Figure 3: HRCT dated 11 January 2022 (arrow showing the lower margin of the left lung is not clear due to pleural effusion)

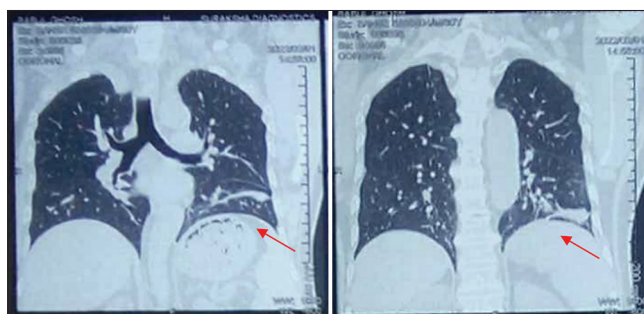


Figure 4: HRCT dated 02 February 2022 (arrow showing clear lower margin of the left lung)

with the standard of care for COVID-19 was conducted on 300 patients, which significantly favoured the use of standard of care and homeopathy. *A. album* and *Phosphorus* were the most frequently prescribed medicines.^[16] There is another case report on individualised homeopathic treatment in a case of severe acute thromboinflammation in a COVID 19 patient in

which the inflammatory parameters improved dramatically within the first 12 h and complete resolution was demonstrated after 10 days.^[17] This case report is an evidence of how the use of homeopathy right from the beginning of a disease can help even in a serious clinical condition. In the present case, initially, the symptoms of the patient were misinterpreted as the aggravation of lying was misinterpreted as aggravation from

sleep. Therefore, the selected remedy, *Lachesis*, gave no relief to the patient. But when the symptoms were verified again, then the most similar remedy turned out to be *Phosphorus*, which brought immediate relief to the patient. This individualised approach in the treatment of COVID 19, backed with all the laboratory reports in support of the successful treatment has shown favourable results and undoubtedly thrown some light on the scope of homeopathy in such virulent conditions. The outcome of interest, in this case, was a rapid improvement of the patient's condition which was evident from the HRCT reports, along with the reduction in other inflammatory markers and possibly a prevention of other associated complications. Controlled studies, with long-term follow-ups and large sample sizes, are required for validation of these results.

Patient perspective

The patient said that after 11 days of intense suffering, he could now lie comfortably on his back and sleep well.

Informed consent

A written informed consent was obtained from the patient for reporting this case.

CONCLUSION

This case shows the positive response of individualized homeopathic treatment in a complicated case of covid 19 within a short span of time along with the marked improvement of laboratory parameters. This may suggest that in future, homeopathic treatments can be given preference for such infectious viral diseases under careful observation of a homeopathic physician.

REFERENCES

- Tellez D, Dayal S, Phan P, Mawley A, Shah K, Consunji G, *et al.* Analysis of COVID-19 on diagnosis, vaccine, treatment, and pathogenesis with clinical scenarios. *Clin Pract* 2021;11:309-21.
- Goudouris ES. Laboratory diagnosis of COVID-19. *J Pediatr (Rio J)* 2021;97:7-12.
- Awulachew E, Diriba K, Anja A, Getu E, Belayneh F. Computed Tomography imaging features of patient with COVID-19: Systematic review and meta-analysis. *Radiol Res Pract* 2020;2020:1023506.
- Ahmadinejad Z, Salahshour F, Dadras O, Rezaei H, SeyedAlinaghi SA. Pleural effusion as sign of coronavirus disease 2019 (COVID-19) pneumonia: A case report. *Infect Disord Drug Targets* 2021;21:468-72.
- World Health Organization. COVID-19 Dashboard. Geneva: World Health Organization; 2022. Available from: <https://covid19.who.int> [Last accessed on 2022 Feb 21].
- Available from: <https://www.worldometers.info/coronavirus/country/india> [Last accessed on 2022 Feb 21].
- Manchanda RK, Miglani A, Gupta M, Meena BS, Chadha V, Joseph F, *et al.* Homeopathic remedies in COVID-19: Prognostic factor research. *Homeopathy* 2021;110:160-7.
- van Haselen RA. Homeopathic clinical case reports: Development of a supplement (HOM-CASE) to the CARE clinical case reporting guideline. *Complement Ther Med* 2016;25:78-85.
- Advisory from Ministry of AYUSH for Meeting the Challenge Arising Out of Spread of Corona Virus (COVID-19) in India. Available from: <https://www.ayush.gov.in/docs/25.pdf> [Last accessed on 2022 Nov 23].
- Ministry of Ayush. Guidelines for Homeopathy Practitioners for Prophylaxis and Symptomatic Management of Home Isolated COVID-19 Patients. Available from: <https://www.ayush.gov.in/docs/CCRH%20Revised%20Guidelines%20for%20Homeopathy%20Practitioners%20for%20Home%20Isolated%20COVID%2019%20patient-f.pdf> [Last accessed on 2022 Nov 23].
- Guidelines for Homeopathic Practitioners for COVID-19. Available from: <https://www.ayush.gov.in/docs/homeopathy-guidelines.pdf> [Last accessed on 2022 Nov 23].
- Hahnemann S. *Organon of Medicine*. 5th ed. New Delhi: B. Jain Publishers; 2002.
- Boericke W, Boericke OE. *Pocket Manual of Homoeopathic Materia Medica Comprising the Characteristic and Guiding Symptoms of All Remedies*. 9th ed. Philadelphia, PA: Boericke and Runyon, Inc.; 1927.
- Lamba CD, Gupta VK, van Haselen R, Rutten L, Mahajan N, Molla AM. Evaluation of the modified Naranjo criteria for assessing causal attribution of clinical outcome to homeopathic intervention as presented in Case reports. *Homeopathy* 2020;109:191-7.
- Kurd R, Freed Y, Jarjoui A, Izbicki G, Levin P, Helvitz Y, *et al.* Homeopathic treatment for COVID-19-related symptoms: A case series. *Complement Med Res* 2022;29:83-8.
- Nayak D, Gupta J, Chaudhary A, Singh KG, Deshmukh A, Das D, *et al.* Efficacy of individualized homeopathy as an adjunct to standard of care of COVID-19: A randomized, single-blind, placebo-controlled study. *Complement Ther Clin Pract* 2022;48:101602.
- Waisse S. Severe acute thromboinflammation: Case report of individualized homeopathic treatment. *Homeopathy* 2021;110:132-6.

Traitement homéopathique d'un patient diabétique Covid-19 avec une complication de bronchite et d'épanchement pleural: un rapport de cas.

Introduction: Le COVID-19 est un nouveau SARS-CoV-2 qui a provoqué une pandémie mondiale. Elle est hautement contagieuse et produit un syndrome respiratoire aigu sévère. De nombreux médicaments homéopathiques ont été proposés pour le traitement des cas de covid et des rapports ont également été publiés.. **Résumé du cas:** Le présent rapport concerne un homme de 61 ans, Covid-positif, présentant des complications telles que bronchite et épanchement pleural. Il a été traité pour le COVID-19 avec un médicament homéopathique approprié, basé sur la totalité des symptômes, tandis que le patient a continué son régime régulier de médecine conventionnelle pour le diabète sucré et l'hypertension. Le remède indiqué a entraîné un soulagement immédiat des symptômes, notamment des douleurs thoraciques, ainsi qu'une nette amélioration des examens de laboratoire. Le score du critère modifié de Naranjo après traitement était de 8, ce qui montre explicitement l'attribution causale positive du médicament homéopathique individualisé, Phosphorus, dans ce cas. Le traitement homéopathique a donné des résultats favorables dans ce cas et démontre la portée de l'homéopathie dans les cas infectieux..

Homöopathische Behandlung eines diabetischen Covid-19-Patienten mit der Komplikation einer Bronchitis und eines Pleuraergusses: Ein Fallbericht

Einleitung: COVID-19 ist eine neuartige SARS-CoV-2-Erkrankung, die eine weltweite Pandemie ausgelöst hat. Sie ist hoch ansteckend und verursacht ein schweres akutes Atemwegssyndrom. Viele homöopathische Arzneimittel wurden für die Behandlung von Covid-Fällen vorgeschlagen, und es wurden auch Berichte veröffentlicht. **Zusammenfassung des Falls:** Der vorliegende Fallbericht handelt von einem 61-jährigen Covid-positiven Mann, der Komplikationen wie Bronchitis und Pleuraerguss aufwies. Er wurde auf der Grundlage der Gesamtheit der Symptome mit einem geeigneten homöopathischen Arzneimittel für COVID-19 behandelt, während der Patient seine reguläre Behandlung mit konventionellen Medikamenten gegen Diabetes mellitus und Bluthochdruck fortsetzte. Das indizierte Mittel führte zu einer sofortigen Linderung der Symptome, insbesondere der Brustschmerzen, sowie zu einer deutlichen Verbesserung der Laboruntersuchungen. Der modifizierte Naranjo-Kriterien-Score nach der Behandlung betrug 8, was die positive kausale Zuordnung des individualisierten homöopathischen Mittels Phosphorus in diesem Fall eindeutig belegt. Die homöopathische Behandlung hat in diesem Fall günstige Ergebnisse gezeigt und demonstriert den Anwendungsbereich der Homöopathie bei Infektionskrankheiten..

श्वसनीशोध (ब्रोंकाइटिस) और प्लूरल एम्फुजन की जटिलता के साथ एक मधुमेह कोविड-19 रोगी का होम्योपैथिक उपचार: एक विषय रिपोर्ट

परिचय: कोविड -19 एक नॉवल एसएआरएस-सीओवी-2 S बीमारी है जोकि दुनिया भर में महामारी का कारण बना है। यह अत्यधिक संक्रामक है और गंभीर तीव्र श्वसन सिंड्रोम पैदा करता है। कोविड मामलों के इलाज के लिए कई होम्योपैथिक दवाओं का सुझाव दिया गया है और भी प्रकाशित की गई हैं। **विषय सारांश:** वर्तमान केस रिपोर्ट एक 61 वर्षीय कोविड-पॉजिटिव पुरुष की है, जो श्वसनीशोध (ब्रोंकाइटिस) प्लूरल एम्फुजन जैसी जटिलताओं को प्रस्तुत करता है। लक्षणों की समग्रता के आधार पर, एक उपयुक्त होम्योपैथिक दवा के साथ उनका इलाज कोविड -19 के लिए किया गया, और रोगी ने मधुमेह और उच्च रक्तचाप के लिए पारंपरिक दवा का अपना नियमित उपचार जारी रखा। संकेतित उपाय से लक्षणों में तत्काल राहत मिली, विशेष रूप से सीने में दर्द के साथ-साथ प्रयोगशाला जांच में उल्लेखनीय सुधार हुआ। उपचार के बाद संशोधित नारंजो मानदंड स्कोर 8 था, जो इस मामले में व्यक्तिगत होम्योपैथिक दवा, फास्फोरस के सकारात्मक कारण को स्पष्ट रूप से दर्शाता है। होम्योपैथिक उपचार ने इस मामले में अनुकूल परिणाम दिखाए हैं जो संक्रामक मामलों में होम्योपैथी के दायरे को प्रदर्शित करता है।

Tratamiento homeopático de un paciente diabético Covid-19 con complicación de bronquitis y derrame pleural: Reporte de un caso

Introducción: COVID-19 es una nueva enfermedad del SRAS-CoV-2 que ha causado una pandemia mundial. Es altamente contagiosa y produce síndrome respiratorio agudo severo. Se han sugerido muchos medicamentos homeopáticos para el tratamiento de los casos covid y también se han publicado informes. **Resumen del caso:** El presente caso clínico es de un varón Covid positivo de 61 años, con complicaciones como bronquitis y derrame pleural. Fue tratado por COVID-19 con una medicina homeopática adecuada, basada en la totalidad de los síntomas, mientras que el paciente continuó su régimen regular de medicina convencional para la diabetes mellitus y la hipertensión. El remedio indicado condujo al alivio inmediato de los síntomas, especialmente el dolor torácico, junto con una notable mejoría en las investigaciones de laboratorio. La puntuación modificada de los criterios de Naranjo después del tratamiento fue de 8, lo que muestra explícitamente la atribución causal positiva de la medicina homeopática individualizada, el Fósforo, en este caso. El tratamiento homeopático ha mostrado resultados favorables en este caso y demuestra el alcance de la homeopatía en casos infecciosos.

糖尿病患者的同种疗法治疗科维德-19支气管炎和胸腔积液并发症的患者：一个案例报告

简介：科维德-19是一种新的萨尔斯-科维德 2 引起全球大流行的疾病。它具有高度传染性，并产生严重的急性呼吸道综合征。许多顺势疗法药物被建议用于治疗科维德病例，也有报告发表。案件摘要：本病例报告的是一位61岁的科维德-患有阳性的男性，出现了支气管炎和胸腔积液等并发症。他接受了以下治疗科维德-19根据全部症状，使用合适的同种疗法药物，同时病人继续服用治疗糖尿病和高血压的常规药物。指明的药方使症状立即得到缓解，特别是胸痛，同时实验室检查也有明显改善。治疗后的修正纳兰霍标准得分是8分，这明确显示了个体化的同位素药物-磷在本病例中的积极因果关系。顺势疗法在这个案例中显示了有利的结果，并证明了顺势疗法在感染性案例中的应用范围。