

Homoeopathic management of wrist ganglion: Case series

Arunava Nath^{1*}, Deb Kumar Palit²

Departments of ¹Forensic Medicine and Toxicology and ²Community Medicine, Pratap Chandra Memorial Homoeopathic Hospital and College, Kolkata, West Bengal, India

Abstract

Introduction: Ganglion cysts are soft tissue swellings occurring most commonly in the hand or wrist. Studies have reported 8%–50% of them resolve spontaneously in adults within 2 years approximately. **Cases Summary:** We present three cases of wrist ganglion treated successfully with individualized homoeopathic medicines; the results were evident within few weeks. Individual curative response of a homoeopathic medicine in each case was assessed through Modified Naranjo Criteria for Homoeopathy-Causal Attribution Inventory, which further elucidated role of constitutional treatment in homoeopathy.

Key words: Individualized homoeopathy, modified Naranjo criteria, Paget's test, transillumination test, wrist ganglion

INTRODUCTION

Ganglion cysts of the wrist and back of the hand have been described by Hippocrates^[1] more than two millennia ago. They are benign fluid-filled masses that can arise from joint capsules, tendon sheaths, and bursae.^[2] They occur on the dorsal side (70%), or volar side (20%) of wrist and tendon sheath of fingers, toes (6.6%).^[3,4] Some lesser common sites of ganglion cysts include intraneural origin located within the perineurium or epineurium,^[5-7] intraosseous or intratendinous^[8] over hip, usually associated with hip disorders.^[9] They are three times more prevalent in females than in males and occur mostly between the second and fourth decades of life.^[10] A history of trauma is elicited in at least 10% of cases and is considered a causative factor although the pathogenesis remains unclear.^[11] Most of the ganglion cysts are asymptomatic besides swelling. The indications for treatment include pain, stiffness, weakness, and cosmetic concern.^[12] Surgical excision remains the gold standard for the treatment of ganglion cysts^[13] with complication rate range of 0%–56%.^[2] The clinical presentation is usually adequate for diagnosis, and X-ray evaluation is rarely indicated (except in the case of “occult wrist ganglion” where magnetic resonance imaging is needed to make a diagnosis).^[14] In 2015, a systematic review by Head *et al.* reported a 76% and 58% reduction in the recurrence of ganglion cyst compared to aspiration in randomized controlled trials and cohort studies, respectively.^[15] A search on PubMed

database revealed electroacupuncture stimulation of ganglion cyst as a favorable alternative to conservative or surgical treatment though the mechanism was obscure.^[16] Patients want treatment modality that would be safe, minimally invasive, less time consuming, having low recurrence, and cost effective.^[17]

In §186 of *Organon of Medicine*, Dr. Samuel Hahnemann has advised the use of active dynamic aid for local maladies resulting from injuries.^[18] Banerjea SK has stated that sycosis produces incoordination everywhere, resulting in over-production, growth, and infiltration of tissues.^[19] According to Ghatak N, all kinds of tumors and tumors' growths are sycotic.^[20] Roberts HA has opined stiffness, soreness, lameness and slowness of recovery as the characteristics of sycotic manifestations. He has advocated sycotic patient to take meat sparingly, and it is better for him to use nuts, beans, or cheese more freely.^[21] Homoeopathic medicines such as *Benzoicum acidum* 3x ointment as an external adjunct along with the internal administration of the drug in high dilution are reported to be indicative in cases of ganglion.^[22,23] *Calcarea fluor* and *Ruta* 3x are indicated

***Address for correspondence:** Dr. Arunava Nath, 64A, Christopher Road, Taruvilla Apartment, 1st Floor, P.O. Gobinda Khatick Road, P.S. Topsia, Kolkata - 700 046, West Bengal, India.
E-mail: arunavanath585@gmail.com

Received: 15.04.2020; **Accepted:** 24.05.2021; **Published:** 29.06.2021.

Access this article online

Quick Response Code:



Website:
www.ijrh.org

DOI:
10.4103/ijrh.ijrh_29_20

This is an open access journal, and articles are distributed under the terms of the Creative Commons Attribution-NonCommercial-ShareAlike 4.0 License, which allows others to remix, tweak, and build upon the work non-commercially, as long as appropriate credit is given and the new creations are licensed under the identical terms.

For reprints contact: WKHLRPMedknow_reprints@wolterskluwer.com

How to cite this article: Nath A, Palit DK. Homoeopathic management of wrist ganglion: Case series. *Indian J Res Homoeopathy* 2021;15:137-46.

in ganglia or encysted tumors of the wrist. Clarke JH has recommended *Sulphur* for ganglion of the wrist given on general indications.^[23] Ray T described four cases of wrist ganglion treated with *Bacillinum* in different potencies with favorable results. Susceptibility, past history and family history of the cases were given importance for selection of the remedy. He further stated that ganglion was a symptom of tubercular diathesis from the blending of two miasms, namely psora and sycosis.^[24] Central Council for Research in Homoeopathy has initiated an efficacy trial (protocol published in 2019) of individualized homoeopathy (IH) in cases of wrist ganglion which is going on and outcomes yet to be published.^[25]

Here, we have presented three cases suffering from wrist ganglion treated with individualized homoeopathy IH and the results were evident within few weeks.

CASE REPORTS

Case 1

A 10-year-old girl visited the Out Patient Department (OPD) of Pratap Chandra Memorial Homoeopathic Hospital and College (PCMHH&C) on August 27, 2019, complaining of swelling on the dorsal aspect of left wrist for the past 2 months which was gradually increasing in size. The swelling was slightly painful which was aggravated on any motion of the hand. There was no history of trauma. She visited a surgeon who recommended surgical treatment. Her mother also informed that she was suffering from diminished appetite for the past 6 months.

Past history

In the past, she had suffered from malarial fever at the age of 6 years, took allopathic treatment and recovered. She also suffered from typhoid fever at the age of 7 years, took homoeopathic treatment and recovered.

Family history

Her father was hypertensive; mother suffered from hypothyroidism.

Mind symptoms

Patient desired for company and was averse to bathing.

Physical generals

Patient's appetite was poor, and thirst was moderate. The tongue was moist and thinly white coated. There were craving for sweets and desire for meat. There was strong aversion to milk and no significant intolerance of any food item. Stool was constipated, hard, passed at 2–3-days interval, with much difficulty. Urine was clear and occasionally offensive. Sweating was moderate but offensive, particularly in palms and soles. Sleep duration was 6–7 h daily, with dreams which she didn't remember. Thermally, she was very sensitive to cold temperature.

General survey

The patient was conscious, alert, and cooperative. Clinically,

mild pallor was observed; cyanosis, edema, jaundice, or clubbing not detected. She was thin built and her weight was 27 kg.

On examination

Soft cystic swelling was felt underneath the skin of dorsum of left wrist which was painful on pressure, not adhered to the skin. The dimension of the swelling was 9 mm (craniocaudal) × 8 mm (mediolateral). Paget's test and transillumination tests were positive.

Diagnosis

The diagnosis was made by history and physical examination [Figure 1a, pretreatment].

The symptoms considered for the analysis and evaluation of the case were as follows:

1. Patient desired for company
2. Had aversion to bathing
3. Appetite was poor
4. Desire for sweets
5. Aversion to milk
6. Constipated, passage of hard stool at 2–3-day interval
7. Sweating was offensive
8. Thermally, she was very chilly
9. Swelling on the dorsal aspect of left wrist

Repertorization and remedial analysis

Repertorium Homeopathicum Syntheticum (Edition 9.1) was consulted as the case presented with characteristic mind and physical symptoms. *Sulphur* (19/9), *Rhus toxicodendron* (16/9) *Phosphorus* (21/8), *Silicea terra* (17/8) and *Carbo vegetabilis* (15/8) were the medicines in the top gradation. *Sulphur* covered all the symptoms with highest gradation [Figure 2].

Remedy selection and administration

Sulphur 30c one medicated globule number 20 was dispensed in 10 ml of distilled water, the whole quantity to be taken once in early morning in empty stomach. This single dose was followed by Liquid placebo (LPL) once daily, early morning in empty stomach for 14 subsequent days.

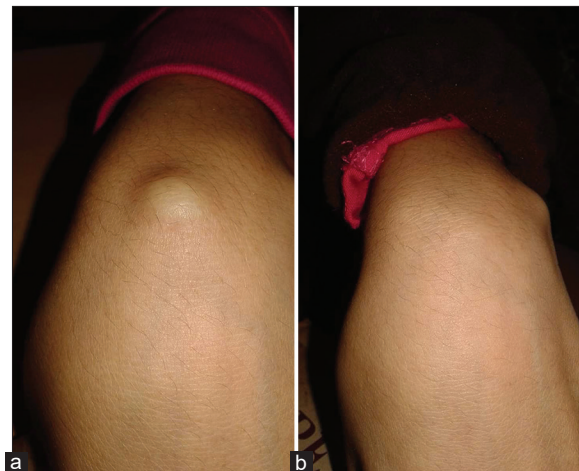

Figure 1: Case 1: Pretreatment (a), Posttreatment (b)

Figure 2: Case 1: Repertorization chart

Investigations advised

Complete blood count (CBC); stool for ova, parasites, and cyst to rule out any chronic inflammatory process and worm infestations.

She was also advised to maintain proper hygiene, have balanced and fiber-rich diet, and avoid excessive movements of the hand.

Follow-up and outcome

Follow-ups were done at 2-week intervals. Marked changes in symptomatology were elicited at the end of treatment [Figure 1b]. Although the cystic swelling became impalpable after 5 weeks, the treatment was continued for 3 months to address any recurrence of old complaints or any new complaints [Table 1]. The causal attribution was ascertained through modified Naranjo criteria. [Table 2].

Case 2

Another case of 21-year-old girl visited the OPD of PCMHH&C on May 07, 2019, and complained of swelling on the dorsal aspect of right wrist for the past 3 months which was gradually increasing in size. The swelling was asymptomatic in the beginning but later became painful on deep pressing. She did not report of any other ailment. She had taken homoeopathic medicines earlier for treatment of the swelling but could not provide the prescription.

Past history

She suffered from typhoid fever at the age of 17 years, took allopathic treatment and recovered. She also suffered from dengue fever at the age of 19 years, took homoeopathic treatment and recovered.

Family history

Her father was hypertensive; mother suffered from hypothyroidism.

Mind symptoms

Irritable, fear of dogs.

Physical generals

Her appetite was good and thirst was profuse. The tongue was moist and clean. There were desire for eggs and craving for sweets. No specific food intolerance or aversion was there. Stool was constipated, hard, passed at 2–3-day interval with much difficulty. Sweating was moderate and offensive, particularly in the head and neck. Sleep was

good, with dreams of falling from heights occasionally. Her menstrual cycle was regular, flow lasting for 4 days with no associated complaints. Thermally, she was very sensitive to cold temperature.

General survey

The patient was conscious, alert, and cooperative. Clinically, no pallor, cyanosis, edema, jaundice, or clubbing detected. Her weight was 54 kg. Blood pressure was 120/80 mmHg.

On examination

A soft cystic swelling underneath the skin of dorsum of right wrist was observed which was painful on deep pressure, not adhered to the skin. The dimension of the swelling was 14 mm (craniocaudal) ×9 mm (mediolateral). Paget’s test and transillumination tests were positive.

Diagnosis

The diagnosis was made by history and physical examination [Figure 3a, pretreatment].

The symptoms considered for the analysis and evaluation of the case were as follows:

1. Patient was irritable
2. She was fearful of dogs
3. Appetite was good
4. Thirst profuse
5. Desire for eggs and sweets
6. Constipated: hard stool at 2–3-day interval which passed with much difficulty
7. Sweating was offensive
8. Dreams of falling from heights
9. Thermally, she was very chilly
10. Swelling on the dorsal aspect of right wrist.

Repertorization and remedial analysis

Repertorium Homeopathicum Syntheticum (Edition 9.1) was consulted as the case presented with characteristic mind and physical symptoms. *Sulphur* (25/11), *Phosphorus* (23/11) *Calcarea carbonica* (21/10), *Silicea terra* (19/10) and *Belladonna* (17/10) were the medicines in the top gradation. *Sulphur* covered all the symptoms with highest gradation [Figure 4].

Remedial selection and administration

Sulphur 30c one medicated globule number 20 was dispensed in 10 ml distilled water, the whole quantity to be taken once

in early morning in empty stomach, followed by LPL once daily, early morning in empty stomach for 14 subsequent days.

Advice

She was also advised to maintain proper hygiene, have balanced and fiber-rich diet, and avoid excessive movements of the hand.

Follow-up and outcome

Follow-ups were done at 2-week intervals. Marked changes in symptomatology were elicited at the end of treatment [Figure 3b]. Although the cystic swelling became impalpable after 3 months, the treatment was continued for nearly 4½ months to address any recurrence of old complaints or any new complaints [Table 3]. The causal attribution was ascertained through modified Naranjo criteria. [Table 4].

Case 3

A 16-year-old boy visited the OPD of PCMH&C on March 26, 2019, complaining of swelling on the ventral aspect of left wrist for the past 1 month which was gradually increasing in size. The swelling was slightly painful, aggravated with any motion of the hand. He had not sought for any treatment before the present consultation.

Past history

The patient had suffered from malarial fever at the age of 10 years, took allopathic treatment and recovered. He also suffered from dengue fever at the age of 7 years, took homoeopathic treatment and recovered.

Family history

His father was diabetic. Mother suffered from some cardiac ailments.

Mind symptoms

Patient desired for company. He was fearful of dogs. There was dread of thunderstorm.

Physical generals

Appetite was average. The tongue was moist and clean. Thirst was moderate. There was craving for salt and desire for meat and fish. There was strong aversion to sweets and intolerance to sour. The patient complained of occasional mucoid stool. Urine was clear. Sweating was profuse and offensive, stained white. Sleep was good, with dreams which were not remembered. Thermally, he was very sensitive to cold temperature.

General survey

The patient was conscious, alert, and cooperative. He was thinly built. Clinically no anemia, cyanosis, edema, jaundice, or clubbing detected. His weight was 39 kg.

On examination

Soft cystic swelling was felt underneath the skin of ventral aspect of left wrist, which was painful on pressure, not adhered to the skin. The dimension of the swelling was 13 mm (craniocaudal) ×8 mm (mediolateral). Paget’s test and transillumination tests were positive.

Diagnosis

The diagnosis was made by history and physical examination [Figure 5a, pretreatment].

The symptoms considered for the analysis and evaluation of the case were as follows:

1. Patient desired for company
2. He was fearful of dogs
3. There was dread of thunderstorm
4. Desire for salt
5. Aversion to sweets
6. Intolerance to sour
7. Occasional mucoid stool
8. Sweating was profuse and offensive
9. Thermally, he was very chilly
10. Swelling on the ventral aspect of left wrist.

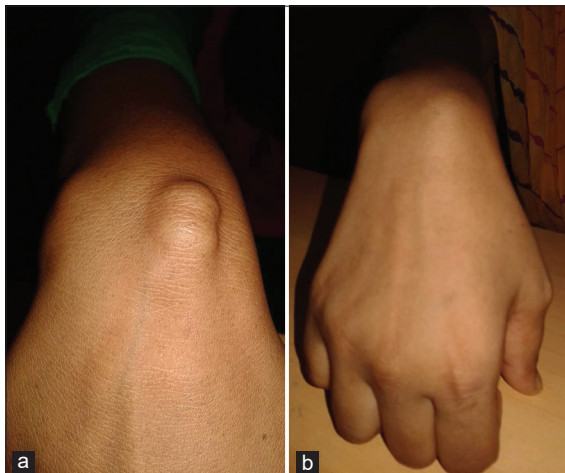


Figure 3: Case 2: Pretreatment (a). Posttreatment (b)




Figure 4: Case 2: Repertorization chart

Table 1: Follow-up, Case 1

Date of visit	Change in symptomatology	Treatment and management	Justification
27 August 2019	First case taking	<i>Sulphur</i> 30/ 1 dose	Repertorisation
10 September 2019	Sudden pain occurred in the swelling since last night without appreciable cause. Not much change in appetite. Tongue moist, clean. Thirst increased. Stool hard passed at 2-day interval. Urine clear and nonoffensive. Sweat offensive. Sleep sound. Biochemistry and pathology reports: HB% 11g/dl, Stool: No abnormality detected	LPL for 7 days once daily. Advised for iron-rich diet to overcome anemia	Initial aggravation of presenting complaints, the medicine was allowed to act
17 September 2019	Size of ganglion reduced by 50%. Pain over swelling present but intensity lesser than before. Appetite increased. Tongue moist, clean. Thirst increased. Stool consistency better but passed at 2-day interval. Urine clear and nonoffensive. Sweat offensive. Sleep sound. Weighed 28 kg	LPL for 14 days to be taken as directed	Complaints were better so advised for placebo
01 October 2019	No swelling visible. On deep palpation, no tenderness elicited. Appetite good. Tongue moist, clean. Thirst increased. Stool consistency better passed once daily. Urine clear and nonoffensive. Sweat offensiveness reduced. Sleep sound	LPL for 14 days once daily. Advised to maintain proper hygiene	Complaints were better so advised for placebo
22/10/2019	No swelling visible. Weighed 29 kg	LPL for 14 days once daily. Advice for CBC	No new complaints
05 November 2019	Overall better. Weighed 29.5 kg. Clinically paleness was reduced. HB% 12.5 g/dl	LPL for 14 days once daily	No new complaints. HB% improved
19 November 2019	Overall better. Weighed 30 kg	LPL for 14 days once daily	No new complaints
03 December 2019	Overall better. No new complaints. Weighed 30 kg	LPL for 14 days once daily. Advised to visit if there was any recurrence	Advice given to check for recurrence of old complaints or any new complaints

LPL: Liquid placebo, CBC: Complete blood count, HB: Hemoglobin

Table 2: Case 1, assessment of the case according to Modified Naranjo criteria for homeopathy inventory

Domains	Yes	No	Not sure or not available
Was there an improvement in the main symptom or condition for which the homeopathic medicine was prescribed?	+2		
Did the clinical improvement occur within a plausible timeframe relative to the drug intake?	+1		
Was there an initial aggravation of symptoms?	+1		
Did the effect encompass more than the main symptom or condition (i.e., were other symptoms ultimately improved or changed)?	+1		
Did overall well-being improve? (suggest using a validated scale or mention about changes in physical, emotional, and behavioral elements)	+1		
Direction of cure: Did some symptoms improve in the opposite order of the development of symptoms of the disease?		0	
Direction of cure: Did at least two of the following aspects apply to the order of improvement of symptoms From organs of more importance to those of less importance? From deeper to more superficial aspects of the individual? From the top downwards?	+1		
Did "old symptoms" (defined as nonseasonal and noncyclical symptoms that were previously thought to have resolved) reappear temporarily during the course of improvement?			0
Are there alternate causes (other than the medicine) that - with a high probability - could have caused the improvement? (consider known course of disease, other forms of treatment, and other clinically relevant interventions)		+1	
Was the health improvement confirmed by any objective evidence? (e.g., laboratory test, clinical observation, etc.)	+2		
Did repeat dosing, if conducted, create similar clinical improvement?			0
Total score			10

Repertorization and remedial analysis

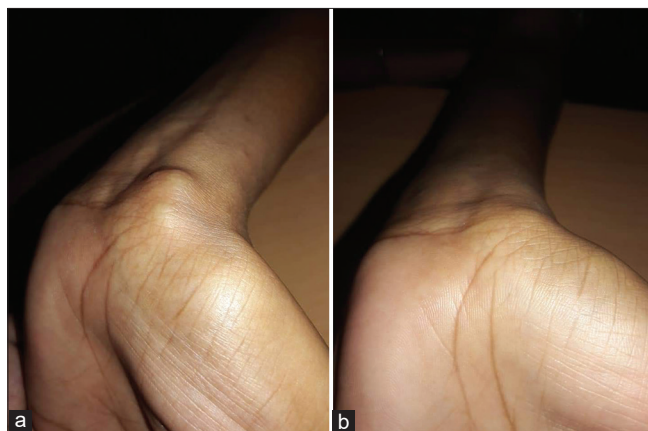
Repertorium Homeopathicum Syntheticum (Edition 9.1) was consulted as the case presented with characteristic mind and physical symptoms. *Phosphorus* (28/11), *Sulphur*

(19/11) *Calcarea carbonica* (17/10), *Causticum* (17/10) and *Silicea terra* (17/10) were the medicines in the top gradation. *Phosphorus* covered all the symptoms with highest gradation [Figure 6].

Table 3: Case 2, follow-up

Date of visit	Change in symptomatology	Treatment and management	Justification
07 May 2019	First case taking	<i>Sulphur</i> 30/ 1 dose	Repertorisation
28 May 2019	Sudden pain occurred in the swelling for the past 2 days. Appetite good. Tongue was moist and clean. Thirst was moderate. Passage of hard stool at 2-day interval. Urine clear. Sound sleep	LPL for 14 days	Initial aggravation of presenting complaints, the medicine was allowed to act
11 June 2019	Size of swelling remained the same. Appetite good. The tongue was moist and clean. Thirst was moderate. Passage of semisolid stool every alternate day. Urine clear. Sound sleep. She weighed 54 kg	LPL for 14 days	To wait and allow the medicine to act
25 June 2019	Swelling was reduced by 50%. No pain on deep palpation. Bowels clear	LPL for 14 days	No new complaints
09 July 2019	Swelling was reduced in size but remained the same as on previous visit. She weighed 54.5 kg	LPL for 14 days	No new complaints
23 July 2019	Swelling was reduced in size but remained the same as previous visit	<i>Sulphur</i> 30C one dose to be taken as directed LPL for 14 days	Condition came to a standstill. The same medicine was repeated
06 August 2019	Irritability reduced. No swelling seen. Sound sleep. Dreams of falling not yet seen. Overall better. Weighed 54.5 kg	LPL for 14 days	No new complaints
20 August 2019	No swelling seen. Overall better	LPL for 14 days	No new complaints
03 September 2019	No swelling seen. Overall better. Weighed 55kg	LPL for 14 days	No new complaints
24 September 2019	No swelling seen. No new complaints. Overall better	LPL for 14 days Advised to visit if there was any recurrence	Advice given to check for recurrence of old complaints or any new complaints

LPL: Liquid placebo

**Figure 5:** Case 3: Pretreatment (a). Posttreatment (b)

Remedial selection and administration

Phosphorus 30c one medicated globule number 20 was dispensed in 10 ml distilled water, the whole quantity to be taken in early morning in empty stomach for 1 day. LPL once daily, early morning in empty stomach for 14 subsequent days, was also given.

Advice

CBC, stool for routine and microscopical examination were advised to rule out any intestinal infections. Also advised to maintain proper hygiene, have balanced diet, and avoid excessive movement of the hand.

Follow-up and outcome

Follow-ups were done at 2-week intervals. Marked changes in symptomatology were elicited at the end of treatment

[Figure 5b]. Although the cystic swelling became impalpable after 2 months, the treatment was continued for more than 4 months to address any recurrence of old complaints or any new complaints [Table 5]. The causal attribution was ascertained through modified Naranjo criteria [Table 6].

Reporting of adverse events

The patients were advised to report any adverse or untoward medical events after the administration of IH during their treatment period. Chances of medicinal aggravation were averted by prescribing minimum doses in the three cases. Had there been still any unfavorable event(s), antidoting or change of plan of treatment could have been adopted as per suitability of the case(s). However, no of such adverse events were reported.

DISCUSSION

We have presented three case reports of ganglion over dorsal aspects of left and right wrist and over volar aspect of left wrist with encouraging outcomes. The cases were diagnosed based on history and physical examination. While prescribing we consulted homeopathic materia medica and keeping in view the dominating miasm in each case, the medicines were prescribed. As the post-treatment findings revealed reduction of the sizes of the swelling were reduced in all the three cases [Figures 1b, 3b and 5b, posttreatment findings]. The individual curative response of a homeopathic medicine was assessed through Modified Naranjo Criteria for Homoeopathy (MONARCH) Inventory.^[26] The total scores were 10 for all the 3 cases thus suggesting a “definite”

Table 4: Case 2, assessment of the case according to Modified Naranjo criteria for homeopathy inventory

Domains	Yes	No	Not sure or not available
Was there an improvement in the main symptom or condition for which the homeopathic medicine was prescribed?	+2		
Did the clinical improvement occur within a plausible timeframe relative to the drug intake?	+1		
Was there an initial aggravation of symptoms?	+1		
Did the effect encompass more than the main symptom or condition (i.e., were other symptoms ultimately improved or changed)?	+1		
Did overall well-being improve? (suggest using a validated scale or mention about changes in physical, emotional, and behavioral elements)	+1		
Direction of cure: Did some symptoms improve in the opposite order of the development of symptoms of the disease?		0	
Direction of cure: Did at least two of the following aspects apply to the order of improvement of symptoms	+1		
From organs of more importance to those of less importance?			
From deeper to more superficial aspects of the individual?			
From the top downwards?			
Did “old symptoms” (defined as nonseasonal and noncyclical symptoms that were previously thought to have resolved) reappear temporarily during the course of improvement?			0
Are there alternate causes (other than the medicine) that - with a high probability - could have caused the improvement? (consider known course of disease, other forms of treatment, and other clinically relevant interventions)		+1	
Was the health improvement confirmed by any objective evidence? (e.g., laboratory test, clinical observation, etc.)	+2		
Did repeat dosing, if conducted, create similar clinical improvement?			0
Total score			10




Figure 6: Case 3: Repertorization chart

association between the medicine and the outcome (definite ≥ 9 ; probable 5–8; possible 1–4; and doubtful ≤ 0) [Tables 2, 4 and 6]. Reporting of the cases adhered to the HOM-CASE-CARE guidelines.^[27]

Although history of trauma is considered to be one of the causative factors behind wrist ganglion, none of these three cases had such a history. Symptomatic cases are managed with either painful or surgical maneuvers in standard therapy, but we treated with IH with a positive clinical outcome in the most rapid and gentle manner.

We treated the three cases on the basis of totality of symptoms and susceptibility.^[28] Out of three cases, two cases were treated with *Sulphur* whose reference we find in homeopathic literature.^[23] The third case was treated with *Phosphorus* whose characteristic modalities in the treatment of wrist ganglion we were unable to find. Both the remedies are mainly antipsoric, but have antisycotic properties as evident from homeopathic literature.^[29-31] The presented cases had different sites of cystic manifestations and were treated based on homeopathic

principles. They were evidence based from pre and post-treatment physical findings. We waited for few more weeks and asked patients to report if there was recurrence of any old or new complaints. The patients in the cases presented were from the second and third decade of life as corroborated from age-wise distribution.^[32] The other comorbid conditions involving both the mental and physical planes such as irritability, appetite, thirst, and consistency of the stool were addressed with the same individualized medicines. At the end of the treatment, the patients reported to be better.

A case series reporting only of three cases is, however, though inadequate to infer definite efficacy of homeopathy in wrist ganglion, for which further controlled trials are warranted. The diagnosis and prognosis of the cases were done based on the clinical findings; and advanced imaging techniques were not used due to limited resources. In future, controlled trials can be implemented with methodological rigors and sound imaging techniques with adequate sample size, which will further validate our results. Further, studies may also include cases of ganglia located at

Table 5: Follow-up, Case 3

Date of visit	Change in symptomatology	Treatment and management	Justification
26 March 2019	First case taking	<i>Phosphorus</i> 30/ 1 dose	Repertorisation
09 April 2019	Sudden pain occurred in the swelling for the past 2 days. Size of ganglion reduced by 60%. Appetite good. The tongue was moist and clean. Thirst was moderate. Stool clear. Urine clear. Sound sleep. Sweat offensive. Biochemistry and pathology reports: HB% 12g/dl, Stool: No abnormality detected.	LPL for 14 days	Initial aggravation of presenting complaints, the medicine was allowed to act
23 April 2019	Size remained the same. No pain on deep palpation. Appetite good. The tongue was moist and clean. Thirst was moderate. Stool clear. Urine clear. Sound sleep. Sweat offensive. Weighed 39 kg	LPL for 14 days	To wait and allow the medicine to act
07 May 2019	Size remained the same. No pain on deep palpation. Appetite good. Tongue was moist and clean. Thirst was moderate. Stool clear. Urine clear. Sound sleep. Sweat offensive	<i>Phosphorus</i> 30c one dose to be taken as directed. LPL for 14 days	Condition came to a standstill. The same medicine was repeated
21 May 2019	No swelling seen. Appetite good. The tongue was moist and clean. Thirst was moderate. Stool clear. Urine clear. Sound sleep. Sweat nonoffensive. Weighed 39 kg	LPL for 14 days	No new complaints
04 June 2019	Overall better. Weighed 39.5 kg	LPL for 14 days	No new complaints
25 June 2019	Overall better. Weighed 40 kg	LPL for 14 days	No new complaints
09 July 2019	Overall better. Weighed 40 kg	LPL for 14 days	No new complaints
23 July 2019	Overall better. Weighed 40.5kg	LPL for 14 days	No new complaints
06 August 2019	Overall better. No new complaints	LPL for 14 days Advised to visit if there was any recurrence	Advice given to check for recurrence of old complaints or any new complaints

LPL: Liquid placebo, HB: Hemoglobin

Table 6: Case 3, assessment of the case according to Modified Naranjo criteria for homeopathy inventory

Domains	Yes	No	Not sure or not available
Was there an improvement in the main symptom or condition for which the homeopathic medicine was prescribed?	+2		
Did the clinical improvement occur within a plausible timeframe relative to the drug intake?	+1		
Was there an initial aggravation of symptoms?	+1		
Did the effect encompass more than the main symptom or condition (i.e., were other symptoms ultimately improved or changed)?	+1		
Did overall well-being improve? (suggest using a validated scale or mention about changes in physical, emotional, and behavioral elements)	+1		
Direction of cure: Did some symptoms improve in the opposite order of the development of symptoms of the disease?		0	
Direction of cure: Did at least two of the following aspects apply to the order of improvement of symptoms: From organs of more importance to those of less importance? From deeper to more superficial aspects of the individual? From the top downwards?	+1		
Did "old symptoms" (defined as nonseasonal and noncyclical symptoms that were previously thought to have resolved) reappear temporarily during the course of improvement?			0
Are there alternate causes (other than the medicine) that - with a high probability - could have caused the improvement? (consider known course of disease, other forms of treatment, and other clinically relevant interventions)		+1	
Was the health improvement confirmed by any objective evidence? (e.g., laboratory test, clinical observation, etc.)	+2		
Did repeat dosing, if conducted, create similar clinical improvement?			0
Total score		10	

different sites of the body, treated with individualized medicines. Even changes of the ganglion cystic swelling during treatment can be assessed from histopathological point of view.

CONCLUSION

The outcome of the treatment based on IH was favorable. We considered the physical nature of the swelling along with pain

as prognostic indicators. The size of the swelling and the pain manifestations reduced significantly with treatment. MONARCH inventory scores were 10 for all the 3 cases which suggested a "definite" causal attribution between the medicine and the outcome.

Declaration of patient consent

The authors certify that they have obtained appropriate patient consent form. Two of the patients were minor so

assents were given by them and consents were given by their respective guardians. In the form, the patients have expressed their willingness and agreed that their images and other clinical information to be reported in the journal. The patients have understood that their names and initials are not included in the manuscript and due efforts will be made to conceal their identity, but anonymity cannot be guaranteed.

Acknowledgment

The authors deeply acknowledge the institutional head of PCMHH&C for allowing us to collect data for the case reports. We gratefully acknowledge the active cooperation and participation made by the patients and the supporting staffs.

Financial support and sponsorship

Nil.

Conflicts of interest

None declared.

REFERENCES

1. Domenicucci M, Ramieri A, Marruzzo D, Missori P, Miscusi M, Tarantino R, *et al.* Lumbar ganglion cyst: Nosology, surgical management and proposal of a new classification based on 34 personal cases and literature review. *World J Orthop* 2017;8:697-704.
2. Angelides AC, Wallace PF. The dorsal ganglion of the wrist: Its pathogenesis, gross and microscopic anatomy, and surgical treatment. *J Hand Surg Am* 1976;1:228-35.
3. Westbrook AP, Stephen AB, Oni J, Davis TR. Ganglia: The patient's perception. *J Hand Surg Br* 2000;25:566-7.
4. Weishaupt D, Schweitzer ME, Morrison WB, Haims AH, Wapner K, Kahn M. MRI of the foot and ankle: Prevalence and distribution of occult and palpable ganglia. *J Magn Reson Imaging* 2001;14:464-71.
5. Spinner RJ, Carmichael SW, Atkinson JL. Intra-neural ganglion cyst. *J Neurosurg* 2006;104:990-2.
6. Swartz KR, Wilson D, Boland M, Fee DB. Proximal sciatic nerve intra-neural ganglion cyst. *Case Rep Med* 2009;2009:810973.
7. Colbert SH, Le MH. Case report: Intra-neural ganglion cyst of the ulnar nerve at the wrist. *Hand (N Y)* 2011;6:317-20.
8. Greendyke SD, Wilson M, Shepler TR. Anterior wrist ganglia from the scaphotrapezoidal joint. *J Hand Surg Am* 1992;17:487-90.
9. Burnett RA, Westermann R, Bedard N, Liu S, Callaghan JJ. Ganglion cyst as a rare complication of hip arthroscopy resolved with THA: A case report. *Iowa Orthop J* 2018;38:87-91.
10. Thornburg LE. Ganglions of the hand and wrist. *J Am Acad Orthop Surg* 1999;7:231-8.
11. Lowden CM, Attiah M, Garvin G, Macdermid JC, Osman S, Faber KJ. The prevalence of wrist ganglia in an asymptomatic population: Magnetic resonance evaluation. *J Hand Surg Br* 2005;30:302-6.
12. Head L, Allen M, Boyd KU. Long-term outcomes and patient satisfaction following wrist ganglion aspiration. *Plast Surg (Oakv)* 2015;23:51-3.
13. Osterman AL, Raphael J. Arthroscopic resection of dorsal ganglion of the wrist. *Hand Clin* 1995;11:7-12.
14. Gude W, Morelli V. Ganglion cysts of the wrist: Pathophysiology, clinical picture, and management. *Curr Rev Musculoskelet Med* 2008;1:205-11.
15. Head L, Gencarelli JR, Allen M, Boyd KU. Wrist ganglion treatment: Systematic review and meta-analysis. *J Hand Surg* 2015;40:546-53.
16. Tekeoğlu I, Doğan A. Electroacupuncture in the treatment of a ganglion of the wrist-A case report. *Acupunct Med* 2006;24:29-32.
17. Mohan SM, Mohan BK, Lal KH, Mohan SS. Management of wrist ganglia by transfixation technique: Our experience in a rural teaching institution. *J Evol Med Dent Sci* 2014;3:6781-9.
18. Singh M, Singh S. First Corrected, Re-Translated and Redacted Edition of Organon of Medicine with Word Meanings below Each Aphorisms 6th and 5th Editions by Samuel Hahnemann. 2nd ed. Kolkata: Homeopathic Publications; 2015.
19. Banerjee SK. Miasmatic Prescribing. New Delhi: B. Jain Publishers (P) Ltd.; 2010.
20. Ghatak N. Chronic Disease-Its Cause and Cure. Sasaram: World Homeopathic Links;1931.
21. Roberts HA. The Principles of Art and Cure by Homoeopathy-A Modern Textbook. 3rd ed. New Delhi: B Jain Publishers (P) Ltd.;2007.
22. Hughes R. The Principles and Practice of Homoeopathy. Reprint ed. New Delhi: B Jain Publishers (P) Ltd.; 2004.
23. Murphy R. Lotus Materia Medica. 3rd ed. New Delhi: B. Jain Publishers (P) Ltd.; 2010.
24. Ray T. A clinical symptom of Bacillinum. The Hahnemannian Gleanings 1985;52:321-2.
25. Central Council for Research in Homoeopathy. Protocol for efficacy of individualised homoeopathic medicine in cases of wrist ganglion: A prospective, parallel arm, randomised, double-blind, placebo-controlled trial. *Indian J Res Homoeopathy* 2019;13:118-24.
26. Lamba CD, Gupta VK, Haselen RV, Rutten L, Mahajan N, Molla AM, *et al.* Evaluation of the modified naranjo criteria for assessing causal attribution of clinical outcome to homeopathic intervention as presented in case reports. *Homeopathy* 2020;109:191-7.
27. van Haselen RA. Homeopathic clinical case reports: Development of a supplement (HOM-CASE) to the CARE clinical case reporting guideline. *Complement Ther Med* 2016;25:78-85.
28. Close S. The Genius of Homoeopathy. Reprint ed. New Delhi: Indian Books and Periodicals Publishers; 2001.
29. Dubey SK. Textbook of Materia Medica. Millennium ed. Calcutta: Books and Allied (P) Ltd.; 2000.
30. Kent JT. Repertory of the Homoeopathic Materia Medica. 4th ed. Calcutta: Economic Homoeo Pharmacy; 1982.
31. Schroyens F. SYNTHESIS Repertorium Homoeopathicum Syntheticum the Source Repertory. 9.1 ed. New Delhi: B. Jain Publishers (P) Ltd.; 2011.
32. Arora B. A loop suture technique in treatment of wrist and ankle ganglion. *Indian J Appl Res* 2016;6:441-3.

कलाई नाड़ीग्रंथि का होम्योपैथिक प्रबंधन – एक मामला श्रृंखला

प्रस्तावना: नाड़ीग्रंथि गाँठें मुलायम कोशिकायुक्त सूजन होती हैं जो सामान्यतौर पर हाथ या कलाई में हो जाती हैं। अध्ययनों ने प्रतिवेदित किया है कि वयस्कों में इनमें से 8–50 प्रतिशत लगभग 2 वर्षों के भीतर सहजता से खत्म हो जाती हैं। **मामलों का सारांश:** हम व्यक्तिपरक होम्योपैथिक दवाओं के माध्यम से कलाई नाड़ीग्रंथि के सफलतापूर्वक उपचारित तीन मामलों को पेश कर रहे हैं; परिणाम अगले कुछ हफ्तों में स्पष्ट हो गए थे। होम्योपैथी-हेतुक संबंध सामग्री के लिए संशोधित नरान्जो मानदंड के माध्यम से प्रत्येक मामले में होम्योपैथिक दवा की व्यक्तिगत उपचारात्मक प्रतिक्रिया का मूल्यांकन किया गया था, जिसने बाद में होम्योपैथी में वैधानिक उपचार की भूमिका को स्पष्ट किया था।

Prise en charge homéopathique du ganglion du poignet : une série de cas.

Introduction: Les kystes ganglionnaires sont des gonflements des tissus mous survenant le plus souvent au niveau de la main ou du poignet. Des études ont rapporté que 8 à 50 % d'entre eux se résolvent spontanément chez l'adulte en 2 ans environ. **Résumé des cas:** Nous présentons trois cas de ganglion du poignet traités avec succès avec des médicaments homéopathiques individualisés; les résultats étaient évidents en quelques semaines. La réponse curative individuelle d'un médicament homéopathique dans chaque cas a été évaluée par le biais des critères de Naranjo modifiés pour l'inventaire d'attribution causale de l'homéopathie, qui ont élucidé davantage le rôle du traitement constitutionnel dans l'homéopathie.

Manejo Homeopático Del Ganglio de La Muñeca: Una Serie De Casos

Introducción: Los quistes ganglionares son inflamaciones del tejido blando que ocurren más comúnmente en la mano o la muñeca. Los estudios han informado que entre el 8% y el 50% de ellos se resuelven espontáneamente en adultos en aproximadamente 2 años. **Resumen de casos:** Presentamos tres casos de ganglio de muñeca tratados con éxito con medicamentos homeopáticos individualizados; los resultados fueron evidentes en unas pocas semanas. La respuesta curativa individual de un medicamento homeopático en cada caso se evaluó mediante Criterios Naranjo Modificados para el Inventario de Atribución Homeopatía-Causal, que aclaraba aún más el papel del tratamiento constitucional en la Homeopatía, lo que aclaraba más el papel del tratamiento constitucional en la Homeopatía. que esclareció aún más el papel del tratamiento constitucional en la homeopatía.

Homöopathisches Management von Handgelenkganglion: Eine Fallserie

Einleitung/Einführung: Ganglienzysten sind Weichteilschwellungen, die am häufigsten in der Hand oder am Handgelenk auftreten. Studien haben berichtet, 8%-50% von ihnen lösen sich spontan bei Erwachsenen innerhalb von 2 Jahren auf. **Fallzusammenfassung CasesSummary:** Wir präsentieren drei Fälle von Handgelenkganglion, die erfolgreich mit individualisierten homöopathischen Arzneimitteln behandelt wurden; Die Ergebnisse waren innerhalb weniger Wochen offensichtlich. Die individuelle Heilreaktion eines homöopathischen Arzneimittels wurde jeweils anhand modifizierter Naranjo-Kriterien für das Homöopathie-kausale Attributionsinventar bewertet, die die Rolle der konstitutionellen Behandlung in der Homöopathie weiter erläuterten. **Einführung:** Ganglienzysten sind Weichteilschwellungen, die am häufigsten in der Hand oder am Handgelenk auftreten. Studien haben berichtet, 8%-50% von ihnen lösen sich spontan bei Erwachsenen innerhalb von 2 Jahren auf. **CasesSummary:** Wir präsentieren drei Fälle von Handgelenkganglion, die erfolgreich mit individualisierten homöopathischen Arzneimitteln behandelt wurden; die Ergebnisse waren innerhalb weniger Wochen offensichtlich. Die individuelle Heilreaktion eines homöopathischen Arzneimittels wurde jeweils anhand modifizierter Naranjo-Kriterien für das Homöopathie-kausale Attributionsinventar bewertet, die die Rolle der konstitutionellen Behandlung in der Homöopathie weiter erläuterten.

手腕神经节的顺势疗法：案例系列

导言：神经节囊肿是发生在手或手腕上的软组织肿胀。研究表明，大约2年内，8%-50%的婴儿在成人中自发分解。 **案例摘要：**现将个人化顺势疗法治疗成功的手腕神经节3例；几个星期之内，结果就显而易见了。通过《顺势疗法修正纳兰霍标准 — 因果归因目录》评估顺势疗法药物在每一病例中的个体疗效，进一步阐明顺势疗法中的立宪治疗作用。