

# Resolution of vocal cord nodules with individualised homoeopathic treatment

Suraia Parveen\*, Ranita Nath

Dr. Anjali Chatterjee Regional Research Institute (H), Kolkata, West Bengal, Central Council for Research in Homoeopathy, New Delhi, India

## Abstract

Vocal Cord Nodules (VCNs) are localised benign, superficial growths on the medial surface of the true vocal folds resulting primarily from voice abuse, overuse or misuse and clinically manifested by progressive hoarseness of voice, with increased effort required to produce the voice, vocal fatigue and discomfort or pain in the throat. Conventional treatment methods include conservative voice therapy and surgical intervention. Both treatment methods are required for the resolution of VCNs with improvement of clinical symptoms. Here, a 44-year-old male teacher presented with a history of progressive hoarseness with vocal fatigue, discomfort in the throat during talking and bilateral VCNs since 8 months. There was no improvement after voice rest and voice therapy interventions for 5 months and he was finally advised for surgery, which he denied. He was, instead, successfully treated by individualised homoeopathic single medicine *Hepar sulphuricum* (30C, 200C and 1M) selected on holistic approach. Over the period of 5 months of homoeopathic treatment, the patient's presenting symptoms of VCNs were improved and with resolution of it. This case report suggests that homoeopathic intervention may be the treatment for the resolution of VCNs with its presenting symptoms.

**Keywords:** *Hepar sulphuricum*, Hoarseness, Homoeopathy, Individualisation, Vocal cord nodules

## INTRODUCTION

Vocal cord nodules (VCNs) are benign, callous-like growths on the medial surface of the true vocal folds that commonly occur from vocal cords tissue trauma due to chronic vocal overuse or misuse. VCNs are usually bilateral and located at the midpoint of the membranous vocal fold and are characterised by hoarseness of voice, vocal fatigue, a sensation of discomfort or pain in the throat because of increased effort required to produce the voice and an unstable voice when speaking. Hoarseness is a common presenting symptom and refers to a rough, raspy, breathy, weak or strained voice or to changes in pitch and perceived effort.<sup>[1,2]</sup> This pathological growth of masses in vocal folds is generally caused by excessive and repeated mechanical stress. Vocal cords are subject to collision forces at each vibratory cycle. High-pitched vibration causes mechanical stress confined to the edge of the vocal folds, which is associated with a predisposition to nodule formation by activating subepithelial fibroblasts leading to excessive collagenous fibre deposition. Over the time, the vocal abuses generate firstly soft and swollen spots, which then evolve into nodules and become bigger and stiffer if the incorrect vocal use persists.<sup>[3]</sup>

Epidemiologic studies of the sociodemographic factors related to vocal nodules in the nationwide surveys are rare. Vocal nodules are common among the general population; with a lifetime prevalence reported at 2.29%–16.9%.<sup>[4]</sup> Most of the patients with voice complaints are known to have benign vocal fold lesions, with the most common pathology being vocal nodules. Hoarseness of voice is the predominant symptom followed by vocal fatigue.<sup>[5]</sup> The exact prevalence of vocal fold nodules is not known, but it has been reported that 23.4% of children who attended an ENT clinic for voice hoarseness, 6% of phoniatic clinic attendees and 43% of teachers with dysphonia had nodules. Vocal nodules have been associated with young age. The younger individuals have a greater possibility to overuse or abuse their voice, compared with that of the older age group.<sup>[2]</sup> The exact aetiology of vocal

**\*Address for correspondence:** Dr. Suraia Parveen,  
Dr. Anjali Chatterjee Regional Research Institute (H), 50, Rajendra Chatterjee  
Road, Kolkata - 700 035, West Bengal, India.  
E-mail: [drsuraia@gmail.com](mailto:drsuraia@gmail.com)

**Received:** 30.01.2019; **Accepted:** 16.09.2019

### Access this article online

Quick Response Code:



Website:  
[www.ijrh.org](http://www.ijrh.org)

DOI:  
10.4103/ijrh.ijrh\_5\_19

This is an open access journal, and articles are distributed under the terms of the Creative Commons Attribution-NonCommercial-ShareAlike 4.0 License, which allows others to remix, tweak, and build upon the work non-commercially, as long as appropriate credit is given and the new creations are licensed under the identical terms.

**For reprints contact:** [reprints@medknow.com](mailto:reprints@medknow.com)

**How to cite this article:** Parveen S, Nath R. Resolution of vocal cord nodules with individualised homoeopathic treatment. *Indian J Res Homoeopathy* 2019;13:184-91.

nodules is not known, but traditionally, the causative factors of VCN are reported to be laryngeal trauma due to long-term voice use, vocal abuse or misuse, long-term exposures to smoke or chemical and other medical conditions such as infection, allergy, gastroesophageal reflux, hypothyroidism, neuromuscular conditions, psychiatric conditions, systemic disorders, neoplasms or other vocal cord lesions. However, the majority of previous studies concerning vocal nodules have involved specific occupation (almost teachers and singers). A study conducted by Herrington *et al.* found that occupation such as teacher had more voice disorders as a result of voice overuse.<sup>[6]</sup> Significant occupational voice demands, such as teachers, are at the greatest risk for developing voice problems as well as vocal nodules or vocal polyps. Some reported that over 30%–38% of teachers quit their jobs or have trouble with teaching because of voice problems. The impact stress of phonation appears to be important both clinically and in laboratory models of VCNs. The diagnosis of VCNs based on history, presenting symptoms and endoscopic laryngeal examination (indirect laryngoscopy or fibre-optic endoscopy or microlaryngoscopy) which revealed bilateral vocal fold nodules.<sup>[7,8]</sup>

VCNs are treated either by non-surgical voice therapy interventions (e.g., voice retraining or voice therapy, voice rest or hygiene) or by surgical removal of nodules including excision with microsurgical instrument and the laser. Exacerbating factors, such as infection, allergy and reflux, may also be treated with pharmacological interventions. Voice therapy usually requires a prolonged period of treatment while surgery potentially removes the causative lesions restoring the anatomical configuration of the vocal folds. Although voice therapy is principally indicated for the treatment of functional dysphonia without any organic abnormality in the vocal folds, a number of clinicians have attempted to perform voice therapy even in dysphonic patients with benign mass lesions in the vocal folds. Voice therapy is usually chosen as a primary treatment of choice; there is no consensus as to which of the techniques employed by speech therapists are most effective or for how long they should be used. The techniques range from improving vocal hygiene, behaviour modification and ‘abuse’ reduction, to vocal retraining and psychological support, but it may be hampered voice-demanding profession like teaching or singing for time-consuming. Rates of surgical intervention vary widely, and the exact criteria for surgery are not clearly defined and it is also very costly. However, there are potential risks of surgery, and failures have been reported if the underlying causative factors are not addressed. For complete resolution of vocal nodules, both non-surgical speech therapy intervention and surgery are effective. It is not clear how patients should be selected.<sup>[9,10]</sup>

Literature review revealed a case report on homoeopathic treatment of vocal cord polyp with hoarseness of voice. This case was treated with indicated homoeopathic medicines *Arsenicum album* and showed a resolution of vocal cord polyp.<sup>[11,12]</sup>

A case of hoarseness of voice with bilateral VCNs, where voice therapy could not improve the presenting symptoms with failure to resolution of nodule, is presented here. Then, he was advised for surgical intervention by an ear, nose, and throat (ENT) surgeon but he rather chose to take homoeopathic medication.

## PATIENT INFORMATION

On 11 April 2018, a 44-year-old male presented to the Outpatient Department of Dr. Anjali Chatterjee Regional Research Institute for Homoeopathy (DACRRIH), Kolkata, with hoarseness of voice, vocal fatigue and discomfort or pain in the throat during speaking for the past 8 months. There was a history of vocal overuse which gradually preceded the onset. The hoarseness was accentuated in the morning and evening after overuse (teaching) of voice and in cold weather.

### History of present complaints

The patient had been suffering from hoarseness of voice for near about 8 months. Professionally, he was a tutor and used to teach for 8–10 hours (4–5 coaching classes) per day, resulting in overuse of voice, which, in turn, led to hoarseness of voice. After suffering from hoarseness of voice for 8 weeks, laryngoscopy was done on 15 October 2017 as advised by the ENT surgeon which revealed bilateral VCNs. The ENT surgeon suggested voice rest and voice therapy with voice hygiene and minimises their coaching classes. He took voice therapy intervention (voice rest, voice training and voice hygiene) and discontinued his coaching classes for 20 weeks. However, there was no improvement.

It was difficult for him to continue further voice rest with the voice therapy as this was hampering his occupation. Due to deprivation in his tuition/teaching profession, he became worried, anxious and frustrated and ultimately he restarted his coaching classes on a small scale. Then, he was advised surgical removal of VCNs by the ENT surgeon. To avoid surgery, he decided to take the homoeopathic treatment and came to the Outpatient Department at DACRRIH, Kolkata.

### Past history

There was a history of pneumonia at the age of 2 years which was cured by Allopathy medicines. There was a tendency to wards recurrent attacks of cold and cough.

### Family history

Paternal grandfather of the patient died due to heart stroke, and maternal uncle is a known case of bronchial asthma.

### Personal history

The patient is a private tutor and teaches literature to the students. He started his teaching profession in 2010 and is teaching for 8–10 hours/day.

The living environment of the patient is dry and airy. No other environmental factors except cold weather provokes his recurrent throat infection. There was no history of any addiction like smoking or alcohol and he was not on any ongoing allopathic medicine.

## HOMOEOPATHIC GENERALS

### Mental generals

The patient was worried and frustrated due to his illness. He is very sensitive and anxious about little matters. He is physically active and speaks hurriedly.

### Physical generals

The patient is fair complexioned but looked older than his age. He is chilly and cannot tolerate cold in general and prefers wrapping up his head. There was a history of recurrent attack of cold and cough from exposure to cold weather. He has a tendency to catch cold easily and delayed wound healing. He has satisfactory appetite and moderate thirst with craving for sour things<sup>++</sup> and meat<sup>+</sup>. He dislikes fatty, spicy food<sup>++</sup> with intolerance to bitter<sup>+</sup>, salty things<sup>+</sup>. His bowel habit is regular, clear and soft in consistency, and urine passes normally without any difficulty. There is profuse offensive perspiration all over the body but without any relief. He has a sound sleep pattern, 6–7 h/day.

### Particulars

The patient feels pain and discomfort in the throat or larynx during speaking. Hoarseness of voice is aggravated from overuse of voice from teaching and in the morning. He has to put extra effort to speak or to read. His cough aggravated due to exposure to cold wind or weather.

## ANALYSIS OF THE CASE AND REPERTORISATION

Proper case taking was done as per the direction of the Organon of Medicines and the Homoeopathic Philosophy. After analysis and evaluation of the symptoms of this case, the totality of symptom was constructed and the case was and repertorised with the help of ‘Homopath Classic M.D version-10 software’<sup>[13]</sup> using Kent’s repertory. The repertorial results are shown in Figure 1.

The following symptoms were considered for repertorisation:

- Feeling of anxiety from little matters
- Despair of recovery
- Hasty speech
- Chilly, cannot tolerate cold in general, patient feels better during wrapping up the head
- Tendency to take cold
- History of delayed wound healing
- Desire – Sour things<sup>++</sup>
- Aversion – Fat/rich food<sup>++</sup>
- Sweat – Profuse all the time without getting any relief and offensive in odour
- Hoarseness aggravated on overuse of voice and in the morning
- Pain and discomfort feeling in the throat/larynx during talking
- Cough aggravated on being cold and exposure to cold air.

Repertorisation		Hep	Ars	Phos	Sil	Rhust	Sep	Merc	Nux-v	Calc	Kali-c	Lach	Carb-v	Sulph	Bry	Con
<b>Totality Symptoms Covered</b>		37	27	27	25	24	22	22	22	21	21	21	20	20	19	18
[KT] [Mind]Anxiety:Trifles,about:		13	12	12	10	11	11	9	9	10	10	9	10	10	10	10
[KT] [Mind]Despair:Recovery:			2		2					1						2
[KT] [Mind]Speech:Hasty:			3		1		2		1	3	1				2	
[KT] [Stomach]Desires:Sour,acids,etc.:		3	1				2	3	1			3			1	
[KT] [Stomach]Aversion:Fats and rich food:		3	2	2		1	2			2	2	2	2	2	2	2
[KT] [Generalities]Heat:Vital,lack of:		2	2	1		1	2	2		1			2	2	2	
[KT] [Generalities]Cold:Tendency to take:		3	3	3	3	3	2	2	3	3	3	2	2	2	2	2
[KT] [Generalities]Uncovering agg:		3	1	2	3	2	3	3	3	2	3		2	2	3	2
[KT] [Generalities]Wounds:Heal,slow to:		3	3	2	3	3	1	2	3		3	2			2	2
[KT] [Perspiration]Profuse:Day and night without relief:		3		1	3	2	1	2		2	1	3	2	3		1
[KT] [Perspiration]Odour:Offensive:		3	2	2	3	2	3	3	3		1	2	2	3		1
[KT] [Larynx and Trachea]Voice:Hoarseness:		3	2	3	2	2	2	3	2	3	2	3	3	2	3	2
[KT] [Larynx and Trachea]Voice:Hoarseness:Overuse of the voice:				2		3										
[KT] [Larynx and Trachea]Pain:Larynx:Talking,while:		2		3									1	1	1	
[KT] [Cough]Cold:Becoming:On:		3	3	3	3	3			3	2	3	2	2	2	2	2
[KT] [Cough]Air:Cold:Agg:		3	3	3	2	2	2		3	2	2	2	2	1	1	2
Symptoms 1 to 16		Total Symptoms : 16					Remedies 1 to 15					Total Remedies : 278				

Figure 1: Repertorisation software chart

## DIAGNOSTIC ASSESSMENT

Diagnosis was made by presenting symptoms such as hoarseness of voice, pain with discomfort in the throat and voice fatigue during talking and confirmed by fibre-optic laryngoscopy (FOL) on 15 October 2017 and revealed bilateral, symmetrical VCNs in the medial part of vocal cord [Figure 2].

## THERAPEUTIC INTERVENTION WITH FOLLOW-UP AND OUTCOME

On the basis of totality, individualisation, repertorial analysis and consultation with Materia Medica, *Hepar sulphuricum* was selected as similimum. On the first visit (11 April 2018), *Hepar sulphuricum* 30C was prescribed with four doses for two consecutive days. Homoeopathic medicines were procured from Hahnemann Publishing Company Pvt. Ltd. (Good Manufacturing Practice certified ISO 9001:2008 unit) and was dispensed from DACRRIH dispensary. Clinical follow-up of the patient was assessed fortnightly or as per requirement for 5 months. During follow-ups, the change in potency and repetitions of doses were done as per guidelines of the homoeopathic philosophy.<sup>[14,15]</sup>

A detailed account of follow-up with prescription is shown in Table 1.

*Hepar sulphuricum* with raising potencies (30C, 200C and 1M) improved the presenting symptoms of VCNs, hoarseness of voice, voice fatigue and discomfort in the throat during talking with resolution of bilateral VCNs, which was confirmed by FOL on dated 24 September 2018 [Figure 3]. The other associated symptoms such as cough and tendency towards

cold were also improved. Finally, his voice returned to normal with improvement in his quality of life and continuation of his teaching.

The final outcome and possible causal attribution of the changes in this case were assessed using the 'modified Naranjo criteria' as proposed by the clinical data working group of the Homeopathic Pharmacopoeia of the United States.<sup>[16]</sup>

## DISCUSSION

VCNs are localised, benign, callous-like masses, present on both folds and located within the lamina propria and represent a pathological condition for which the growth of unnatural masses on vocal folds affects the patients. More specifically, progressive hoarseness is the presenting symptom of all types of VC lesions that impairs communication or reduces voice-related quality of life. A number of studies have considered the association between voice disorders and a specific occupation group, for example, teacher and student which correlate this case report.<sup>[7,17,18]</sup>

With regard to management of VCNs, smaller nodules were managed conservatively by voice therapy, but larger ones required surgery and also post-operative care voice therapy equally plays a vital role for better prognosis which was more cost-effective.<sup>[19]</sup> According to the current literature, a substantial proportion of vocal polyps certainly tend to shrink after voice therapy, but regarding vocal nodules, no studies have investigated the effectiveness of voice therapy using proper experimental methodology. Evidence at present are, therefore, still insufficient to support the use of voice therapy for the treatment of benign vocal fold lesions and require surgery.<sup>[20]</sup>

There is no doubt that vocal nodules are a difficult condition to study and treat because the aetiology is not fully understood. The study suggested that patients with VCNs who showed no improvement after 6 weeks of voice therapy either subjectively or objectively were subjected to surgery.<sup>[21,22]</sup> In this case report, the patient was in proper voice therapy by a speech therapist for near about 20 weeks, but there was no improvement in

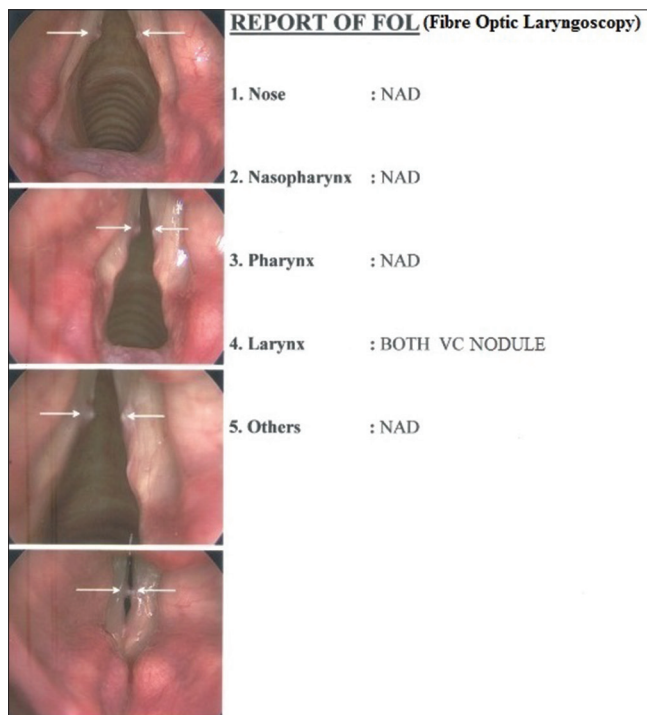


Figure 2: Before treatment: Both vocal cord nodules

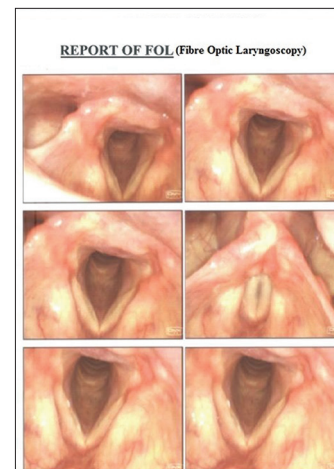


Figure 3: After treatment: Vocal cord nodules resolved

**Table 1: Timeline including follow-up of the case**

Date of visit	Symptoms/indications	Prescribed medicine with potency and doses
11 April 2018	Baseline symptoms (hoarseness, voice fatigue and discomfort in the throat, etc.)	<i>Hepar sulphuris</i> 30/4 doses (D)/BD
28 April 2018	No changes occur. All symptoms are stand still	<i>Hepar sulphuris</i> 30/OD/2 days
16 May 2018	Patients presents with acute attack of cough and cold, caused by exposure to cold air during travelling in train for 3 days back. Running nose is followed by cough with mucous expectoration < in the morning and evening. On chest auscultation - rales++and ronchi+ ; hoarseness and other symptoms are same	<i>Hepar sulphuris</i> 200/OD/2 days
30 May 2018	Cough was subsided. Discomfort in the throat with voice fatigue reduced. No changes in hoarseness of voice. Feels little better	Placebo
16 June 2018	Morning aggravation of hoarseness reduced but persists the same throughout the day. No further improvement in discomfort in the throat and voice fatigue	<i>Hepar sulphuris</i> 200/OD/2 days
30 June 2018	Hoarseness of voice- slightly better, voice fatigue with discomfort in the throat - also reduced. No further attack of cough	Placebo
16 July 2018	No further improvement in hoarseness of voice and other symptoms. Improvement is stand still. Cough for 2 days, mild but more in morning	<i>Hepar sulphuris</i> 1M/OD/2 days
30 July 2018	Hoarseness of voice - better than earlier. Voice fatigue and discomfort feeling are also better. All presenting symptoms are improving No attack of cough further	Placebo
17 Aug 2018	No further improvement of hoarseness of voice and more in the morning and evening after using of voice (after teaching two coaching classes). No discomfort during talking but voice fatigue persists	<i>Hepar sulphuris</i> 1M/OD/1 day
31 Aug 2018	Hoarseness of voice is improved. There is no aggravation in the morning and evening. No discomfort feeling in the throat during talking. Voice fatigue improved	Placebo
19 Sept 2018	The patient's voice returns to normal and other associated symptoms are also improved. Tendency of cold and cough also improved. The patient feels better as a whole He was advised for laryngoscopy to assess the pathological lesion, vocal fold nodules	No medicine
28 Sept 2018	Laryngoscopy [Figure 2] was done on 24 September 2018; revealed no vocal cord nodules, i.e. resolution of vocal cord nodules. Improved the presenting symptoms as well as pathological symptoms, i.e. resolution of vocal cord nodule The patient was advised to visit OPD if any recurrence of symptoms and advised to avoid overuse of voice	No medicine
23 Jan 2018	Normal voice. No recurrence of hoarseness and continues his profession (teaching) and ultimately improved his quality of life	After 4 months, by telephonic conversation, the current status of the patient

OPD: Outpatient department; BD: Twice daily; OD: Once daily

presenting symptoms of VCNs (hoarseness, voice fatigue and discomfort in the throat) and was advised for surgery.

Homoeopathy can take care of chronic problems in an individual, where surgery is otherwise advised. In previous study<sup>[23]</sup> and case studies,<sup>[24,25]</sup> homoeopathic treatment had shown positive results on surgical cases such as breast lesions and benign squamous laryngeal papillomatosis. In this case, the patient was treated with single Homoeopathic medicine *Hepar sulphuricum* in increasing potencies (i.e. 30C, 200C and 1M), over a period of 5 months, which brought about the improvement and final resolution of it. Moreover, there was no recurrence of symptoms of VCNs till date (near about 8 months).

*Hepar sulphuricum* not only presented as a 1<sup>st</sup>-grade medicine under the rubric 'hoarseness of voice' in Kent's and Synthesis repertory, but also, it has been selected on the basis of holistic approach and individualisation of general symptoms. *Hepar sulphuricum* with 30C and 200C potencies improved the presenting symptoms of VCNs to some extent, but *Hepar sulphuricum* 1M completed the cure, i.e., the patient gained his normal voice with resolution of VCNs confirmed by laryngoscopy [Figure 3] on 24 September 2018.

In this case, the total outcome score, as per the modified Naranjo criteria was +9, which was close to the maximum score 13 [Table 2]. This explicitly shows the positive causal attribution of the individualised homoeopathic treatment towards this case of bilateral VCNs with associated symptoms.<sup>[16]</sup>

A study conducted by Verdolini *et al.*, Nerriere *et al.* and Mattiske *et al.* found that voice disorders such as hoarseness of voice, vocal fatigue and discomfort or pain in the throat during speaking often arise in one's career as a teacher. This confirms that teaching is a profession with very high vocal demands. With proper individualised homoeopathic treatment, these problems can be solved.<sup>[26-28]</sup>

### Strengths and limitations in approach to the case

Homoeopathy can take care of chronic problems in an individual, where surgery is otherwise advised. The, homoeopathic approach towards the VCNs is holistic, rather than restricted to the pathological problem. Proper diagnosis, voice therapy and individualised homoeopathic treatment has proven to be useful in the management of patients with VCNs. Individualised homoeopathic treatment has a positive effect in the resolution of VCNs with its presenting symptoms and

**Table 2: Assessment of outcome with modified Naranjo algorithm**

Item	Yes	No	Not sure or N/A
Was there an improvement in the main symptom or condition for which the homoeopathic medicine was prescribed?	+2		
Did the clinical improvement occur within a plausible time frame relative to the drug intake?	+1		
Was there an initial aggravation of symptom? (need to define in glossary)			0
Did the effect encompass more than the main symptom or condition, i.e., were other symptoms ultimately improved or changed?	+1		
Did overall well-being improve? (suggest using validated scale)	+1		
Direction of cure: did some symptoms improve in the opposite order of the development of symptoms of the disease?			0
Direction of cure: Did at least two of the following aspects apply to the order of improvement of symptoms from organs of more importance to those of less importance from deeper to more superficial aspects of the individual from the top downwards			0
Did old symptoms (defined as non-seasonal and non-cyclical that were previously thought to have resolved) reappear temporarily during the course of improvement?		0	
Are there alternate causes (other than the medicine) that with a high probability could have caused the improvement? (consider known course of disease, other forms of treatment and other clinically relevant interventions)		+1	
Was the health improvement confirmed by any objective evidence? (e.g., lab test, clinical observation, etc.)	+2		
Did repeat dosing, if conducted, create similar clinical improvement?	+1		
Total score			9

N/A: Not available

also returns the voice to normal with improved quality of life. However, it is not possible to exclude the chances of recurrence of VCNs in future resulting from using the voice excessively.

### Future perspectives

This case illustrates the improvement of a chronic problem like VCNs with hoarseness of voice, vocal fatigue and discomfort or pain in the throat during speaking. Homoeopathy should be considered before a surgical intervention. Well-designed research studies are required for establishing the effectiveness of Homoeopathy in treating VCNs with associated symptoms. A comparative study can be carried out to assess whether treatment results vary with individualised medicines or with specific medicines for a clinical condition.

### Acknowledgements

The authors are grateful to Dr. D. B. Sarkar, Officer In-Charge, DACRRIH, Kolkata, for editing this case report and acknowledge the patient for his compliance in continued follow-ups.

### Declaration of patient consent

The authors declare that they have obtained all appropriate patient consent forms. In the form, the patient has given written consent for his images and other clinical information to be reported in the journal. The patient understands that his name will not be published and due efforts will be made to conceal his identity.

### Financial support and sponsorship

Nil.

### Conflicts of interest

None declared.

### REFERENCES

- Trottier AM, Massoud E, Brown T. A case of hoarseness and vocal cord immobility. *CMAJ* 2013;185:1520-4.
- Feierabend RH, Shahram MN. Hoarseness in adults. *Am Fam Physician* 2009;80:363-70.
- Zhukhovitskaya A, Battaglia D, Khosla SM, Murry T, Sulica L. Gender and age in benign vocal fold lesions. *Laryngoscope* 2015;125:191-6.
- Akif Kiliç M, Okur E, Yildirim I, Güzelsoy S. The prevalence of vocal fold nodules in school age children. *Int J Pediatr Otorhinolaryngol* 2004;68:409-12.
- Bastian RW. Benign vocal fold mucosal disorders. *Cummings Otolaryngol Head Neck Surg* 2005;4:2150.
- Herrington-Hall BL, Lee L, Stemple JC, Niemi KR, McHone MM. Description of laryngeal pathologies by age, sex, and occupation in a treatment-seeking sample. *J Speech Hear Disord* 1988;53:57-64.
- Smith E, Kirchner HL, Taylor M, Hoffman H, Lemke JH. Voice problems among teachers: Differences by gender and teaching characteristics. *J Voice* 1998;12:328-34.
- Won SJ, Kim RB, Kim JP, Park JJ, Kwon MS, Woo SH, *et al.* The prevalence and factors associate with vocal nodules in general population: Cross-sectional epidemiological study. *Medicine (Baltimore)* 2016;95:e4971.
- Pedersen M, McGlashan J. Surgical versus non-surgical interventions for vocal cord nodules. *Cochrane Database Syst Rev* 2012;6:CD001934.
- Nakagawa H, Miyamoto M, Kusuyama T, Mori Y, Fukuda H. Resolution of vocal fold polyps with conservative treatment. *J Voice* 2012;26:e107-10.
- Gupta G. Case of Vocal Cord Nodules; August, 2013. Available from: <https://homopath.com/blog/homeopathic-clinical-cases-a-case-of-vocal-cord-nodules/>. [Last accessed on 2019 Sep 10].
- Gnanasambandam R. Case report; vocal cord nodule escaped from surgery. *Homoeo Times* 2005;2:16-7.
- Shah J. *Homopath Classic M.D Repertory*. Ver. 1.0. Mumbai, India: Mind Technologies Pvt. Ltd.; 2002
- Boericke W. *Pocket Manual of Homoeopathic Materia Medica & Repertory*. 50<sup>th</sup> Impression. New Delhi: B. Jain Publisher (P) Ltd.; 2010. p. 325-8.
- Hahnemann S. *Organon of Medicine*. 6<sup>th</sup> ed. New Delhi: B. Jain Publishers (P) Ltd.; 2011.
- van Haselen RA. Homeopathic clinical case reports: Development of a supplement (HOM-CASE) to the CARE clinical case reporting guideline. *Complement Ther Med* 2016;25:78-85.
- Sapir S, Keidar A, Mathers-Schmidt B. Vocal attrition in teachers: Survey findings. *Eur J Disord Commun* 1993;28:177-85.
- Schwartz SR, Cohen SM, Dailey SH, Rosenfeld RM, Deutsch ES, Gillespie MB, *et al.* Clinical practice guideline: Hoarseness (dysphonia). *Otolaryngol Head Neck Surg* 2009;141:S1-31.

19. Siddapur Geetha K, Siddapur Kishan R. Comparative study of benign vocal fold lesions in a tertiary health centre. *Int J Otorhinolaryngol Head Neck Surg* 2015;1:65-8. Available from: <https://www.ijorl.com/index.php/ijorl/article/view/70>. [Last accessed on 2019 Sep 20].
20. Ogawa M, Inohara H. Is voice therapy effective for the treatment of dysphonic patients with benign vocal fold lesions? *Auris Nasus Larynx* 2018;45:661-6.
21. Bakat B, Gupta A, Roy A, Roychoudhury A, Raychoudhury BK. Does voice therapy cure all vocal fold nodules. *Int J Phonosurg Laryngol* 2014;4:55-9. [DOI: 10.5005/jp-journals-10023-1083].
22. McCrory E. Voice therapy outcomes in vocal fold nodules: A retrospective audit. *Int J Lang Commun Disord* 2001;36 (Suppl):19\_24.
23. Gupta G, Naveen G, Madhu C. Fibroadenoma of breast: A sonomammographical supported clinical study on the effect of homoeopathic drugs. *Homoeopathy* 2013;4:37-45.
24. Parveen S. Individualized homoeopathic treatment of breast fibroadenoma: A case report. *Indian J Res Homoeopath* 2018;12:46-52.
25. Nanda SK, Galagali JR, Guruprasad V. Thuja-in management of laryngeal papillomatosis. *Med J Armed Forces India* 2000;56:87.
26. Verdolini K, Ramig LO. Review: Occupational risks for voice problems. *Logoped Phoniatr Vocol* 2001;26:37-46.
27. Nerrière E, Vercambre MN, Gilbert F, Kovess-Masféty V. Voice disorders and mental health in teachers: A cross-sectional nationwide study. *BMC Public Health* 2009;9:370.
28. Mattiske JA, Oates JM, Greenwood KM. Vocal problems among teachers: A review of prevalence, causes, prevention, and treatment. *J Voice* 1998;12:489-99.

### वैयक्तिकृत होम्योपैथी उपचार के साथ वोकल कॉर्ड नोड्यूलस का समाधान – एक केस रिपोर्ट

वोकल कॉर्ड नोड्यूलस (वीवीएन) स्थानीय सुसाध्य गांठ है, वास्तविक आवाज ग्रंथि सिलवटों की बीच की सतह पर उपस्थित वृद्धि मुख्य रूप से आवाज के दुरुपयोग से होती है और चिकित्सकीय रूप से आवाज की कर्कशता से प्रकट होती है। आवाज पैदा करने के लिए आवश्यक प्रयास में वृद्धि के साथ गले और मुखर थकान में असुविधा या दर्द पारंपरिक उपचार विधियों में अपरिवर्तनवादी आवाज चिकित्सा और शल्य चिकित्सा संबंधी व्यवधान शामिल हैं। नैदानिक लक्षणों में सुधार के साथ वोकल कॉर्ड नोड्यूलस के समाधान के लिए दोनों आवश्यक हैं। यहां एक 34 वर्षीय पुरुष शिक्षक ने आवाज की थकान के साथ गला बैठने का वृत्तांत, बात करने के दौरान गले में तकलीफ और आठ महीनों से आवाज ग्रंथि के दोनों और गांठों के साथ प्रस्तुत किया। पांच महीनों तक आवाज को आराम देने के बाद और आवाज चिकित्सा लेने के बाद कोई सुधार नहीं हुआ और अंत में शल्य चिकित्सा के लिए सलाह दी गई, जिसे उन्होंने अस्वीकार कर दिया। इसके बजाय, व्यक्तिगत रूप से होम्योपैथिक एकल चिकित्सा हेपर सल्फ्यूरिस (30, 200 1एम) को सफलतापूर्वक इसके समग्र दृष्टिकोण पर चयन किया गया। होम्योपैथी उपचार के पांच महीनों की अवधि में रोगी में लक्षणान्मक रूप से सुधार हुआ था और मुखर कॉर्ड नोड्यूलस की स्थिरता के साथ और शिक्षण पेशे को जारी रखते हुए अपनी सामान्य आवाज में वापस आ गया। यह केस रिपोर्ट बताती है कि होम्योपैथिक व्यवधान मुखर कॉर्ड नोड्यूलस के समाधान के लिए उपचार हो सकता है।

### Traitement des nodules sur les cordes vocales grâce à un traitement homéopathique individualisé – Une étude de cas

Les nodules sur les cordes vocales (NCV) sont des excroissances bénignes, superficielles et localisées qui sont situées sur la surface médiale des cordes vocales, résultant principalement d'un usage abusif, excessif ou mauvais de la voix et se manifestant cliniquement par un enrouement de la voix, avec un effort accru requis pour produire la voix, une gêne ou une douleur dans la gorge et de la fatigue vocale. Les méthodes de traitement conventionnelles comprennent la thérapie vocale traditionnelle et l'intervention chirurgicale. Les deux sont nécessaires au traitement des nodules sur les cordes vocales et permettent l'amélioration des symptômes cliniques. Dans le cas que nous souhaitons évoquer, un enseignant de 34 ans a présenté pendant huit mois des antécédents d'enrouement accompagné de fatigue vocale, de gêne dans la gorge lorsqu'il parlait et de nodule bilatéral sur les cordes vocales. Aucune amélioration ne s'étant produite après le repos de la voix et de la thérapie vocale pendant cinq mois, on lui a finalement recommandé une intervention chirurgicale, ce qu'il a refusé. Au lieu de cela, il a été traité avec succès par un seul médicament homéopathique personnalisé, l'Hepar sulphuris (30 200 1M), choisi pour son approche holistique. Au cours des cinq mois de traitement homéopathique, le patient a vu une amélioration sur le plan symptomatique et l'élimination des nodules sur les cordes vocales ce qui lui a permis de retrouver sa voix normale et de continuer à enseigner. Cette étude de cas suggère que l'homéopathie peut être le traitement pour des nodules sur les cordes vocales.

### **Resolución de nódulos en cuerdas vocales con un tratamiento homeopático individualizado. Informe de caso clínico**

Los nódulos de cuerdas vocales (NCV) son crecimientos benignos superficiales en la superficie medial de los pliegues vocales verdaderos que se deben al maluso o sobreuso (abuso) de la voz y que se manifiestan clínicamente por disfonía con un aumento del esfuerzo para generar la voz, malestar y dolor de garganta y fatiga vocal. Los métodos de tratamiento convencional incluyen terapias vocales conservadoras e intervenciones quirúrgicas. Se requieren ambos tipos de tratamiento para resolver los nódulos de cuerdas vocales y mejorar los síntomas clínicos. En este artículo, se presenta un maestro de 34 años de edad con antecedentes de disfonía con fatiga vocal, molestias de garganta al hablar y un nódulo bilateral de cuerda vocal durante ocho meses. No se obtuvieron mejorías con un reposo de la voz o con intervenciones de terapia vocal durante cinco meses, por lo que finalmente se la indicó someterse a un tratamiento quirúrgico, el cual fue rechazado por el paciente. En cambio, recurrió a un tratamiento homeopático individualizado con *Hepar sulphuris* (30, 200 1M), seleccionado a partir de un concepto holístico. Tras un periodo de cinco meses de tratamiento homeopático, mejoraron los síntomas del paciente con la resolución de los nódulos de cuerdas vocales y la recuperación de la voz normal hasta el punto de poder seguir con sus actividades de enseñanza. Este informe de caso clínico indica que la intervención homeopática puede ser un tratamiento para la resolución de los nódulos de cuerda vocal.

### **Auflösung von Stimmbandknoten mit individualisierter homöopathischer Behandlung - Ein Fallbericht**

Stimmbandknoten (VCN) sind lokalisierte, gutartige, oberflächliche Wucherungen auf der medialen Oberfläche der wahren Stimmlippen, die hauptsächlich auf Stimmissbrauch, Überbeanspruchung oder Missbrauch zurückzuführen sind und sich klinisch durch Heiserkeit der Stimme manifestieren, wobei ein erhöhter Aufwand erforderlich ist, um die Stimme, das Unbehagen oder den Klang zu erzeugen Schmerzen im Hals und Müdigkeit der Stimme Zu den herkömmlichen Behandlungsmethoden gehören eine konservative Sprachtherapie und chirurgische Eingriffe. Beide sind für die Auflösung von Stimmbandknoten mit Verbesserung der klinischen Symptome erforderlich. Hier präsentierte ein 34-jähriger männlicher Lehrer acht Monate lang die Geschichte der Heiserkeit mit Stimmermüdung, Beschwerden im Hals während des Sprechens und bilateralem Stimmbandknoten. Nach fünfmonatigen Stimmruhe- und Sprachtherapie-Eingriffen zeigte sich keine Besserung und schließlich wurde eine Operation empfohlen, die er ablehnte. Stattdessen wurde er erfolgreich mit dem individualisierten homöopathischen Einzelarzneimittel *Hepar sulphuris* (30, 200 1M) behandelt, das nach seinem ganzheitlichen Ansatz ausgewählt wurde. Während der fünfmonatigen homöopathischen Behandlung besserte sich der Patient symptomatisch und mit Auflösung der Stimmbandknoten und kehrte mit fortgesetzter Lehrtätigkeit zu seiner normalen Stimme zurück. Dieser Fallbericht legt nahe, dass eine homöopathische Intervention die Behandlung für die Auflösung von Stimmbandknoten sein könnte.

### **利用個人化順勢療法治療聲帶結節的消退 - 病例報告**

聲帶結節 (VCN) 是由聲音濫用、過度使用或誤用引起的真性聲帶內表面的局部良性淺表性生長，臨床表現為聲音嘶啞，增加了產生聲音所需的力度、喉嚨不適或疼痛。傳統的治療方法包括保守的言語治療和外科手術。這兩種方法都需要通過改善臨床症狀來解決聲帶結節。有一位34歲的男教師有聲音嘶啞的病史，聲音疲勞，說話時喉嚨不適，雙側聲帶結節長達8個月。經過5個月的聲帶休息和言語治療介入後，沒有任何改善，最後建議進行手術，但他拒絕接受手術。相反，他成功地接受了個人化順勢療法治療，並服用單一的順勢療法藥物---硫肝（30C、200C、1M）。經過5個月的順勢療法治療，患者症狀有所改善，聲帶結節消退，能夠繼續從事教學工作，恢復正常聲音。本病例報告建議順勢療法的介入治療，可能是聲帶結節消退的治療方法。