

Evidence-based Homoeopathy: A case of corneal abscess

Sandeep Sudhakar Sathye*

Department of Homoeopathy, Sathye Eye Research Institute for Alternative Medicines, Pune, Maharashtra, India

Abstract

Corneal abscess is a circumscribed collection of pus within the layers of cornea. It is usually endogenous in origin and commonly found near the limbal blood vessels close to corneal margin. Treatment in modern medicine is use of local and systemic antibiotics. Homoeopathy has mentioned medicines for corneal abscess. A case reported was a female of 68 years of age suffering from symptoms of redness, dull pain, and foreign body sensation in the right eye and was diagnosed as corneal abscess. The homoeopathic medicine *Hepar sulphuris* 200C was prescribed on the basis of pathology. Abscess was reduced considerably within 5 days and it was absorbed completely in 21 days. No recurrence of abscess was observed thereafter. Ocular photographs during follow-up visits have provided documentary evidence about the effectiveness of homoeopathic *Hepar sulphuris* 200C in corneal abscess.

Key words: Case report, Corneal abscess, Hepar sulphuris, Homoeopathy

INTRODUCTION

Corneal abscess means a circumscribed collection of pus within the layers of the cornea.^[1] It is usually endogenous in origin and commonly found near the limbal blood vessels close to corneal margin. It is a form of marginal keratitis that occurs due to tuberculosis, syphilis, measles, or immunologically-mediated diseases that includes phlyctenular keratitis, acne rosacea, meibomitis, and blepharitis.^[2] Corneal abscess usually extends to the outer surface to discharge the pus, and an ulcer is formed or it may extend in both directions at the same time resulting in perforation of the cornea.^[1] Treatment in modern medicine is use of local and systemic antibiotics.

Some patients may have an allergic reaction or a drug resistance to local or systemic antibiotics. Almost every type of bacteria has become stronger and less responsive to antibiotic treatment when it is really needed.^[3] Homoeopathy has been treating infectious diseases successfully without giving any recurrence since preantibiotics era. In homoeopathy, different medicines were mentioned for corneal abscess, but there was a lack of published case study or a research work with documentary evidence about corneal abscess being treated with homoeopathy.

A case report presented with ocular photographs during follow-up visits has provided documentary evidence about

the effectiveness of homoeopathic treatment in corneal abscess.

CASE REPORT

History

A female aged 68 years presented on February 17, 2013, to the outpatient department of institute with the complaints of redness of the right eye for 10 days and mild pain, mild foreign body sensation with glaring of light throughout the day for 5 days. She had no history of ocular injury, no dental or ear-nose-throat complaints or complaints of any general disease.

Examination

On eye examination, patient's distance vision was normal (6/6 on Snellen's chart) with her own glasses. There was no conjunctival discharge or any abnormality of eyelids. On lifting the upper lid, there was a congestion restricted to the upper quadrant of the cornea and the presence of a corneal

*Address for correspondence: Dr. Sandeep Sudhakar Sathye, Plot No. 4, Sadanand Nagar, Anand Nagar, Hingne (Khurd), Sinhagad Road, Pune - 411 051, Maharashtra, India. E-mail: sandeepsathye@gmail.com

Access this article online

Quick Response Code:



Website:
www.ijrh.org

DOI:
10.4103/0974-7168.188242

This is an open access article distributed under the terms of the Creative Commons Attribution-NonCommercial-ShareAlike 3.0 License, which allows others to remix, tweak, and build upon the work non-commercially, as long as the author is credited and the new creations are licensed under the identical terms.

For reprints contact: reprints@medknow.com

How to cite this article: Sathye SS. Evidence-based Homoeopathy: A case of corneal abscess. *Indian J Res Homoeopathy* 2016;10:206-10.

abscess which was white and extending from 11 to 12 o'clock position [Figure 1].

Intervention

Homoeopathic medicine *Hepar sulphuris* in 200C potency was prescribed every 2 hourly for 2 days on the basis of pathology.

Follow-up and Outcomes

On February 18, 2013, there was a reduction of pain and foreign body sensation in the eye. On eye examination, vision was normal with glasses, and there was a reduction in area of corneal abscess, so the medicine was continued with the same dose for 2 days.

On February 21, 2013, there was only occasional foreign body sensation while glaring of light has reduced. On eye examination, vision was not affected and there was a considerable reduction in area and density of corneal abscess as well as ocular congestion [Figure 2]. The same medicine was continued four times a day.

On February 25, 2013, there was no foreign body sensation and glaring of light in the eye. On eye examination, there was no congestion and abscess has further reduced [Figure 3]. The same medicine was continued twice a day.

On March 2, 2013, the patient had no symptoms and abscess was in a resolving stage [Figure 4]. Hence, the medicine was continued further for 7 days.

On March 9, 2013, there were no ocular symptoms and corneal abscess was absorbed completely, so the medicine was discontinued [Figure 5].

On March 30, 2013, the eye was normal and there was no recurrence of abscess [Figure 6].

The patient was contacted through phone after 1 month, and she had no ocular complaints. Patient was examined in June 2015, there were no ocular complaints and the eye was normal on examination [Table 1]. The patient was contacted through phone in January 2016 and had no ocular complaints thereafter.

DISCUSSION

A systemic use of homoeopathic *Hepar sulphuris* 200C has achieved a considerable reduction in corneal abscess within 5 days and its resolution in 21 days.

Abscess was restricted to the upper quadrant of cornea below the lid and there was no history of ocular injury or any associated ocular disease, so cause of abscess might be due to some systemic low-grade infection rather than of exogenous origin.

Hepar sulphuris has probably acted on endogenous infection apart from its action on corneal abscess as there was no recurrence thereafter. In this case, abscess being restricted to the stromal layers of cornea, a systemic route of treatment was preferred instead of giving local treatment.

Homoeopathic medicines mentioned for corneal abscess in the literature were as follows with their gradation:

- Cornea – abscess of: Calc-s., *Hep.*, Kali-s., Merc-c., Sil., Sulph^[4]
- Corneal abscess: *Calc. hy.*, Fe. ph., *HEP.*, Merc., *Rhus.*, Sil., Sulph^[5]
- Cornea - abscess: Calc. hypo., *Hepar.*, Merc. cor., Sil., Sulph.^[1]

However, these medicines are indicated for corneal abscess in general that includes infection of exogenous or endogenous origin or infection from neighboring ocular tissue. Out of above medicines, *Hepar sulphuris* seems to have more similarity to this case as it has a specific affinity for cornea in general^[6] and corneal abscess in particular. Tendency for suppuration is a strong-guiding symptom of *Hepar sulphuris* as mentioned in books. *Hepar sulphuris* is indicated for infected corneal ulcer which is exogenous in origin and for parenchymatous keratitis and suppurative choroiditis that are usually endogenous in origin.^[4] Hence, *Hepar sulphuris* covers corneal infection of both endogenous and exogenous origins. Norton AB has specifically mentioned in his book that “*Hepar sulphuris* is one of the most frequently indicated remedies for ulcers and

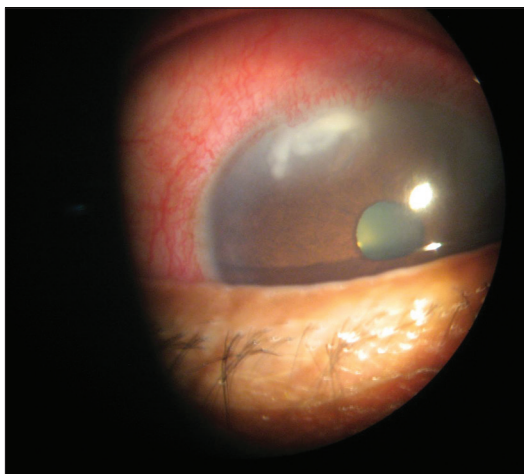

Figure 1: Corneal abscess in the right eye before treatment (dated February 17, 2013)

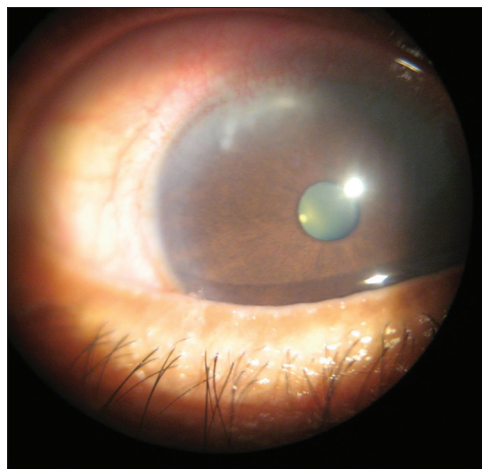


Figure 2: Corneal abscess during treatment (dated February 21, 2013)

Table 1: Timeline of patient response and medicine prescribed with its dose		
Date	Response	Prescription
Baseline visit	Redness, mild pain, foreign body sensation, and glaring of light - right eye	<i>Hepar sulphuris</i> 200C, every 2 hourly ×2 days
February 17, 2013	Ocular congestion and corneal abscess in the upper quadrant of cornea	
February 18, 2013	Reduction - pain and foreign body sensation Corneal abscess - area reduced	<i>Hepar sulphuris</i> 200C, every 2 hourly ×2 days
February 21, 2013	Occasional foreign body sensation and reduction of glaring of light Ocular congestion - reduced Corneal abscess - area and density reduced	<i>Hepar sulphuris</i> 200C, QID ×4 days
February 25, 2013	No pain, foreign body sensation, and glaring of light No ocular congestion. Corneal abscess - reduced	<i>Hepar sulphuris</i> 200C, BD×4 days
March 2, 2013	No ocular symptoms Corneal abscess - resolving stage	<i>Hepar sulphuris</i> 200C, BD×7 days
March 9, 2013	No ocular complaints Corneal abscess - resolved completely	Medicine discontinued
March 30, 2013	No recurrence	-
June 6, 2015	No recurrence	-

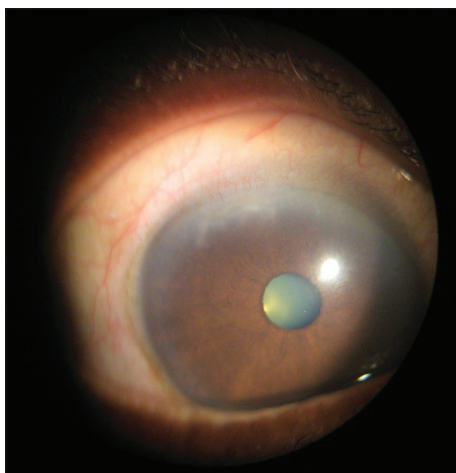


Figure 3: Corneal abscess during treatment (dated February 25, 2013)

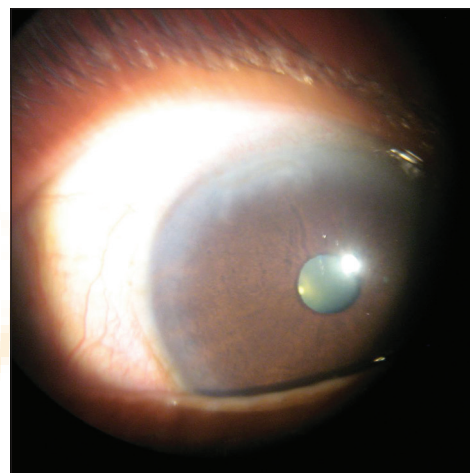


Figure 4: Corneal abscess during treatment (dated March 2, 2013)

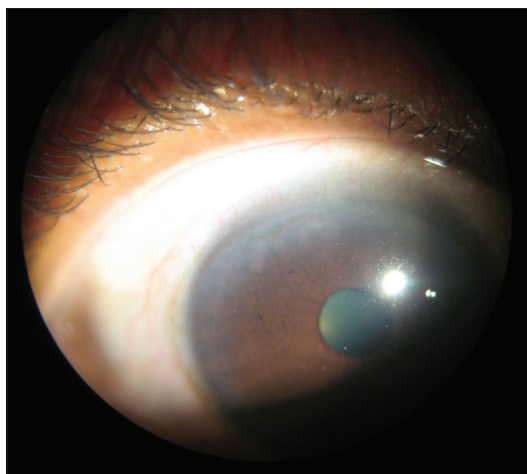


Figure 5: Corneal abscess absorbed completely after treatment (dated March 9, 2013)

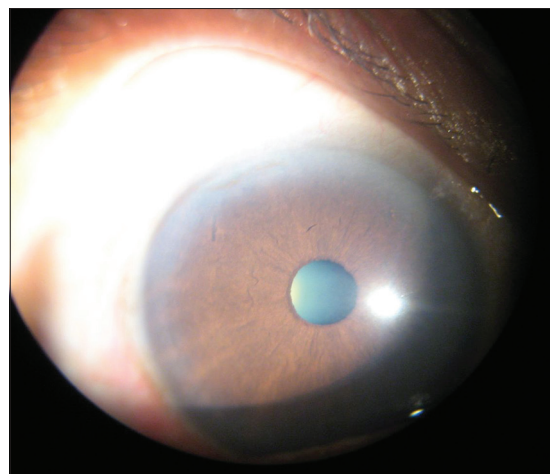


Figure 6: No recurrence of corneal abscess during follow-up (dated March 30, 2013)

abscesses of the cornea, especially for the deep-sloughing form.^{2[1]} *Hepar sulphuris* is usually prescribed when the

intensity of symptom is severe. In this case, corneal abscess was intrastromal, so symptoms were not as severe as they

occur with an infected corneal ulcer. *Hepar sulphuris* was mainly prescribed on the basis of pathology as an abscess and prescription was not based on any characteristic particular symptom. Hence, even though the patient had no severe pain, it was prescribed and resulted in complete resolution of abscess.

Hepar sulphuris was used in medium (200C) potency with frequent repetition and not in low potency because there was an acute inflammatory condition of the cornea with recent pathological changes that were reversible in nature. Second, patient had only ocular symptoms with no obvious general complaints that show a moderate vitality or susceptibility in a patient. Third, *Hepar sulphuris* has action on abscess in general and corneal abscess in particular. Hence, more the similarity of medicine to the affected part, more will be the susceptibility of a patient for medicine, and higher will be the potency required.^[7] Finally, the aim of treatment was to absorb the abscess internally and not to promote further suppuration so as to prevent opening of an abscess externally with an added risk of exogenous infection. Abscess was absorbed considerably within 5 days with no untoward effects that indicate correct selection of potency for this case.

A spontaneous or natural resolution of abscess is not a possibility in this case as majority of abscess has resolved within 5 days of treatment [Figure 3]. Norton AB has mentioned that “as a rule, corneal abscess does not heal by itself but more and more parenchyma is destroyed, and if in a rare case, it heals by itself it begins by formation of new blood vessels in the cornea.” In this patient, no new blood vessels were seen on cornea during healing stage of an abscess. Similarly, no reference in modern literature mentions a natural resolution of abscess. Patient had done no alteration in diet or regimen and no axillary line of treatment was suggested. Similarly, another case of corneal abscess in an old woman was treated successfully by me with *Hepar sulphuris* in the year 2014. All these points go in favor of resolution of an abscess by medicine.

In this case, abscess was intrastromal without actual ulceration of cornea and was located at its periphery, so there was no corneal scarring and vision was not affected during follow-up visits.

Absorption of corneal abscess was a top priority in this case as well as there were no obvious signs and symptoms of general disease, so a systemic homoeopathic treatment was started immediately without going for any investigation. However, in future cases, detailed investigations will be carried out to find out the root cause of corneal abscess.

The intention to present this case was that *Hepar sulphuris* even though has been mentioned in homoeopathic literature for corneal abscess, published case report about its effect was lacking. Ocular photographs taken during follow-up visits have provided valid evidence about its effectiveness in corneal abscess. Hence, physicians can use *Hepar sulphuris* 200C in their clinical practice to treat patients suffering from intrastromal corneal abscess.

CONCLUSION

A case report presented with ocular photographic evidence directs to positive role of effectiveness of homoeopathic medicine *Hepar sulphuris* 200C in corneal abscess. However, case series/clinical trials are required to substantiate the results of *Hepar sulphuris* in corneal abscess.

Financial Support and Sponsorship

Nil.

Conflicts of Interest

There are no conflicts of interest.

REFERENCES

1. Norton AB. Ophthalmic Diseases and Therapeutics. 3rd ed. New Delhi: B. Jain Publishers (P) Ltd.; 1987. p. 261-2, 627.
2. Sihota R, Tandon R. editors. Parsons' Diseases of the Eye. 20th ed. New Delhi: Elsevier; 1984. p. 186-97.
3. Missouri Department of Health and Senior Services. FAQ's. Available from: <http://www.health.mo.gov/safety/antibioticresistance/faq.php>. [Last accessed 2016 Jan 10]
4. Boericke W. Boericke's New Manual of Homoeopathic Materia Medica with Repertory. New Delhi: B. Jain Publishers (P) Ltd.; 2011. p. 636.
5. Moffat JL. Homoeopathic Therapeutics in Ophthalmology. New Delhi: B. Jain Publishers (P) Ltd.; 1995. p. 137.
6. Boger CM. Boenninghausen's Characteristic and Repertory. New Delhi: B. Jain Publishers (P) Ltd.; 1987. p. 310.
7. Close S. Genius of Homoeopathy. Reprint Edition. New Delhi: B. Jain Publishers (P) Ltd.; 1984. p. 183-211.

साक्ष्य आधारित होम्योपैथी: नेत्रपटल के पस भरे फोड़े का मामला

नेत्रपटल का फोड़ा कॉर्निया की परतों के बीच गोलाकार रूप में एक पस का भराव है। यह उत्पत्ति में प्रायः अंतर्जात होता है और कॉर्निया के किनारे के निकट लिम्बल रक्त वाहिकाओं के पास पाया जाता है। आधुनिक औषध विज्ञान में इसकी चिकित्सा स्थानीय और प्रणालीगत प्रतिजीवियों (एंटीबायोटिक्स) के प्रयोग द्वारा है। होम्योपैथी में कॉर्निया के फोड़ों के लिए औषधियाँ वर्णित हैं। 68 वर्षीय एक महिला का मामला दर्ज किया गया जो दाहिनी आँख में लाली, हलके दर्द और बाह्य पदार्थ के अनुभव से पीड़ित थी और कॉर्निया के फोड़े के रूप में रोग की पहचान की गयी। रोग-निदान के आधार पर होम्योपैथी औषधि हेपार सल्फ्यूरिस 200सी लेने की सलाह दी गयी। पांच दिनों के अंदर फोड़े के आकार में अत्यंत कमी आई और वह 21 दिनों में पूरी तरह से सूख गया। उसके पश्चात फोड़े की पुनरावृत्ति देखने को नहीं मिली। अनुवर्ती जाँच के दौरान ली गयी नेत्र तस्वीरों ने कॉर्निया के फोड़े की स्थिति में होम्योपैथी की हीपर सल्फ्यूरिस 200सी की प्रभावशीलता के बारे में प्रलेखी साक्ष्य प्रदान कराया है।

Homeopatía basada en evidencias: caso de absceso córneo

RESUMEN

El absceso córneo es una acumulación circunscrita de pus dentro de las capas de la córnea. Suele ser de origen endógeno y encontrarse habitualmente cerca de los vasos sanguíneos de limbo cerca del margen corneal. El tratamiento en medicina moderna reside en la administración de antibióticos locales y sistémicos. En homeopatía, se han indicado medicamentos para los abscesos córneos. El caso referido es una mujer de 68 años de edad con síntomas de enrojecimiento, dolor sordo y sensación de cuerpo extraño en el ojo derecho. Se le había diagnosticado un absceso córneo. Se le prescribió el medicamento homeopático *Hepar sulphuris* 200C teniendo en cuenta su patología. El absceso se redujo considerablemente en cinco días y al cabo de 21 días estaba totalmente absorbido. No se observó recurrencia del absceso posteriormente. Las fotografías oculares durante las visitas de seguimiento ofrecen evidencias documentadas de la eficacia del medicamento homeopático *Hepar sulphuris* 200 C en el absceso córneo.